

ORIGINAL COMMUNICATION

ANATOMY OF THE MALE REPRODUCTIVE ORGANS OF THE AFRICAN SIDENECK TURTLE (*Pelusios castaneus*).

Olukole Samuel Gbadebo^{1*}, Oyeyemi Matthew Olugbenga², Oke Bankole Olusiji¹.

¹Department of Veterinary Anatomy, Faculty of Veterinary Medicine, University of Ibadan, Ibadan, Nigeria.

² Department of Veterinary Surgery and Reproduction, Faculty of Veterinary Medicine, University of Ibadan, Ibadan, Nigeria.

*Corresponding Author: Dr S.G. Olukole, Reproductive Biology and Vertebrate Morphology Unit, Department of Veterinary Anatomy, Faculty of Veterinary Medicine, University of Ibadan, Ibadan, Nigeria. E-mails: deborolukole@yahoo.com

SUMMARY

The topographic anatomy of the male reproductive organs of the African sideneck (*Pelusios castaneus*) turtle was explored through dissection. The testis and epididymis were attached to the peritoneal wall in all the turtles examined, posterior to the lungs, ventrolateral to the kidneys. The testes were yellow, smooth and ovoid in shape while the epididymes were sigmoid in shape and creamy in colour. The ureter, ductus deferens and urinary bladder led into the cloaca, which opened to the exterior at the tip of the tail. The penis was completely housed within the ventral floor of the cloaca and consists of two corpora cavernosa in between which was the urethral groove. The male reproductive anatomy of the African sideneck turtle is similar to those earlier reported in sea and freshwater turtles.

Key Words: Testis, Epididymis, Morphology, Turtles.

INTRODUCTION

Freshwater turtles are under increasing threats around the world. The African side neck turtle (*Pelusios castaneus*) is a freshwater turtle of the family Pelomedusidae, widely distributed in West Africa (Kirkpatrick, 1995). This turtle is small to medium in size, with relatively extensive plastron that may have a hinge present between the pectoral and abdominal scutes (Olukole *et al.*, 2010).

Limited research studies have been reported on the Africa genus *Pelusios*. The existing reports focused on its conservation, nutrition and history of migration (Broadley and Boycott, 2009). With the exception of

the reports by Olukole *et al.* (2010), on the morphometry of the external body anatomy and the blood parameters of the African sideneck turtle (Omonona *et al.*, 2011), there is paucity of research information on the basic anatomy of the animal.

This report brings to lime light the topographical anatomy of the male reproductive organs of the African sideneck turtle through dissection of the animal with the view of understanding the anatomical relations of these organs with other organs within the abdominal and pelvic regions of the animal.

MATERIALS AND METHODS

Experimental Animals

Ten adult male African sideneck turtles from

various riverbanks in Ibadan, Nigeria, were used for the study. The animals were kept

in artificial ponds, fed with commercial fish pellets *ad libitum* and standard body parameters were determined using a Draper® 115 mm vernier caliper and metric tape, while body weight were taken with the aid of a Microvar® weighing balance. The Ethics Committee of the Faculty of Veterinary Medicine, University of Ibadan, Nigeria, approved the protocol for the study and there was no conflict of interest.

Turtle Dissection

The animals were sacrificed by cervical decapitation. In order to separate the plastron from the carapace, a straight line

cut through the inframarginal scutes of each animal was made craniocaudally.

This was followed by the detachment of the thick connective tissue between the pectoral apparatus from the anterior part of the plastron and cutting through the pelvic bones, which were attached to the coelomic surface of the plastron. The carapace was then separated from the plastron as described by Wyneken, 2001. The superficial and deep structures of the coelomic cavities of the turtles were exposed. The structural relations of the enclosed organs were studied in situ and were recorded through the use of a Samsung® digital camera.

RESULTS

The average body weight of the turtles was 0.75 ± 0.03 kg. The curved carapace and plastron lengths of the turtles were 23.4 ± 1.27 cm and 16.3 ± 1.42 cm, respectively. On the superficial surface of the coelomic cavity were the large fan-shaped pelvic muscles that were attached to the plastron (pelvic muscles and fat deposits) [Figure 1]. The left and right acromion processes crossed the anterior surface of the coelomic cavity just posterior to the neck and extended to the shoulder joint. They were attached medially to the plastron via ligaments. The coracoid processes extended posteriorly from the shoulder joint toward the abdomen. The heart, lungs, liver, segments of the small intestine and major blood vessels were located after separating the muscles from the peritoneum by anterior rotation of the coracoid and acromion processes (Figure 2). The testis and epididymis were attached to the peritoneal wall in all the turtles examined. These gonads were posterior to the lungs and located on the medial sides of the kidneys on both sides of the median plane

(Figures 3 and 4). Topographically, the testis was observed to be 2-3 cm equidistant from both the median plane of the turtles and the bridge between the carapace and plastron. Hence, the caudal border of the seventh marginal scute of the carapace coincides with the cranial border of the testis on both sides of the median plane of the turtle.

On the plastron, this landmark corresponds with the cranial portions of the femoral scute. Also, the long axis of the testis was nearly longitudinal and had two surfaces (ventral and dorsal), two borders (lateral and medial), and two extremities (anterior and posterior). The medial and lateral borders are convex in shape with the lateral border relating laterally to the kidneys. The epididymis of the *P. castaneus* attached to the lateral aspects of the caudal border of the testis and extended caudally to about 2-3 cm before transiting into the ductus deferens. The width of the epididymis ranged from 1.5 to 2 cm. Topographically, the epididymis was found between the 8th

and 9th marginal scutes at the midpoint of the femoral scute of the plastron.

The entire length of the each kidney was lateral to its corresponding epididymis on both sides of the median plane and extends to a point less than 0.5 cm to the caudal end of the epididymis (Figure 4). The cranial portion of the epididymis attaches to the entire length of lateral border of the testis by efferent ducts of the testis, connective tissue and serous membrane. The epididymis by virtue of its nature of attachment could not be subdivided into head, body and tail as in mammals.

The ductus deferens, a tiny-coiled tube is a continuation of the epididymis extending to the neck of the urinary bladder in the region covered by the anal scute of the plastron (Figures 3 and 4). A pair of accessory urinary bladder was found caudolateral to the neck of the main urinary bladder and dorsal in position to the pubis (Figures 4 and 5). The ureter ran caudally on the medial portions of the kidneys, just between the kidneys and epididymis. The ureter, ductus deferens and urinary bladder as well as its accessories all lead into the cloaca which then opened to the exterior at the tip of the tail (Figure 5). The penis was completely housed within the ventral floor of the cloaca (Figures 5 and 6). The penis of the *P. castaneus* consists of two corpora cavernosa and a urethral groove that leads to the exterior. The glans penis was observed at the posterior end of the urethral groove (Figure 6).

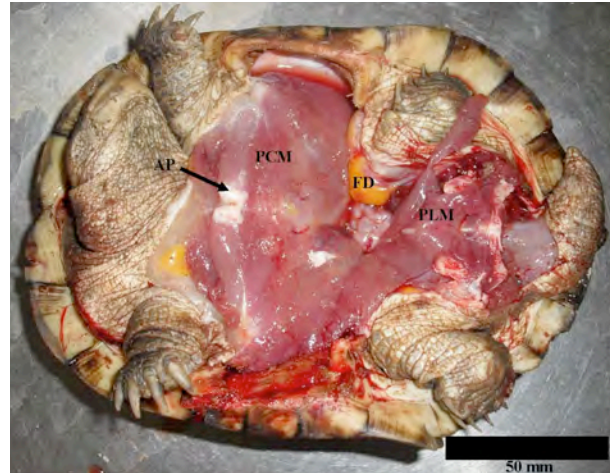


Figure 1. Superficial structures of the coelomic cavity of the *P. castaneus*. PCM: Pectoralis muscle; FD: Fat Deposit; PLM: Pelvic Muscle; AP: Acromion Process

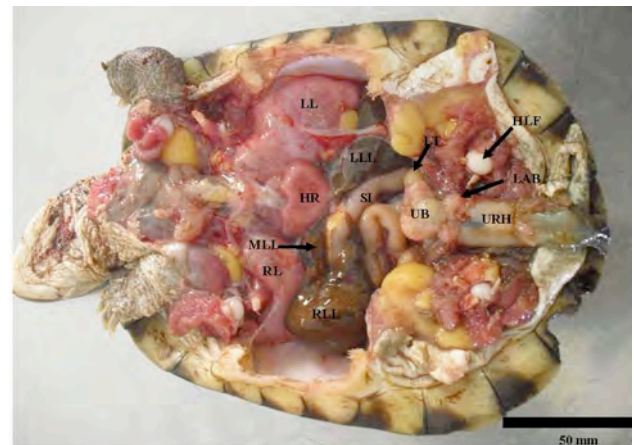


Figure 2. Deep structures of the coelomic cavity of the *P. castaneus*. HR: Heart; LL: Left lung; LLL: Left lobe of Liver; RLL: Right lobe of Liver; MLL: Middle Lobe of Liver; SI: Small Intestine; LT: Left Testis; HLF: Head of left femur; URH: Urethra; UB: Urinary Bladder; LAB: Right Accessory Urinary Bladder.

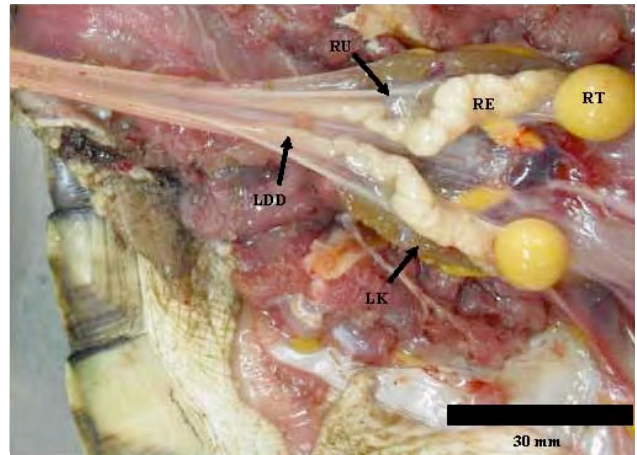


Figure 4: The topographical relations of the male reproductive organs of the *P. castaneus*. LK: Left Kidney; RU: Right Ureter; LDD: Left Ductus Deferens; RE: Right Epididymis; RT: Right Testis.

Figure 3: The urinogenital system of the *P. castaneus*. RT: Right testis; RE: Right Epididymis; RAB: Right Accessory Urinary Bladder; UB: Urinary Bladder. Note that the Urinary bladder is reflected in this diagram to show its link to the accessory urinary bladders.

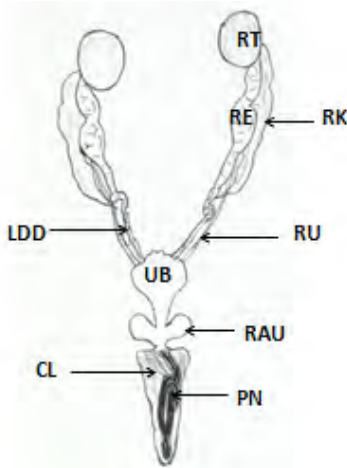


Figure 5: Diagrammatic presentation of the male reproductive organs of the *P. castaneus*. RK: Right Kidney; RU: Right Ureter; LDD: Left Ductus Deferens; RE: Right Epididymis; RT: Right Testis; UB: Urinary Bladder; RAU: Right accessory Urinary Bladder; CL: Cloaca; PN: Penis.

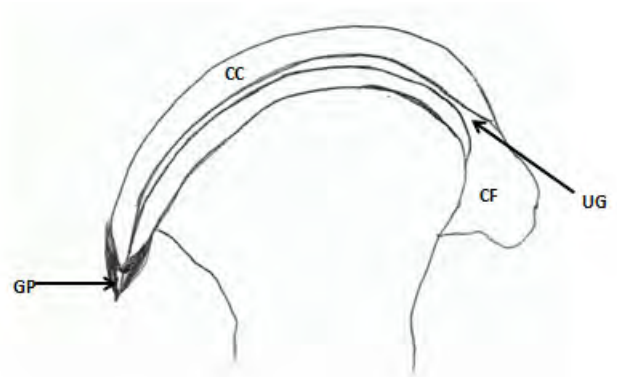


Figure 6: Diagrammatic presentation of the penis of the *P. castaneus*. CC: Corpus carvenosus; GP: Glans penis; CF: Cloacal floor; UP: Urethral groove.

DISCUSSION

The study of the topographic anatomy of reptiles is a necessary tool in the understanding of the structure and function

of turtles, crocodiles, lizards, sphenodons and birds. The identification of specific landmarks on the carapace and plastron for

the location of the gonads in the African sideneck turtle provides a useful a guide for veterinarians in post mortem examination of the gonads of sea and freshwater turtles.

The testis was yellow, smooth and ovoid in shape with the epididymis being relatively sigmoid and creamy in colour. These are in conformity with earlier reports on the male reproductive organs of freshwater turtles (Kellner and Schwanke, 2001). These findings are similar to the report of Rao and Shaad (1985) on the male reproductive organs of the freshwater turtle *Trionyx gangeticus*. The possession of accessory urinary bladder as observed in the study had been reported in several species of sea and freshwater turtles (Wyneken, 2001). The structure of the penis and its anatomical relations observed in the *P. castaneus* is in conformity with previous reports on the organs of the male reproductive organs of turtles (Wyneken, 2001). The relations of the kidneys to the gonads in the *P. castaneus* are similar to that described in the turtle of the *Trachemys scripta elegans* species (Silva *et al.*, 2010).

However, turtles of the *Trachemys scripta elegans* species have been reported to possess a pair of asymmetrical kidneys, located in the caudodorsal portion of the coelomic cavity (Silva *et al.*, 2010).

This study has shown that the topographical anatomy of the male reproductive organs of the *P. castaneus* is similar to those of earlier reports in both sea and freshwater turtles. The information made available by this study is expected to be useful in reptilian clinical practice as well as the improved breeding of the animal. The outcome of the study is also expected to be useful in the comparative regional anatomy of sea and freshwater turtles.

Acknowledgement: This work was supported by University of Ibadan Senate Research Grants (SRG/FVM/2010/4A and SRG/FVM/2010/1B). The authors would like to appreciate the support of the members of staff of the Technical Unit of the Department of Veterinary Anatomy, especially, Mr Shina Ramoni, the Chief Technologist.

REFERENCES

1. Broadley DG, Boycott RC. 2009. *Pelusios sinuatus* (Smith 1838) –Serrated Hinged Terrapin. Conservation Biology of Freshwater Turtles and Tortoises. Chel Res Monographs 5: 036.1-036.5.
2. Kellner A, Schwanke C. 2001. Reptile fossils of Brazil: a brief introduction to herpetology. In: Brito IM. (Ed.). Geologia historica. Uberlandia: Edufu. p 303-363.
3. Kirkpatrick DT. 2013. An Essay on Taxonomy and the Genus *Pelusios*. Available at: <http://www.unc.edu/~dtkirkpa/stuff/pel.html> Accessed: 22 February 2013. Originally published in Reptile & Amphibian Magazine, March/April 1995. p 32-40.
4. Olukole SG, Aina OO, Okusanya BO. 2010. Morphometric analysis of the external body anatomy of the African sideneck turtle (*Pelusios sinuatus*). Conference proceedings of the 30th Annual Symposium on Sea Turtle biology and conservation held in Goa, India, p. 313.
5. Omonona AO, Olukole SG, Kushe FA. 2011. Haematology and serum biochemical parameters in free ranging African sideneck turtle (*Pelusios sinuatus*) in Ibadan, Nigeria. *Acta Herpetol.*, 6: 267-274.

6. Rao RJ, Shaad FU. 1985. Sexual cycle of the male freshwater turtle, *Trionyx gangeticus* (Cuvier) *Herpetol*, 41: 433-437.
7. Silva GFN, Matos WCG, Freire VTO, Pereira NJ, Seyfert CE, Faria MD. 2010. Dimensions, mass and volume of the turtles kidneys (*Trachemys scripta elegans* WIED, 1839). *J. Morphol. Sci.*, 27: 142-147.
8. Wyneken J. 2001. The Anatomy of Sea Turtles. U.S. Department of Commerce NOAA Technical Memorandum NMFS-SEFSC-470, p. 1-172.