

Variant Branching of the Common Femoral Artery in a Black Kenyan Population: Trifurcation is Common

Julius Ogeng'o, Musa Misiani, Bethleen Waisiko, Beda O. Olabu, Emily Maranga

Correspondence to Prof. Julius Ogeng'o, Department of Human Anatomy, University of Nairobi P.O. BOX 30197 – 00100 Nairobi, Kenya. Email: jogengo@uonbi.ac.ke.

ABSTRACT

Branching pattern of common femoral artery is important during artery catheterization, orthopaedic, plastic and general surgery in the proximal thigh. Frequency of variant branching shows ethnic variation but there are no data for black African populations. Since atherosclerotic diseases are increasing and femoral artery catheterization is rising, variation in branching of common femoral artery was studied by dissection in a black Kenyan population. 208 femoral arteries in 104 limbs were studied. Bifurcation occurred in only 72.1% of cases. Trifurcation into superficial femoral, profunda femoris and lateral circumflex femoral arteries occurred in 27.9% of cases. Trifurcation of common femoral artery is a common variation in the black Kenyan population. Pre – operative ultrasonic evaluation of the femoral arterial system is recommended to minimize inadvertent arterial injury during catheterization or surgery.

INTRODUCTION

Common femoral artery (CFA) is the segment of the artery proximal to the origin of profunda femoris artery (PFA) at the so-called femoral bifurcation, while the segment distal to the bifurcation is called superficial femoral artery (SFA) [Standing et al., 2008; Crisan, 2012]. Variations in branching pattern of common femoral artery are important during arterial catheterization for diagnostic and therapeutic radiology, femoral embolectomy and proximal thigh surgery (Thitilerdecha et al., 2012). Such variations may also explain variations in occurrence of atheroma (Moore et al., 2012) and influence interpretation of the effects of lower limb vaso occlusive disease (Norgen et al., 2007). The branching patterns display ethnic variation but data from black African

populations are scarce. We recently described variant origin of the lateral circumflex femoral artery (Sinkeet et al., 2012), but did not elucidate variational branching of common femoral artery. Atherosclerosis of the common femoral artery frequently occurs in association with disease in the aortoiliac and femoral popliteal territories (Norgen et al., 2007; Kang et al., 2008; Nelson et al., 2012). Further, atherosclerosis is becoming more common in black African populations (Mensah, 2008). Accordingly, data on the femoral artery, which is one of the most frequently cannulated and involved artery is critical. This study therefore aimed at describing the variations in branching pattern of the common femoral artery in a black Kenyan population.

MATERIALS AND METHODS

This was a cadaveric dissection study. Two hundred and eight femoral arteries from 104 lower limbs of black Kenyans were examined at the Department of Human Anatomy, University of Nairobi, Kenya. The femoral triangle was exposed on both sides by three incisions along the inguinal ligament, from the anterior superior iliac spine to the knee and from the pubic symphysis to the knee.

Skin flap and fascia were removed, fibrofatty tissue and veins cleared, to expose sartorius and adductor longus muscles. The muscles were retracted and femoral sheath opened to expose the entire length of the femoral artery lateral to the femoral vein (Figure 1). Common femoral artery (CFA) was defined as that segment between the inguinal ligament and origin of Profunda femoris

artery (PFA), while the continuation beyond here was referred to as the superficial femoral artery (SFA). The junction between CFA and PFA was considered the femoral bifurcation. Medial circumflex femoral artery (MCFA) was identified as the largest branch of either CFA, PFA or SFA that wound around the medial side of the femur between

pectineus and iliopsoas then between obturator externus and adductor brevis. Lateral femoral circumflex artery (LCFA) was taken as the largest branch that coursed laterally on the lateral side of the femur between the anterior and posterior divisions of the femoral nerve.

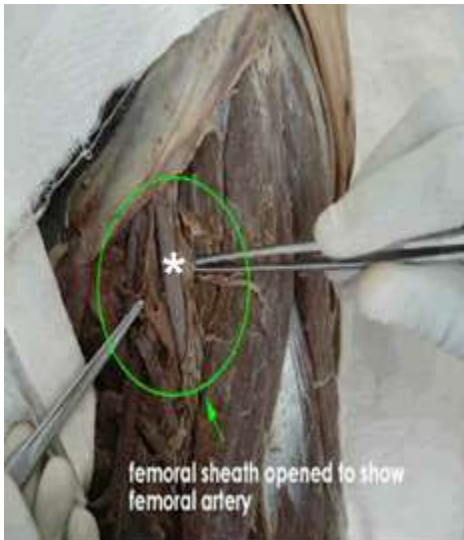


Figure 1A: Dissection of femoral triangle to display the common femoral artery (*) in the oval

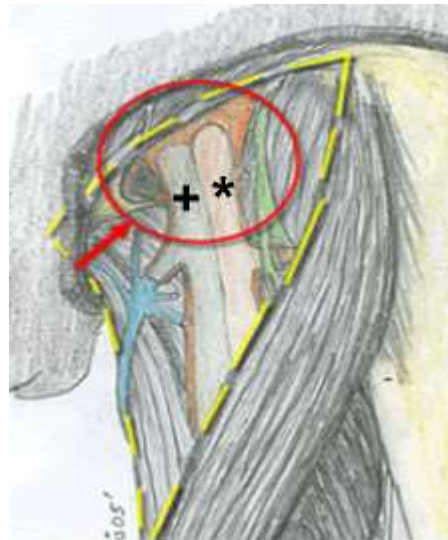


Figure 1B: Drawing of femoral triangle to show proximal femoral artery (*) and femoral vein (+) in the circle

Two hundred and eight CFAs from 104 individuals (68 male and 36 female) were available for examination. Two patterns of branching of the CFA were identified. Bifurcation (Fig 1A) into PFA and SFA was the most common pattern (72.1%). Trifurcation (Fig 1B) into SFA, PFA and LCFA was observed in 58 (27.9%) cases. In all cases, MCFA arose either from a common short trunk with PFA (Fig 1C) (20.4%) or from the PFA (79.6%). LCFA arose from PFA

in 138 (66.7%), CFA in 58 (27.9%) and from SFA in 12 (5.6%) cases (Fig 1D).

Also noteworthy in these cases of bifurcation was the level of origin of the MCFA and LCFA. These vessels originated at the same level in only 62 (29.6%) instances. In the remainder (70.4%), LCFA arose from PFA distal to MCFA. Gender and side differences were not statistically significant.

RESULTS




Figure 1 A - D: Branching pattern of the common femoral artery in an adult black Kenyan population. A: Bifurcation (*) of the common femoral artery (CFA) into the superficial femoral artery (SFA) and profunda femoris artery (PFA). Note the origin, at the same level, of the medial and lateral circumflex femoral arteries (M) and (LCFA) respectively from profunda femoris artery. **B:** Trifurcation (*) of the common femoral artery (CFA) into the superficial femoral artery (SFA), profunda femoris artery (PFA) and lateral circumflex femoral artery (LCFA). Note the origin of medial circumflex femoral artery (MCFAs) from profunda femoris artery. **C:** Trifurcation (*) of the common femoral artery (CFA) into the superficial femoral artery (SFA) profunda femoris artery (PFA) lateral circumflex femoral artery (LCFA) and common trunk for medial circumflex femoral (MCFAs) and profunda femoris (PFA) arteries. **D:** Bifurcation (*) of the common femoral artery (CFA) into superficial femoral (SFA) and common stem for PFA and MCFAs. Note the origin of lateral circumflex femoral artery (LCFA) from superficial femoral artery (SFA).

DISCUSSION

The femoral artery usually bifurcates into the superficial femoral and profunda femoris arteries (Standing, 2008; Crisan, 2012). Observations of the current study revealed, however, that bifurcation occurred in only 72.1% of cases. In the remainder (27.9%), the artery trifurcated into SFA, PFA and LCFA. There are only isolated reports of such variation (Guidicelli et al., 1977; Troupis et al., 2013; Savirithri, 2013). The variation results from origin of LCFA from the common femoral artery, which occurs in up to 33% of cases (Basar et al., 2002). A remarkable finding of the current study is the high frequency of origin of circumflex femoral arteries from the superficial femoral arteries. This is hardly reported in literature. It is probable that this is due to a nomenclature difference for various segments. Knowledge of these variations is, however, important to minimize inadvertent damage to the arteries during orthopaedic, plastic, vascular, general surgical and invasive cardiology procedures (Troupis, 2012).

The presence of trifurcation significantly alters flow patterns, which may predispose to

atherosclerosis. Accordingly, the high frequency of trifurcation suggests that this population is more vulnerable to atherosclerosis. Cases where MCFA, LCFA or both arise from CFA may, in the same way, be more vulnerable to atherosclerosis. 27.9% frequency is higher than most of those reported in other populations (Table 1). This may constitute part of the explanation for more frequent involvement of CFA and SFA in atherosclerosis.

These figures reflect wide variations in origin of circumflex arteries. Origin of the latter directly from the femoral artery may be due to varied levels of separation of profunda femoris from the femoral artery during development. These variations should always be considered during diagnostic, interventional radiological and surgical procedures in the femoral triangle (Prakash et al., 2010). In conclusion, trifurcation of common femoral artery is a common variation in the black Kenyan population. Pre – operative ultrasound evaluation of the femoral arterial system is recommended to minimize inadvertent arterial injury during catheterization or surgery.

Table 1: Origin of the circumflex femoral arteries in various populations

Reference	Population	Frequency of origin of circumflex femoral arteries (%)					
		MCFA			LCFA		
		CFA	PFA	SFA	CFA	PFA	SFA
Siddharth <i>et al.</i> , 1985	Indian	26	63	-	16	71	-
Uzel <i>et al.</i> , 2008	Turkish	-	-	-	19.1	77.3	-
Adachi, 1928	German	14	63.2	-	18.3	78.2	-
Lippert and Pabst, 1985	German	-	58	-	19	76	-
Massoud and Fletcher, 1997	American	18	81	-	2.8	81	-
Basar <i>et al.</i> , 2002	Turkish	-	-	-	32.9	67.1	-
Fukuda <i>et al.</i> , 2005	Japanese	-	-	-	16.6	78.6	-
Dixit <i>et al.</i> , 2011	Indian	19.3	66.7	-	7.9	77.2	-
Tanyeli <i>et al.</i> , 2006	Turkish	15	79	-	-	-	-
Perera, 1995 [683]	Colombian	35.4	64.5	-	14.6	85.4	-
Samarawickrama <i>et al.</i> , 2009	Greek	31	62	-	-	92.3	-
Emura, 1989	Japanese	-	61.7	-	-	-	-
Current study, 2013	Kenyan	-	79.6	4.1	27.9	66.7	5.6

MCFA= Medial Circumflex Femoral Artery; LCFA = Lateral Circumflex Femoral artery.

Acknowledgement: We are grateful to Jacob Gimongo and Acleus Murunga for technical support and Antonina Odock – Opiko for typing the manuscript.

REFERENCES

1. Adachi B, Hasebe K. 1928. Der Arterien system der Japaner vol 1. Kyoto, maruzen, Kaiserhck japanaischen: Universtiat Zu Kyoto: 43 – 46.
2. Basar R, Sargon MF, Cumhur M, Bayramoglu A, Demiryurek D. 2002. Distinct intergender difference in the femoral artery ramification pattern found in the Turkish population: angiographic study. *Anat Sci Int*, 77: 250 – 253.
3. Crisan S. 2012. Ultrasound examination of the femoral and popliteal arteries. *Medical Ultrasound*, 14:74-77.
4. Dixit DP, Mehta LA, Kothari ML. 2001. Variations in the origin and course of profunda femoris. *J Anat*, 50: 6 – 7.
5. Emura S, Shoumura S, Ishizaki N, Tamahira T, Ito M, Chen SY, Isono H. 1989. The anatomical study of the branches of the femoral artery (II). Comparison with the findings of Adachi's classification. *Kaibogaki Zasshi*, 64: 196 – 205.
6. Fukuda H, Ashida M, Ishii R, Abe S, Ibukuro K. 2005. Anatomical variants of the lateral circumflex femoral artery: an angiographic study. *Surg Radiol Anat*, 27: 260 – 264.
7. Guidicelli H, Meaulle PY, Lecoecur J, Dupre A, Bonneton G, Gauthier R. 1977. Repair problems of infected iatrogenic lesions of the femoral trifurcation. Review of 7 cases. *Acta Chir Bel*, 76:317-322.
8. Kang JL, Patel VI, Conrad MF, Lamuraglia GM, Chung TK, Cambria RP. 2008. Common femoral artery occlusive disease: contemporary results following surgical endarterectomy. *J Vasc Surg* 18: 872 – 877.
9. Lipert H, Pabst R. 1985. The arterial variations in man. Their classification and frequencies. *Bergmann Munchen*, 54 – 61.
10. Masoud TF, Fletcher EW. 1997. Anatomical variations of the profunda femoris artery: an angiographic study. *Surg Radiol Anat*; 19: 99 – 103
11. Mensah GA. 2008. Ischemic heart disease in Africa. *Heart* 94: 836 – 843.
12. Moore JE, Timmins LH, La Disa JF. 2010. Coronary artery bifurcation biomechanics and implications for interventional strategies. *Cath Cardiovasc Interv*, 76:836-843.

13. Nelson PR, Powell RJ, Schemerhorn ML, Fillinger MF, Zwolak RM, Walsh DB. 2012. Early results of external iliac stenting combined with common femoral endarterectomy. *J Vasc Surg* 35: 1107 – 1113.
14. Norgen L, Hiatt WR, Dormandy JA, Nehler MR, Harris KA, Fowkes FG. 2007. Intersociety consensus for the management of peripheral arterial disease (TASC II). *J Vasc Surg (suppl)*; s5 – 67.
15. Perera J. 1995. Anatomy of the origin of the deep femoral artery. *Ceylon Med J*, 40: 139 – 141.
16. Prakash KJ, Kumar BA, Jose BA, Kumar YS, Singh G. 2010. Variations in the origins of the profunda femoris and the medial and the lateral circumflex femoral arteries. A cadaver study in Indian population. *Rom J Morphol Embryol*, 51: 167 – 170.
17. Samarawickrainna MB, Nanayakhara BG, Wimalagunaratana KWR, Nishantha DG, Walawage UB. 2009. The branching pattern of the femoral artery in the femoral triangle: a cadaver study. *Galle Med Journal*, 14: 31 – 34.
18. Savithri P. 2013. A rare variation of trifurcation of right femoral artery. *Int J Anat variations*, 6: 4 – 6.
19. Siddarth P, Smith NL, mason RA, Giron F. 1985. Variational anatomy of the deep femoral artery. *Anat Rec*, 212: 206 – 209.
20. Sinkeet SR, Ogeng'o JA, Elbusaidy H, Olabu BO, Irungu MW. 2012. Variant origin of lateral circumflex femoral artery in a black Kenyan population. *Folia Morphol (warz)*, 71 (1): 15 – 18.
21. Standring S. 2008. *Grays Anatomy-The anatomical basis of clinical practice*. 40th edition. Spain: Churchill Livingstone Elsevier,1380.
22. Tanyeli E, Uzel M, Yildirim M, Celik HH. 2006. An anatomical study of the origins of the medial circumflex femoral artery in the Turkish populations. *Folia Morphol*, 65: 209 – 212.
23. Thitilerdecha SDM, Rungruang T, Voraphattropas C. 2012. The origin of profunda femoris artery in Thais. *Siriraj Med J*, 64: 534 – 536.
24. Troupis T, Michalinos A, Marcos L, Samolis A, Tsakotos G, Dimittoulis D, Vemeratos D, Skandalakis P. 2013. "Trifurcation" of femoral artery. *Artery Res*, 7: 106 – 108.
25. Uzel M, Tanyeli E, Yildirim M. 2008. An anatomical study of the origin of the lateral circumflex femoral artery in the Turkish population. *Folia Morphol*; 67: 226 – 230.