

RELATION OF THE EXTERNAL LARYNGEAL NERVE TO SUPERIOR THYROID ARTERY IN AN AFRICAN POPULATION

Georgina Magoma, Hassan Saidi, Wyckliffe Kaisha

Correspondence: Georgina Magoma email: georginamagoma@gmail.com, Department of Human Anatomy, University of Nairobi, P.O. Box 00100 – 30197, Nairobi, Kenya.

SUMMARY

The external laryngeal nerve runs parallel to superior thyroid artery and later crossing the artery either above or below the upper pole of the thyroid gland. This relatively high anatomic variability demonstrates inter-population differences. However, datum among the Kenyan population is lacking. Knowledge of normal and variant anatomy of these structures is important in surgical procedures within the neck. This study therefore aimed at describing the variant anatomical relations of the superior thyroid artery and external laryngeal nerve for the Kenyan population. Twenty formalin fixed cadavers obtained from the Department of Human Anatomy, University of Nairobi were dissected to expose the thyroid gland, superior thyroid artery and external laryngeal nerve. The relation of the superior thyroid artery to the external laryngeal nerve was noted. The external laryngeal nerve crossed the superior thyroid artery within 1cm above the upper pole of the thyroid gland in 25% of cases and more than 1 cm in 75% of cases. The level at which the external laryngeal nerve crosses the superior thyroid artery displays variations among Kenyans warranting care during surgical procedures of the thyroid gland.

Key words: Superior thyroid artery, Nerve

INTRODUCTION

Surgical procedures involving the thyroid gland require a thorough knowledge not only of the normal gross anatomy of the structures within the region but also of the anatomical variations of the structures located within it (Vazquez et al., 2008). With most studies focusing on the anatomic variation of the inferior thyroid artery and the recurrent laryngeal nerve, few have demonstrated variations of the superior thyroid artery (STA) and the external laryngeal nerve (ELN) (Cernea et al., 1992). The STA branches from the external carotid artery and descends to reach the superior pole of the thyroid gland (Thwine et al., 2010). The artery courses anterolateral to the external branch of the superior laryngeal nerve until just above the superior pole of the thyroid gland (Aina and Hisham, 2001).

The ELN is closely related to the STA as it crosses the artery from lateral to medial, either above or below the superior pole of the thyroid (Cernea et al., 1995). Variations in the ELN in relation to the STA and the upper pole of thyroid gland are important to note as it supplies the tensor of the

vocal cord. Iatrogenic injury to this nerve results in voice changes ranging from slight huskiness (Aina and Hisham, 2001) to a low volume and a tired voice.

This study therefore aimed at describing anatomical variations in the relationship of the STA and ELN.

MATERIALS AND METHODS

Twenty formalin fixed cadavers obtained from the Department of Human Anatomy, University of Nairobi were used in the study. Cadavers that were difficult to dissect and those that were macerated by the students before data collection were excluded from the study.

Skin incisions were made from the chin to the supra-sternal notch, along the lower border of the mandible up to the mastoid process and from the sternal end of the clavicle to the acromion process. Skin flaps were reflected for exposure of the anterior triangle of the neck. The platysma and the sternocleidomastoid were cut close to their origins on the clavicle and reflected superiorly. The strap

muscles were transected and reflected to expose the thyroid gland lying within its fascia. The dissection field was cleaned to expose the gland, STA, and ELN. The relationship between the STA and the ELN was noted and classified as being types 1, 2a and 2b (Cernea et al., 1992)

Type 1 - Nerve crossing the superior thyroid vessels 1 or more cm above a horizontal plane through the upper border of the superior thyroid pole.

Type 2a - Nerve crossing the vessels less than 1 cm above the horizontal plane.

Type 2b - Nerve crossing the vessels below the horizontal plane.

Macrographs of thyroid vessels that exhibited variations in origin were taken using a digital Kodak

Easy Share V103® camera. Data obtained was coded, tabulated and analysed using SPSS 16.0 for windows® (SPSS Inc., Chicago, Illinois). Percentages and frequencies of the observed variations in origin were obtained. Results were presented in tables and macrographs.

RESULTS

Forty ELN (20 right and 20 left) were dissected and their relationship with the superior thyroid artery noted. 10 of these nerves (25 %) crossed the STA within 1 cm above the upper thyroid pole (type 2a) while the remaining 30 ELN (75%) crossed the artery more than 1cm above the upper thyroid pole (type 1) [Fig. 1 and 2]. In all cases, there was bilateral symmetry

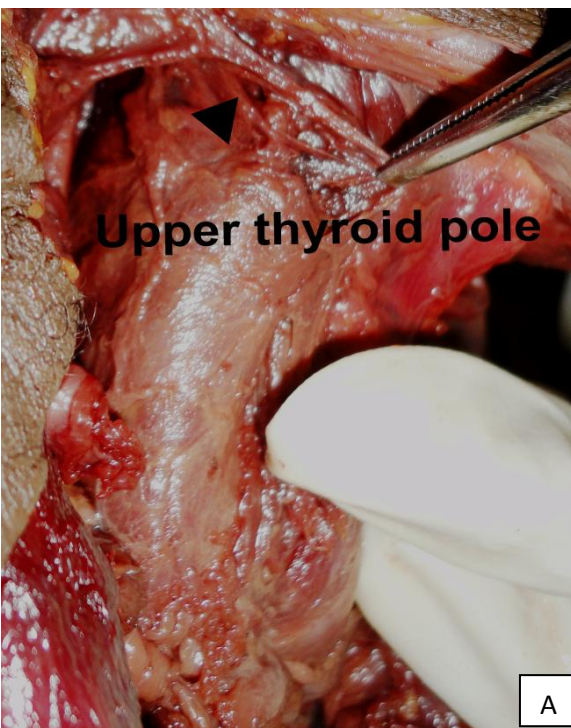


Fig. 1A: Type 1 ELN. Black arrow head at the superior thyroid artery, forceps tagging the ELN

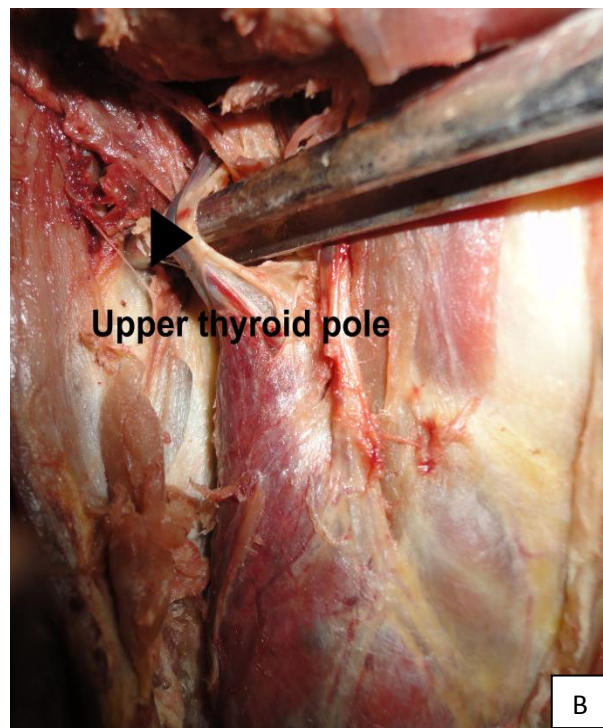


Fig. 1B: Type 2a ELN; Black arrow head at crossing of ELN on STA.

Table 1 Relationship of Superior thyroid artery and External laryngeal nerve

Author	Type 1	Type 2a	Type 2b
Cernea et al., 1992	60%	17%	20%
Aina and Hisham, 2001	17.3%	56%	26.7%
Current Study, 2010	75%	25%	Nil

DISCUSSION

There was a predominance of type 1 ELN (75%) which is higher compared to findings from other populations (table 1). The type 2 ELN (shown to constitute a quarter of the sample) is considered to be at high risk during ligation of the STA (Kark et al., 1984). Prevalence of this type of ELN is lower than that reported by Aina and Hisham, (2001). This difference may be due to characteristics of the samples whereby the latter study used patients with large goiters that required resection during surgery. This may be attributable to the enlargement of the gland displacing the pedicle higher. Indeed Cernea et al., (1995) showed a higher prevalence of type 2 b ELN in patients with large goiters. Bilateral symmetry was observed in all cases compared to asymmetry of upto 53% of cases observed by Cernea et al., (1992). In the aforementioned study, samples were drawn from 2 different anthropological groups, a factor that might contribute to the different results observed in this current study. The assumption was backed up

by observations in an article by Aina and Hisham, (2001) who postulated that there might be a higher frequency of high risk anatomic configuration of type 2b ELN in white people. In as much as it would appear that variations in the type of ELN within this population are less predisposed to iatrogenic injury, there is need for further intensive studies to be done on a larger sample in order to draw valid conclusions. Further studies on pathologic thyroid glands (goitres) should be done as this has been shown to affect the position of the external laryngeal nerve.

In conclusion, the Kenyan population shows a majority of the sample bearing the type 1 ELN with bilateral symmetry in all cases. However, 25% of the sample had type 2a ELN that is at high risk of iatrogenic injury in operations involving resection of the superior thyroid pedicle and ligation of the STA (Kark et al., 1984) warranting knowledge of this anatomic variant

REFERENCES

1. Aina N, Hisham N. 2001. External Laryngeal Nerve In Thyroid Surgery: Recognition And Surgical Implications. *Anz J Surg* 71: 212–214.
2. Cernea C, Ferraz A, Nishio S, Dutra A, Hojaij F, Santos L. 1992. Surgical anatomy of the external branch of the superior laryngeal nerve. *Head Neck* 14: 380–383.
3. Cernea CR, Nishio S, Hojaij FC. 1995. Identification of the external branch of the superior laryngeal nerve (EBSLN) in large goiters. *Am J Otolaryngol* 16: 307– 311. Kark A, Kissin M, Auerbach R, Meikle M. 1984. Voice changes after thyroidectomy: role of the external laryngeal nerve. *Br Med J* 289: 1412-1415.
4. Thwine S, Soe M, Myint M, Than M, Lwin S. 2010. Variations of the origin and branches of the External Carotid artery in a human cadaver. *Singapore Med J* 51: e40-2.
5. Xiao H, Zhuang W, Wang S, Binjie Yu, Chen G, Zhou M, Wong N. 2002. A Novel Approach To Thyroid Ablative Therapy For Graves' Disease. *J Clin Endocrinol Metab* 87: 3583–3589.
6. Vázquez T, Cobiella R, Marañillo E, Valderrama FJ, McHanwell S, Parkin I, Sañudo JR. 2009. Anatomical variations of the superior thyroid and superior laryngeal arteries. *Head Neck* 31: 1078-85.