

## SURGICAL ANATOMY OF THE PROFUNDA BRACHII ARTERY

Anne Pulei, Kevin Ongeti, Martin Inyimili, Julius Ogeng'o

**Correspondence:** Dr. Anne Naipanoi Pulei, Department of Human Anatomy, University of Nairobi. P.O. Box 30197 00100 Nairobi, Kenya. Email: [anmunkush@yahoo.com](mailto:anmunkush@yahoo.com)

### SUMMARY

Variations in the origin and termination of the profunda brachii artery (PBA) are rarely described in literature. Knowledge of this unusual anatomy is important during brachial artery catheterization and harvesting of lateral arm flaps. One hundred and forty four arms from 72 cadavers of black Kenyans were dissected and examined for the origin and termination of PBA at the Department of Human Anatomy, University of Nairobi, Kenya. The patterns of origin and termination of the PBA were observed and recorded. The PBA was present in all the cases. It arose from the brachial, axillary and a common stem with the superior ulnar collateral arteries in 96.9%, 1.4% and 1.7% of the cases respectively. It displayed duplication and early branching in 11.1% and 16.7% of the cases respectively. The high incidence of duplication and early branching makes it vulnerable to inadvertent injury during fractures of the humerus, brachial artery catheterization and may complicate lateral arm flaps. Preoperative angiographic evaluation is therefore recommended.

**Key words: Profunda brachii arteries, variations.**

### INTRODUCTION

Profunda brachii artery (PBA) is the largest branch of the brachial artery (BA) given off in the arm from the posteromedial aspect. It runs posteriorly to join the radial nerve in the radial groove where it gives rise to its deltoid branch, nutrient artery and terminates by bifurcating into middle and radial collateral arteries (Standing et al., 2005). Variant origins and branching patterns have been described (Charles et al., 1931).

These variations are important during harvesting of the lateral arm flaps (Katsaros et al., 1984; Antohi et al., 2005) and may lead to inadvertent injury during percutaneous arterial catheterization or injection of drugs (Evans et al., 1974; Das et al., 2005). There have been case reports on these variations from many populations (Celik et al., 2004; Madhyastha et al., 2009). The frequency and patterns of these variations display ethnic differences (Patnaik et al., 2002). This is the first study that systematically appraises the pattern of origin and termination of the PBA.

### MATERIALS AND METHODS

One hundred and forty four arms from 72 cadavers of adult black Kenyans at the Department of Human Anatomy, University of Nairobi were

dissected for the PBA. Sixty two of these cadavers were male and the rest were female, the age range being 22-69yrs. Vertical incisions were made on the lateral and medial borders of the arm from the coracoid process and axilla proximally to the mid arm. These incisions were joined by transverse ones and the skin flaps were removed. The biceps brachii was sectioned in the middle, the ends retracted and the fascia split to expose the BA in its entire extent from the axilla to the cubital fossa. The PBA was identified as the most proximal branch which joined the radial nerve in the radial groove.

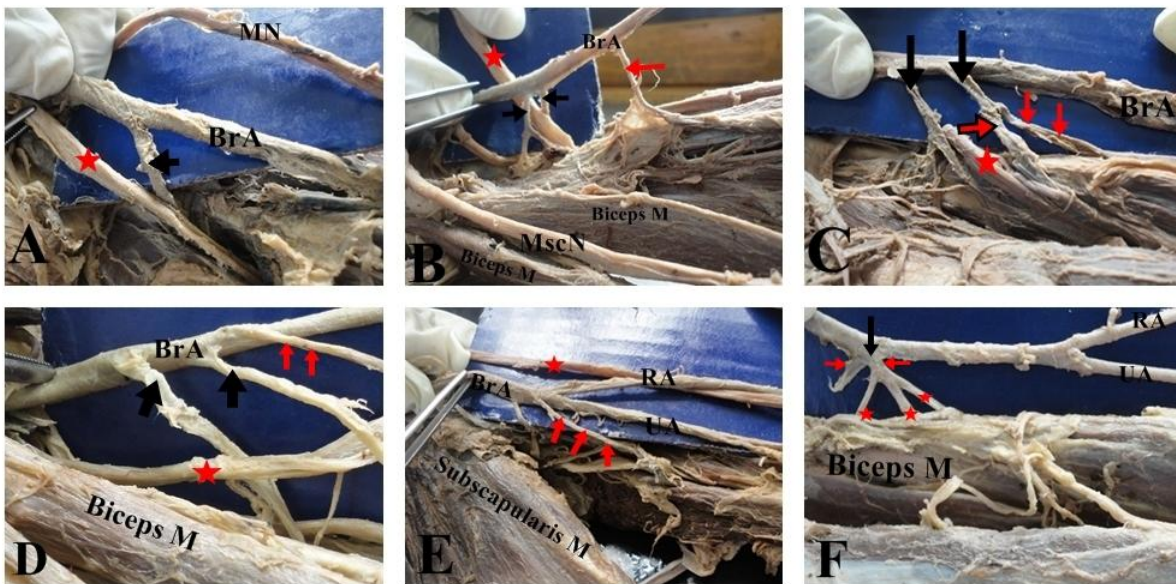
The origins, its relationship with the radial nerve and proximal terminal branching patterns were examined. The results were analyzed using the SPSS<sup>®</sup> version 17 for Windows<sup>®</sup> and presented in tables and macrographs. A p value of  $\leq 0.05$  was considered significant.

### RESULTS

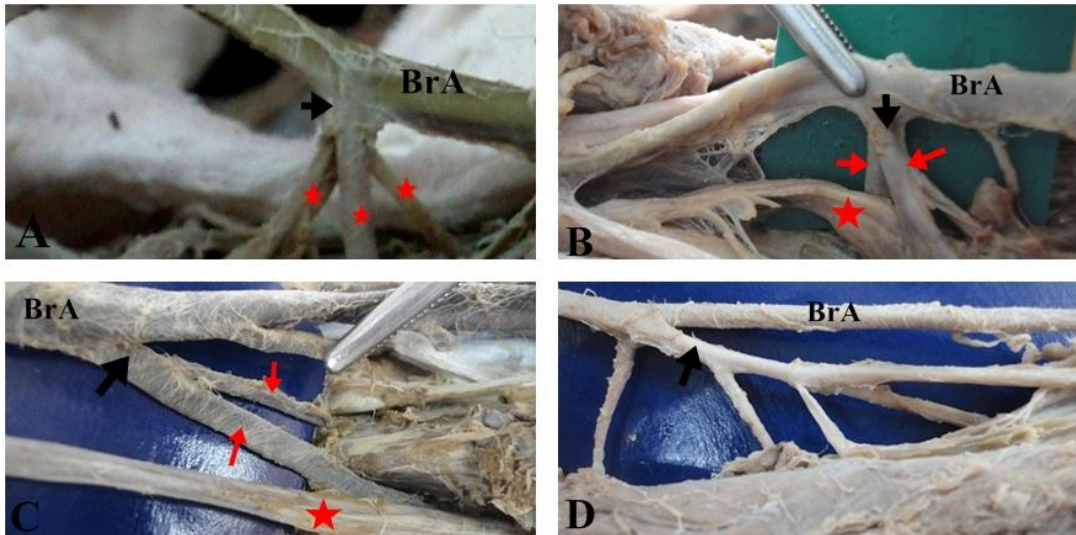
Profunda brachii artery was present in all 144 arms included in this study. It originated from the BA in 98.6% of the cases. Two (1.4%) PBA arose from the axillary artery. The artery displayed the classical pattern in 88 cases (70.9%) entering the

radial groove as a single trunk before dividing into its terminal branches (Fig. 1A). Of those originating from the brachial artery, it was double in 16 cases (11.1%). In six cases, the four branches arose from the same level and the radial nerve passed in between the two trunks (Fig. 1B). In the remainder the arteries arose parallel to each other, in which case the radial nerve either passed in between the two branches, or alongside one of the branches. In two cases, one of the terminal branches of PBA arose from a common trunk with the superior ulnar collateral (Fig. 1C). In four cases (3.2%), the double profunda brachii were associated with high superior ulnar collateral (Fig. 1D). In two cases, the double profunda brachii were associated with high superior ulnar collateral (Fig. 1D). In two cases, the origin of the PBA was part of the trifurcation of the

brachial artery into PBA, ulnar and radial arteries (Fig. 1E). Two of the PBAs arose as a very short trunk that immediately bifurcated into two branches, one of which then trifurcated (Fig. 1F). In 6 cases (4.8%) the PBA trifurcated immediately after its origin into three terminal branches (Fig. 2A). Eighteen (12.5%) profunda brachii divided immediately (within 2cm of its origin) into its two terminal branches, with the radial nerve in between the two trunks (Fig. 2B), or the radial nerve running in parallel with one nerve (Fig. 2C). Table 1 summarizes the above findings. It was noted that more variations were observed on the left than on the right and this proved to be statistically significant with a p value of 0.001 (see Table 2).



**Fig 1: A-F: Pattern of origin of PBA.** A: Single PBA, (arrow), from brachial artery (BrA), entering the radial groove with the radial nerve (red star). MN is the median nerve. B: duplicated PBA (black arrows) with radial nerve in between them (star) Note that the Radial nerve (RN) passes in between the two trunks. Additionally, these two arteries seem to have arisen from the same point on the artery. The red arrow points on the superior ulnar collateral artery. MscN is the musculocutaneous nerve. C: "double" profunda brachii (arrows) where the second artery (radial collateral) arose in common with the superior ulnar collateral. D: double PBAs with high ulnar collateral (red arrow). E: Trifurcation of the brachial artery (BrA), into PBA (arrow), ulnar (UA) and radial (RA) arteries. F very short trunk of PBA (arrow) originating from the brachial artery and immediately bifurcates, one of the arteries further divides into three branches. Note that the brachial artery also divides higher up in the arm into the radial and ulnar arteries.



**Fig. 2: A-D: Pattern of branching of the profunda brachii artery.** A: Immediate trifurcation of the PBA (arrow) BrA is the brachial artery. B: Immediate bifurcation the PBA (vertical black arrow) with the radial nerve (star) in between the two branches (arrow). C: bifurcation, with radial nerve (star) running with one of the branches, radial ulnar collateral. D: PBA (arrow), that is large almost the same size as its mother artery that divides into several branches.

Table 1: Variations of the PBA: patterns of branching.

Variation	Left	Right	Total	
			No	%
Normal branching pattern	44	58	102	70.8
Single trunk with immediate bifurcation	12	6	18	12.5
Single trunk with immediate trifurcation	2	2	4	2.8
Double profunda brachii	12	6	18	12.5
Common trunk of origin with the superior ulnar collateral	2	0	2	1.4
Total	72	72	144	100

Table 2: side to side comparison of the pattern of branching of the PBA

Side	Classical (Usual branching pattern)	Variant branching pattern
Right	29	7
Left	22	14
Total	51	21

p value=0.001

## DISCUSSION

Observations of the present study support the previous reports which suggest that PBA is always present and often arises from the BA (Charles et al., 1931; Anson, 1966). Rarely, it derives its origin from the axillary artery.

Duplications of the PBA were observed in 10% of the cases, higher than the earlier reports of 0.7 to 2% seen in other populations (Patnaik et al., 2002; Celik et al., 2004; Das et al., 2005). This suggests ethnic differences in the bifurcation pattern of this artery. Fractures of the humerus damaging the PBA may cause excessive hemorrhage (Das et al., 2005)

in cases of the double arteries. The high frequency of double PBA suggests that the artery is more amenable to accidental damage and excessive bleeding consequent to fracture of the humerus. This implies that surgeons and interventional radiologists should exercise extra diligence when operating on the BA.

The PBAs divides early into two or three branches which enter the radial groove separately. Such variations have not been described in literature before although they affect length of the branches which in turn influences the length and the depth of the musculocutaneous lateral arm flap (Antohi et

al., 2005; De Souza et al., 2010). In addition, the association of the PBA with high origin of the superior ulnar collateral artery as in the case of the common trunk predisposes the latter to inadvertent injury during flap harvesting or other procedures of the arm (Madhyastha et al., 2009).

In conclusion the profunda brachii artery in this population has a high incidence of duplication and early branching. These make it vulnerable to inadvertent injury during fractures of the humerus, brachial artery catheterization and may complicate lateral arm flaps. Preoperative angiographic evaluation is recommended.

**Acknowledgement:** We are thankful to the staff of Gross Anatomy Laboratory namely Mr. Jacob Gimongo, Charles Githinji and Peter Nziu for their technical support.

**Conflict of interest: None**

**Source of funding: None**

## REFERENCES

1. Antohi N, Stingu C, Stan V. 2005. The use of free flap transfer in upper extremity reconstruction. *Tim Med J* 1: 27-35.
2. Anson BJ. 1966. *Morris' Human Anatomy In: The cardiovascular system - Arteries and veins*; Thomas M; Oelrich Eds. McGraw Hill Book Co; The Blackiston Division, New York, pp. 708-724.
3. Celik HH, Aldur MM, Tunali SS. 2004. Multiple variations of the deep artery of the arm: double deep artery of the arm and deep artery of arm with the superior ulnar collateral. A case report. *Morphologic*. 88: 188-190.
4. Charles CM, Pen L, Holden HF, Miller RA, Elvis EB. 1931. The origin of the deep brachial artery in American white and American Negro males. *Anat rec* 50: 299-302.
5. Das S, Singh S, Paul S. 2005. Double profunda brachii and abnormal branching pattern of the brachial artery. *Tim Med J* 2: 159-161.
6. De Souza FI, Saito M, Torres LR, Wet TH, Jumor RM, Zumiotti AV. 2010. Anatomic study of the lateral arm flap with retrograde flow. *Acta Orthop Bras*. 18 1: 39-43.
7. Evans JM, Latto IP, Ng WS. 1974. Accidental intraarterial injection of drugs: a hazard of arterial cannulation. *Br J Anesthesia* 46: 463-436.
8. Katsaros J, Schursterman M, Beppu M. 1984. The lateral upper arm flap; Anatomy and clinical applications. *Ann Plast Surg* 12: 489 – 500.
9. Madhyastha S, Nayak SR, Krishnamurthy A, D'costa, Jose AA, Bhat KMR. 2009. Case report of high origin of radial, ulnar and profunda brachii arteries, its clinical implications and review of literature. *J Vasc Bras* 8: 374-378.
10. Patnaik WG, Kalsey G, Singla RK. 2002. Branching pattern of the brachial artery. A morphological study. *J Anat Soc India* 51: 176-186.
11. Standring S, Johnson D, Ellis H, Collins P. 2005. *Gray's Anatomy*, 39<sup>th</sup> edition. Churchill Livingstone, London. 356.