

## FLORID CEMENTO-OSSEOUS DYSPLASIA: A REPORT OF TWO CASES SEEN AT THE UNIVERSITY COLLEGE HOSPITAL IBADAN

A.O. Lawal<sup>1</sup>, A.O. Adisa<sup>1</sup>, and T.J. Lasisi<sup>2</sup>

1. Department of Oral Pathology, College of Medicine, University of Ibadan, Nigeria.

2. Department of Oral Pathology, University College Hospital, Ibadan Nigeria.

Attribute to Department of Oral Pathology, College of Medicine, University of Ibadan, Nigeria

### Correspondence:

**Dr. A.O. Lawal**

Department of Oral Pathology,

College of Medicine,

University of Ibadan.

E-mail: toytoy219@yahoo.com

Tel: +2348055133964.

### SUMMARY

**Florid cemento-osseous dysplasia (FCOD) is commonly seen in black women, but few cases have been reported in sub-Saharan Africa. This article presents two cases of FCOD seen at the University College Hospital Ibadan.**

**Two women aged 70 and 60 years were initially diagnosed as chronic osteomyelitis but both were eventually diagnosed as florid cemento-osseous dysplasia after radiological examination by orthopantomogram.**

**Diagnosis of florid cemento-osseous dysplasia is possible by clinical examination and the distinct radiological presentation, especially on orthopantomogram and a biopsy may not be required.**

**Keywords:** Florid cemento-osseous dysplasia, women, Ibadan.

### INTRODUCTION

Cemento-osseous dysplasias are a group of disorders known to originate from periodontal ligament tissues and involve essentially the same pathological process.<sup>1</sup> They are usually classified depending on their topography and radiographic appearances, into three main groups: periapical, focal and florid cemental dysplasias.<sup>1</sup>

Florid cemento-osseous dysplasia was first described by Melrose *et al*<sup>2</sup> in 1976. This condition has been interpreted as a dysplastic lesion or developmental anomaly arising in tooth-bearing areas.<sup>2</sup> Florid cemento-osseous dysplasia is more commonly seen in middle-aged black women although it may also occur in Caucasians and Asians.<sup>3,4</sup> The processes may be totally asymptomatic and may be detected incidentally when radiographs are taken for some other purposes. Symptoms such as dull pain or drainage are almost always associated with exposure of sclerotic calcified masses in the oral cavity.<sup>5</sup> This may occur as the result of progressive alveolar atrophy under a denture or after extraction of teeth in the affected area.<sup>5</sup>

The lesions show a marked tendency for bilateral symmetric involvement, and it is not unusual to encounter extensive involvement of all four posterior quadrants.<sup>2</sup>

Although FCOD is said to be commonly seen in middle aged black women, report of cases from sub-Saharan Africa, especially Nigeria the most populous

black nation, is rare. We present a report of two cases seen at the University College Hospital Ibadan.

### Case Profile

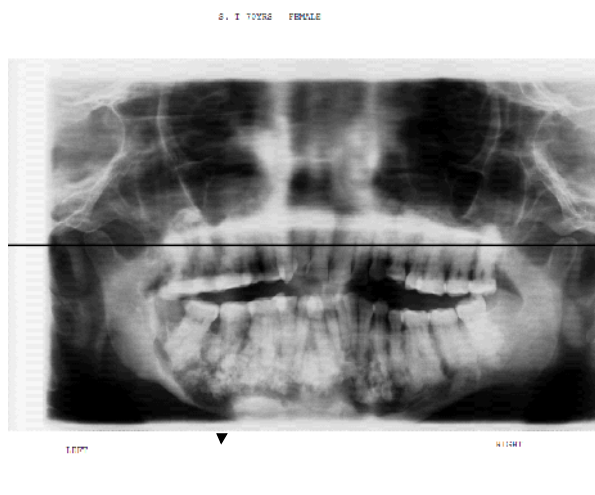
#### Case 1

A 70 year old woman presented at the dental outpatient clinic of the University College Hospital Ibadan, with a 16 year history of pain and discharge from a sinus located on the left jaw. She had presented 10 years earlier at the same clinic but absconded due to financial constraints. On examination, there was a tender swelling on the left body of the mandible with a discharging sinus in relation to teeth 34, 35 and 36. Oral hygiene was poor and there were no carious teeth but there was an area of necrotic bone exposure in the region of 32, 33, 34, 35 and 36. An initial diagnosis of chronic suppurative osteomyelitis was made. An orthopantomogram however showed diffuse mottled radio-opaque masses within the body of the mandible extending from tooth 38 to tooth 48 (Fig 1). A diagnosis of florid cement-osseous dysplasia complicated by chronic suppurative osteomyelitis was thus made. The patient was placed on oral clindamycin tablets 300mg bid but was subsequently lost to follow up.

#### Case 2

A case of a 60 year old woman who presented at the dental clinic of the University College Hospital Ibadan, with a 3 months history of tooth ache and jaw swelling which had been progressively increasing in size.

She had applied traditional medicine without any appreciable relief. There was no relevant medical history. Examination revealed a healthy looking woman, not pale or jaundiced. There was a warm, tender, diffuse swelling on the left body of the mandible. Intra-oral examination showed poor oral hygiene with swelling and pus discharge in the left buccal sulcus in relation to tooth 37. No carious teeth were observed, tooth 36 was however, tender to percussion. On radiological examination, Orthopantomogram showed widespread radio-opaque masses affecting all four quadrants of the jaws with a



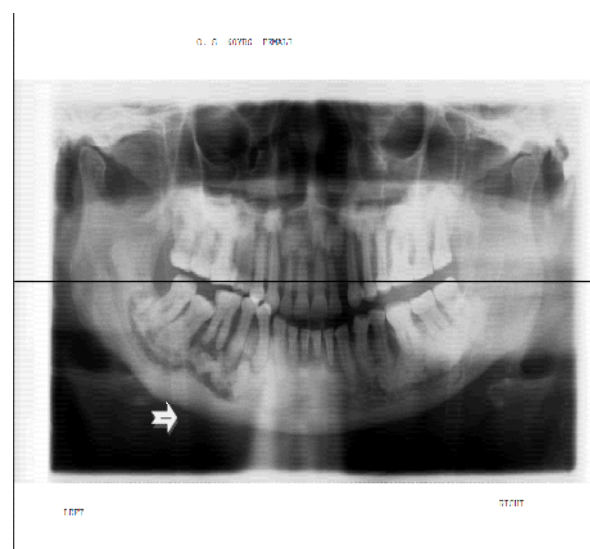
sequestrum forming on the left mandibular quadrant and tooth 36 floating in its socket (Fig 2).

## DISCUSSION

The term florid cemento-osseous dysplasia (FCOD) has been proposed in the second edition of the World Health Organisation's (WHO) 'International histological classification of Odontogenic tumours' to replace the first edition's term 'gigantiform cementoma'.<sup>6</sup> The disorder is strictly localized to the tooth-bearing areas and not associated with any other skeletal disease. The affected area undergoes changes from normal vascular bone into an avascular cementum-like lesion.<sup>1</sup> The lesion is usually benign and requires no treatment unless cosmetically embarrassing, however, treatment of a secondary infection of this lesion can be difficult and complicated.<sup>7</sup> The aetiology of FCOD is unknown, although, some authors have proposed that a reactive or dysplastic process of the periodontal ligament may be involved.<sup>8, 9</sup> These lesions are characterized by replacement of bone by connective tissue matrix, which displays varying degrees of mineralization in the form of woven bone or cementum-like round basophilic acellular structures.<sup>10</sup>

The two cases presented in this report were both complicated by chronic osteomyelitis and were not seen in the commonest age group of occurrence in the 4<sup>th</sup> and 5<sup>th</sup> decades of life. This might be due to the possibility that the lesions were present but asymptomatic for years and were only noticed when they became symptomatic. One of the patients actually first presented over a decade ago with symptoms but absconded.

Florid cemento-osseous dysplasia is often misinterpreted as chronic sclerosing osteomyelitis, especially when associated with pain and discharge. However, chronic diffuse sclerosing osteomyelitis is a primary inflammatory condition of the mandible presenting with cyclic episodes of unilateral pain and swelling and shows a single area of diffuse sclerosis containing small, ill-defined osteolytic areas,<sup>1</sup> whereas, florid cemento-osseous dysplasia is seen as multiple round or lobulated opaque masses.<sup>2</sup> In addition, florid cemento-osseous dysplasia is frequently associated with black women, while chronic diffuse sclerosing osteomyelitis is seen predominantly in adult Caucasian men.<sup>2</sup> Another differential diagnosis of FCOD is Paget's disease, but the dysplastic lesions in Paget's disease are polystotic and the disease also shows biochemical serum changes.<sup>1</sup>



FCOD may also show similarities with jaw bone changes seen in familial adenomatous polyposis (Gardner's syndrome), but FCOD has no other skeletal changes or skin tumours or even the dental anomalies that are seen in Gardner's syndrome. Some authors have reported cases of familial FCOD with autosomal dominant inheritance pattern in some cases, although in most of the cases, the mode of genetic transmission remains unclear.<sup>4, 5, 8</sup> Both of our cases were however

non- familial as no positive family history was found, and this was in conformity with most other reports.<sup>4,5,8,10</sup>

The two cases presented were diagnosed based on clinical and radiological presentations only. FCOD may be diagnosed on the basis of clinical history and radiological examination and biopsy may be complicated by infection and jaw fracture<sup>1,2</sup>.

In conclusion, florid cemento-osseous dysplasia usually presents as an asymptomatic condition that may be detected incidentally. As shown in the two cases reported above, it should be considered as a differential diagnosis of chronic sclerosing osteomyelitis especially in black women. A good clinical examination and radiographs such as an orthopantomogram may be sufficient to make a diagnosis.

## REFERENCES

1. **Jerjes W**, Banu B, Swinson B and Hopper C. Florid Cemento-osseous dysplasia in a young Indian woman. A case report. *Br Dent J* 2005; 198(8): 477-478.
2. **Dađistan S**, Tozođlu U, Göregen M, Çakur B. Florid Cemento-osseous dysplasia: A case report. *Med Oral Pathol Oral Cir Bucal* 2007; 12:E348-50.
3. **Gonçaves M**, Pispico R, Abreu Alves F, Lugão CB, Gonçaves A. Clinical, radiographic, biochemical and histological findings of florid cemento-osseous dysplasia and report of a case. *Braz Dent J* 2005; 16:247-50.
4. **Jakowski MD**. Florid Cemento-osseous dysplasia: A systemic review. *Dentomaxillofac Radiol* 2003 32: 141-149,
5. **Beylouni I**, Farge P, Mazoyer JF, Coudert L. Florid cementoosseous dysplasia. *Oral Surg Oral Med Oral Pathol Oral Radiol Endod* 1998; 85: 707-11.
6. **Kramer IRH**, Pindborg JJ, Shear M. Histological typing of odontogenic tumours. World Health organization International Histological Classification of Tumours (2<sup>nd</sup> edn). Berlin, Germany: Springer-Verlage, 1992.
7. **Bencharit S**, Schardt-Sacco D, Zuniga J R, Minsley G. Surgical and prosthodontic rehabilitation for a patient with aggressive florid cemento-osseous dysplasia: A clinical report. *J Prosthet Dent* 2003; 90(3):220-224.
8. **Waldron CA**: Fibrous lesions of the jaws. *J Oral Maxillofac Surg* 1985; 43: 249-262.
9. **Waldron CA**: Fibro-osseous-lesions of the jaws, *J Oral Maxillofac Surg* 1993; 51: 828-35.
10. **Mangala M**, Ramesh DN, Surekha PS, Santosh P. Florid Cemento-osseous dysplasia: Review and report of two cases. *Indian J Dent Res* 2006;17:131