

## Case Report

### Uterus bicornis unicollis; Occurrence of consecutive viable pregnancies in separate horns. I O Morhason-Bello, I E Ojoko, K M Owonikoko, O Olayemi, AO Omigbodun

Correspondence:

Dr I.O. Morhason-Bello

Department of Obstetrics & Gynaecology,  
University College Hospital,  
Ibadan.

Email: [onembello@yahoo.co.uk](mailto:onembello@yahoo.co.uk)

Mobile phone: 2348034784402

#### SUMMARY

A case of two-consecutive viable pregnancies in separate horns of bicornuate unicollis uterus of a Nigerian is presented. The problem of misdiagnosis associated with the anomaly is noted. This case further demonstrates that women with such anomaly may not have unhindered reproductive carrier and antenatal care will improve their chance.

**Keywords:** *Congenital abnormalities, bicornuate uterus, Mullerian duct abnormalities.*

#### INTRODUCTION

Congenital anomaly of the uterus result from varying degrees of failure of fusion of Mullerian ducts but may occasionally arise from true duplication of the ducts<sup>[1]</sup>. This variability makes their diagnosis very tasking even when radiological investigations such as ultrasonography, hysterosalpingography, and magnetic resonance imaging are used<sup>[1, 2]</sup>. Three-dimensional ultrasound has been shown to improve the accuracy of diagnosis<sup>[3]</sup>.

The incidence reported in the literature ranges between 0.13 – 0.4 percent among the general population<sup>[4, 5]</sup>. Simon et al also, reported about 3.2 percent of fertile women to have bicornuate uterus<sup>[6]</sup>.

Pregnancy occurs despite this anomaly but, only few advance to term without any complication. Studies have shown that offspring of mothers with bicornuate uterus are at risk of both deformations (limb contractures, scoliosis, and club foot) and malformations (omphalocele, teratoma, microcephaly and acardia-anecephaly)<sup>[7, 8]</sup>.

#### CASE REPORT

An unbooked 32-year old Nigerian, carrying her fourth pregnancy, presented on the 8<sup>th</sup> of July 2006 at the University College Hospital, Ibadan with a 2-hour history of labour pain, without vaginal bleeding or liquor drainage, at a gestational age of 35-weeks. The patient received no antenatal care and had no obstetric ultrasound in this pregnancy. She had a normal hospital-supervised pregnancy and vaginal delivery in 1994. She had an emergency caesarean section at 38 weeks in another hospital in 2000, the records of which were unavailable. In 2003, the patient had a second caesarean delivery in our hospital at which the fetus was found to be lying longitudinal in the **left** horn of a bicornuate uterus contrary to a preoperative diagnosis of transverse lie. The baby's birth weight was 2.95kg

After the initial evaluation, she refused bilateral tubal ligation as a method of contraception despite the two previous caesareans but consented to the operative delivery. The patient had an emergency caesarean section (her third) shortly after her admission. The intraoperative findings were: pelvic adhesions, bicornuate uterus (the fetus was occupying the **right**

horn while the left horn was enlarged to the size of a 14-week gravid uterus with a visible scar). A live male infant weighing 2.45kg, with Apgar scores of 5 and 10 at 1 and 5-minutes respectively. The appearance of the uterus shortly after repair of the uterine incision is shown in figures 1 and 2. Speculum examination performed on the 4<sup>th</sup> postoperative day showed a single cervix (figure 3). She had an uneventful postoperative period and her baby had no malformation. The patient was discharged home on the 7<sup>th</sup> postoperative day with a progestogen-implant for contraception following her refusal for sterilization.

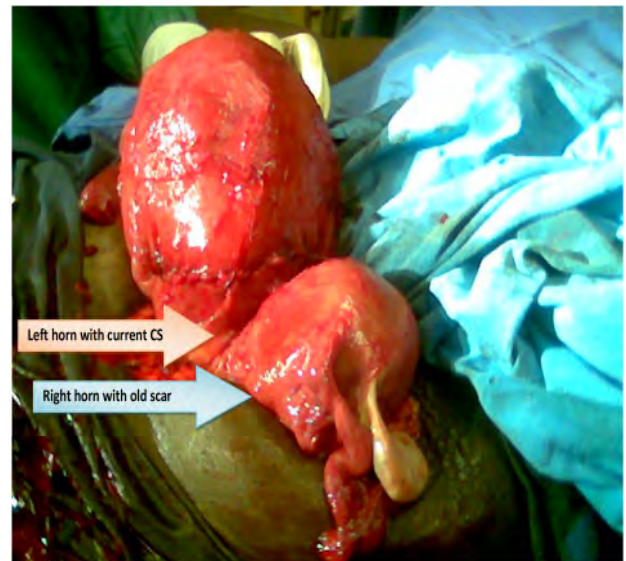


Figure1: Showing the double uterus intraoperatively

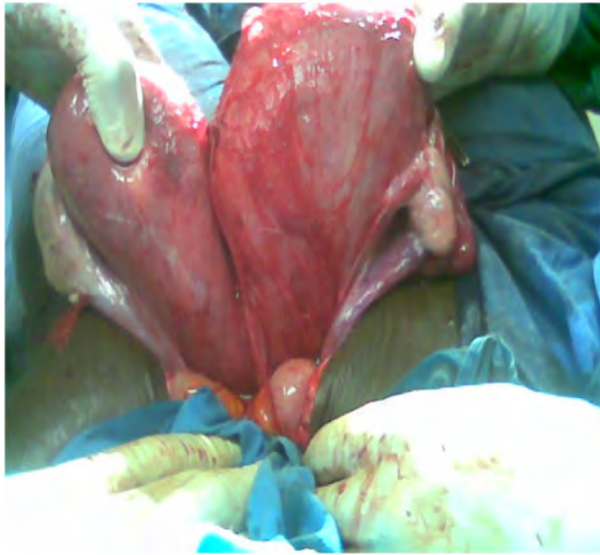

Figure 2: Showing the posterior view of the bicornuate uterus and ovaries

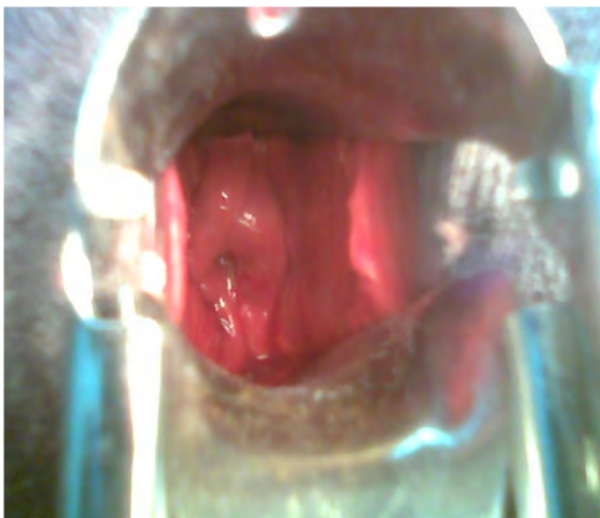

Figure 3: Speculum examination showing a single cervix.

## DISCUSSION

Mullerian duct anomalies are generally rare and often associated with infertility, recurrent pregnancy loss, preterm labour, uterine rupture and other obstetric complications which increase perinatal morbidity and mortality [4, 9]. However, few cases of mothers with especially bicornuate uterus (uterus duplex) have been reported with successful term delivery in the literature [1, 6]. Also, the occurrences of twin pregnancy occupying separate horns of a bicornuate uterus following both normal and assisted conception have been reported [10, 11, 12].

The patient reported had bicornuate unicollis uterus. To our surprise, she had two successful viable deliveries from separate horns. Misdiagnosis of fetal presentation

resulting from abnormal configuration of the fundus of the uterus in the third trimester may be a challenge as it was the case in this patient [1].

One of the challenges that are associated with uterine abnormalities is preterm delivery as shown in this case [9]. Despite the non-attendance of antenatal care by this Nigerian woman, she was fortunate to be delivered at a tertiary health institution where experienced paediatricians are available on twenty-four hour coverage to resuscitate the newborn. This case underscores the importance of routine antenatal care where at least one obstetric Ultrasonography could have assisted in the diagnosis of the abnormal uterus and thus prevented the misdiagnosis of abnormal lie that may have responsible for all the caesarean deliveries.

It is important that clinicians are aware that women with bicornuate uterus could have a successful reproductive carrier contrary to the widely held view. In addition, Nigerian women should be encouraged to attend antenatal care as this will assist in better evaluation of their clinical conditions rather than presenting as an emergency in labour.

## References

1. **Muckle CW.** Developmental abnormalities of the female reproductive organs. In: Gynecology and Obstetrics Looseleaf CD-Rom. 2001. Vol1, Chp 3. Lippincott Williams & Wilkins Publisher.
2. **Valdes L, Malini S, Malinak LR.** Ultrasound evaluation of female genital tract anomalies: A review of 64 cases. *Am J Obstet Gynecol.* 1984; 149(3): 285-92.
3. **Raga F, Bonilla-Musoles F, Blanes J, Osborne NG.** Congenital Mullerian anomalies, diagnostic accuracy of three dimensional ultrasound. *Fertile Steril.* 1996; 65, 523-528.
4. **Golan A, Langer R, Bukarsky I, Capsi E.** Congenital anomalies of Mullerian system. *Fertil. Steril.* 1989; 51:747-55
5. **Heinonen PK, Saarikoski S, Pystyren P.** Reproductive performance of woman with uterine anomalies. *Acta Obstet Gynecol Scand.* 1982; 61, 157-162.
6. **Simon C, Martinex I, Pardo F, Tartajada M, Pellicor A.** Mullerian defefcts in women with normal reproductive outcome. *Fertil Steril.* 1991; 56(6):1192-3.
7. **Martinez-Friaz ML, Bermejo E, Rodriguez-Pinillain E, Friaz JL.** Congenital anomalies in the offspring of mothers with a bicornuate uterus. *J Pediatr.* 1998; 101(4):10.
8. **Winter RM, Dearlove J, Jolly H, Pawson N, Wilson RG.** Apparent microcephaly caused by a

- bicornuate uterus. *Br Med J (Clin Res Ed)*. 1983; 286(6378):1640-1.
9. **Ibrahim Syed *et al.*** Uterus, Mullerian duct abnormalities. An Online review article in emedicine website. Aug 13, 2002.
  10. **Kuczynski AW, Szczesniak W, Szczygielski A.** A case of successful twin pregnancy placed in separate horns of bicornuate, unicollis uterus. *Acta Genet Med Gemellol (Roma)*. 1998; 47(3-4):201-4.
  11. **Barmat LI, Damario MA, Kowalik A, Kligman I, Davis OK, Rosenwaks Z.** Twin gestation occupying separate horns of a bicornuate uterus after in-vitro fertilization and embryo transfer. *Hum Reprod*. 1996; 11(10):2316-8.
  12. **Aruh I, Aslan D, Karaarslan F, Pinar T, Keles R, Demir N.** Twin pregnancy in the horns of a bicornuate uterus after in vitro fertilization and split embryo transfer: a case report. *J Reprod Med*. 2005; 50(3):213-5.