

Spontaneous Appendicocutaneous Fistula

A Case Report

Dr O. M. Tokode* MB, BS
and

Dr O. A. Awojobi† FMCS (Nig)

ABSTRACT

Ruptured appendicitis is not a common cause of spontaneous enterocutaneous fistula. A case of ruptured retrocaecal appendicitis presenting as an enterocutaneous fistula in a Nigerian woman is presented. The literature on this disorder is also reviewed.

INTRODUCTION

Spontaneous appendicocutaneous fistula following acute appendicitis is a rare clinical entity.¹⁻⁸ It is defined as the primary perforation of the appendix to an adjacent area of the skin, excluding fistulae arising as a sequela of surgically treated appendicitis.⁷

However, it has been reported with granulomatous appendicitis⁹ Crohn's disease¹⁰ and when a malignancy in the appendix caused a mucocoele, which ruptured into the retroperitoneal space eventually draining via cutaneous sinuses.^{11,12}

Enterocutaneous fistula following retrocaecal appendicitis usually involves the caecum or ascending colon.

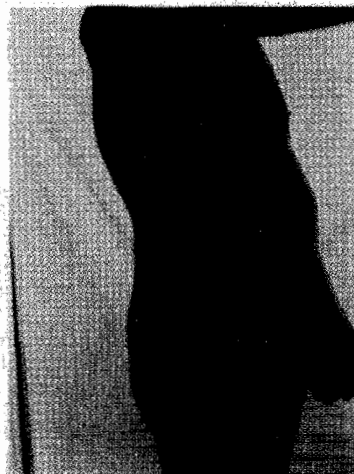In the present communication, we report a case of spontaneous appendicocutaneous fistula complicating retrocaecal retroperitoneal appendicitis in a Nigerian woman.

CASE PROFILE

BS, a 38-year-old female farmer presented at Awojobi Clinic Eruwa on 7th September 2000 with passage of undigested food particles through a sore in the right flank of six years duration. The discharge

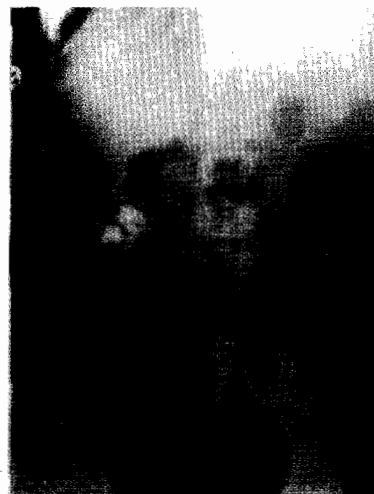
was preceded by a painful right lower quadrant abdominal swelling which spontaneously discharged a lot of pus through the sore.

Examination showed a healthy looking woman with a fistula in the right flank just superior to the iliac crest, discharging intestinal contents (Fig 1).



Fistula opening just superior to the iliac crest.

Her packed cell volume was 40% and white cell count of 3000/mm³ with normal differentials. Fistulography using 60% urograffin showed a single tract leading into the proximal ascending colon and the caecum (Fig 2).



Fistulogram showing the tract to the ascending colon and caecum.

Exploratory laparotomy revealed a retroperitoneal retrocaecal appendix with a colocutaneous fistula

All Correspondence to:

Dr Oluyombo A. Awojobi
Awojobi Clinic Eruwa
P O Box 5, Eruwa, Oyo State, Nigeria.
e-mail: oluyombo1@yahoo.com
Key words: appendicocutaneous fistula fistulogram

*Department of Surgery,
University College Hospital,
Ibadan, Nigeria.

†Awojobi Clinic Eruwa, Eruwa,
Oyo State, Nigeria.

tract into the ascending colon at the tip of the shrunken appendix which was adherent to the colon. No intraperitoneal pathology was found. The defect in the colon was closed in two layers with 0 silk and appendectomy was performed. She made uneventful recovery and was discharged on the seventh postoperative day.

Histopathology report read: 'Piece of appendectomy specimen measuring 5.5cm in length and 1.3cm in its widest width. The serosal surface is moderately congested and the lumen in the middle third is distended with faecal materials. Sections show moderate infiltration of appendiceal mucosa and submucosa by plasma cells and eosinophils, polymorphs, with mild involvement of the muscularis propria. There is mucosal lymphoid hyperplasia with prominent germinal centre. These features are consistent with eosinophilic appendicitis.'

She has been followed up for four years and her condition has remained satisfactory with no recurrence of the fistula.

DISCUSSION

An intestinal fistula is an abnormal tract that communicates between the intestinal mucosa and another epithelial surface. In enterocutaneous fistula the other epithelial surface is the skin and intestinal contents are discharged externally.

The common acquired causes of enterocutaneous fistula include strangulated groin hernia especially femoral hernia, tuberculosis and other granulomatous infections, diverticular disease of the bowel, Crohn's disease, carcinoid tumour and carcinoma of the caecum and appendix.⁹⁻¹⁵

Appendiceal fistula has been the presentation of pseudomyxoma retroperitonei a late complication of mucinous adenocarcinoma of the appendix.^{11,12}

Most enterocutaneous fistulas in this environment have been complications of surgery for peritonitis due to typhoid ileitis, perforated appendicitis, perforated duodenal ulcer, penetrating injuries of the abdomen, septic criminal abortion and intestinal amoebiasis.^{13,16-21} It has followed incomplete appendectomy.⁸

Spontaneous appendicocutaneous fistula complicating acute appendicitis is rare. The cutaneous opening has been in the buttock,⁴ right iliac fossa⁵ the right groin⁶ and in the right flank as in our case report. More common appendiceal fistulas have involved the urinary bladder, colon, duodenum and ileum.³

The effect of the fistula on the patient is least pronounced being a low output fistula the loss of fluids, electrolytes and nutrients is minimal.

Diagnosis is confirmed by fistulography. This displays the fistula tract and its connection to the gut, its level and the presence of associated abscess cavity or distal obstruction. Barium enema with air contrast helps to detect any associated colonic disease like diverticulitis, Crohn's disease or polyposis coli.

The treatment of appendiceal fistula is appendectomy and closure of the colonic defect. No recurrence is expected if there is no other associated pathology.

REFERENCES

1. Bode C O and Odelola M A Entero-cutaneous fistula of the vermiform appendix in childhood: case report. *West Afr J Med* 2000; 19: 154-5.
2. Skaane, P Spontaneous Appendicocutaneous fistula: Report of a case and review of the literature. *Dis Colon Rectum* 1981; 24: 550-4.
3. Nanni, G, Bergamini, C Bertoncini, M and Nanni G. Spontaneous appendicocutaneous fistula: Case report and literature review. *Dis Colon Rectum* 1981; 24: 187-190.
4. Hedner, J, Jansson R and Lindberg, B. Appendicocutaneous fistula: A case report. *Acta Chir Scand* 1978; 144: 123-4.
5. Koak Y, Jeddy, T A and Giddings A E. Appendicocutaneous fistula. *JR Soc Med* 1999; 92: 639-640.
6. Jacob, V and Mohan CVR. Spontaneous appendicocutaneous fistula: A case report. *Christian Med Coll Alumni J* 2002; 36: 15-8.
7. Kjellman T Appendiceal fistulae and calculi. Review of literature and report of three cases *Acta Chir Scand* 1957; 113: 123-139.
8. Hyett A Appendicocutaneous fistula: A hazard of incomplete appendectomy. *Aust NZ J Surg* 1995; 65: 144-5.
9. Richard ML, Aberger, FJ and Landercasper J Granulomatous appendicitis: Crohn's disease, atypical Crohn's or not Crohn's at all? *J Am Coll Surg* 1997; 185: 13-17.
10. Morita H, Murakami H, Kawal S and Kobori O Appendiceal fistulae formation as a complication of primary Crohn's disease prior to surgical management; report of a case *Surgery Today* 1996; 26: 340-344.
11. Stevens K J, Dunn W K and Balfour T. Pseudomyxoma extraperitonei: a lethal complication of mucinous adenocarcinoma of the appendix. *Am J Gastroenterol* 1997; 92: 1920-1922.
12. Koizumi J and Noguchi, H. Pseudomyxoma retroperitonei with spontaneous skin fistula. *Abdominal Imaging* 199; 24: 193-195.
13. W2 General Surgery Unit. An unusual fistula of

- the groin: A case for diagnosis. *The Ibadan Surgeon* 1977; 1: 7 13.
14. Subramanyam S G, Kilpadi, A B and Sunder N. Ileocaecal tuberculosis presenting as abdominal wall sinus. *Trop Doctor* 2003; 33: 246.
15. Jagdish S, Ninan S, Pai D and Ratnakar C. Spontaneous appendicocutaneous fistula. *Indian J Gastroenterol.* 1996; 15: 31.
16. Ohanaka C E, Momoh I M and Osime U. Management of enterocutaneous fistulae in Benin City Nigeria. *Trop Doctor* 2001 31: 104 106.
17. Ikechebelu J I and Okoli C C. Morbidity and mortality following induced abortion in Nnewi, Nigeria. *Trop Doctor* 2003; 33: 170 172.
18. Olurin E O, Ajayi O O and Bohrer S P. Typhoid perforations. *JR Coll Surg Edinb* 1972; 17: 353 363.
19. Odunjo E O. Pathological manifestations of amoebiasis in Nigerians. *West Afr Med J* 1969; 18: 117 120.
20. Adotey J M. External intestinal fistulae in Port Harcourt. *West Afr J Med* 1995; 14: 97 100.
21. Nwabunike TO. Enterocutaneous fistulas in Enugu, Nigeria. *Dis Colon Rectum* 1984; 27: 542 4.