

"The Practice of Scientific Medicine in Private Practice : Fetal Biometric Parameters in Obstetric Screening Ultrasonography"

L.K. Obembe

L.K. Obembe is an Obstetric, Gynaecologist and CEO of Christus Specialists' Hospital (Nig.) Ltd. Olode, Ibadan

KEY WORDS

Biometric parameters, Birth attendants, Ultrasonography,

INTRODUCTION

SINCE the 1970s', ultrasound scanning has become a routine element of antenatal care in the United States of America¹ and Europe². As a major non-invasive diagnostic tool, it facilitates accurate estimation of gestational age, diagnosis of congenital abnormalities and indicates the presence of multiple fetuses³. Although, there has been a lot of controversy about the cost-effectiveness of routine scanning, there have been sufficient grounds of evidence for believing that it might be cost saving to the health care system⁴.

Apart from its diagnostic capabilities, routine ultrasound scanning has important psychological consequences. It is said to contribute to positive health behaviour⁵, reduce anxiety in patients⁶, and stimulate parental bond with the fetus in utero⁷. Also many prospective parents see ultrasound scan as a means of learning about their future child's gender⁸.

Traditional birth attendants (TBA) have existed in every community from ancestral era, and their practice heralded the profession of Midwifery and Obstetrics⁹. In modern day Obstetric practice, the role of these cadre of practitioners cannot be dismissed with disparaging disdain, as they practise according to the dictates of their religions, spiritual beliefs and tenets. In many communities in sub-Saharan Africa, the churches

and mosques assemble more than 80% of antenatal patients, while about 15% attend the secondary health care institutions and 5% the tertiary.

These women (TBA) popularly called "Iya Agbebi" in Yoruba language, have gained the confidence of the pregnant women because (a) they are readily available 24 hours of the day (b) they fast and pray with their patients for safe delivery (c) they charge less because there is no burden of imposed standards and (d) they treat their patients with decorum, humane and compassionate companionship.

The statistical picture of the overall Maternal Mortality Rate (MMR) in sub-Saharan African has been very gloomy. In Nigeria, the figure quoted is 1500, Ghana 1,400, Gambia 1,700, per 100,000 deliveries. Nigeria suffers 10% of the World's Maternal Deaths, yet has less than 2% of the world population.

Since the time Ultrasound was introduced to Obstetric practice in Christus Specialists Hospital (1986), the advantages of screening ultrasonography in prophylactic Obstetric practice have been repeatedly emphasised. It becomes exquisitely imperative to devise ways of introducing the ultrasound facilities to all categories of staff, including Faith Home birth attendants who take care of a large proportion of gravid and parturient women in our society. Co-operation at this primary health care level in this respect would definitely reduce the MMR.

Up till now, Obstetric ultrasound is hardly given the required prominence in the lecture schedule of undergraduate medical students, and many residency programmes hardly make ultrasound compulsory. The objective of this article is to highlight the "fetal biometric parameters in Obstetric screening ultrasonography" and its

All Correspondence Dr. L.K. Obembe FMCOG, FWACS, FAGP, FICS.

Consultant Obstetrician and Gynaecologist
Christus Specialists' Hospital (Nig.) Ltd.
Zion Building, Kayode Obembe Crescent, Olode,
P.O. Box 29259 Sec. P.O.
Ibadan.
E-mail :- Obembe@skannet.com.ng
Telephone/Fax :- 02 - 2410052,
Telephone:- 02 - 2413750

application to health workers, especially mission houses, maternities and primary health care centres so as to enrich the knowledge of all.⁴

Biometric Parameters

The following Fetal Biometric Parameters are determined in order to assess the fetal well being:-

1. Gestational Sac diameter - (GSD)
2. Crown Rump Length - CRL
3. Biparietal diameter - (BPD)
4. Occipitofrontal diameter - (OFD)
5. Head Circumference - (HC)
6. Abdominal Diameter - (AD)
7. Abdominal Circumference - (AC)
8. Femur Length - (FL)
9. Orbits -
10. Placental Abnormalities -

(1) Gestational Sac Diameter (GSD)

The first sonographic sign of intrauterine pregnancy is the appearance of the gestational sac. This is a cystic ringlike structure, representing the chorionic cavity, bordered by a thickened ring of

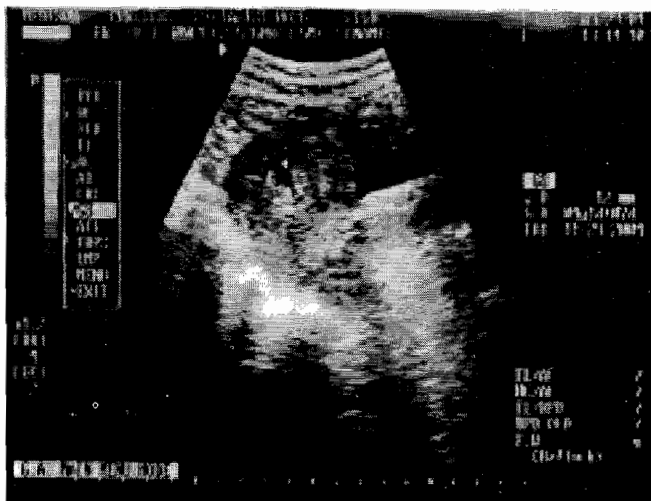


Fig. 1
Sagittal scan demonstrating the appearance of the gestational sac 4 weeks 1 day. The GS diameter is 12mm (G = Gestational Sac)

echoes that corresponds to the trophoblastic ring. The wall mass appears as a double line which is generated by the junction of the decidua parietalis and capsularies.

Qualitatively speaking, the gestational sac is 4-5 week cysis if the sac is echofree, normal shape and diameter less than 20mm. In 90% of cases the 5 accuracy is only \pm 2-3 weeks in gestational dating, and so GSD has not been widely applicable¹⁰. (Fig. 1).

(2) The Crown Rump Length (CRL)

The Crown-rump length is the shortest distance between the extremities of the embryo - normally between the crown (head) and rump (buttocks) excluding limbs and yolk sac. This is the most accurate sonographic technique to establish gestational age¹¹. In the absence of a normogram, a convenient formula can be adopted :

$$\text{GA in weeks} = \text{CRL in cm} + 6$$

CRL should not be applied after 12 weeks.

(Fig. 2).

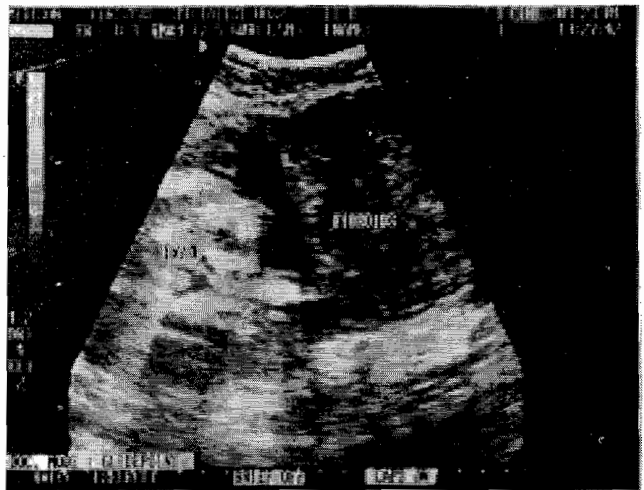


Fig. 2
Sagittal section at 11 weeks demonstrating fetal pole with differentiation of the fetal cranium and abdomen. The crown-rump length (CRL) is 36mm.

(3) Biparietal Diameter (BPD)

Getting the accurate plane is very important in determination of the BPD. This plane should include the cavum septum pellucidum, thalamus, and the middle cerebral artery pulsating in the insula¹²

The callipers are placed from the outer border of the proximal skull to the inner border of the distal skull. (Fig. 3)

(4) Occipitofrontal diameter (OFD)

This is the anteroposterior diameter of the fetal skull, the line perpendicular to the biparietal (BPD).⁶

(5) Head Circumference (HC)

Head circumference (HC) is less affected by head compression. This fact enables the head circumference to be a veritable tool in the

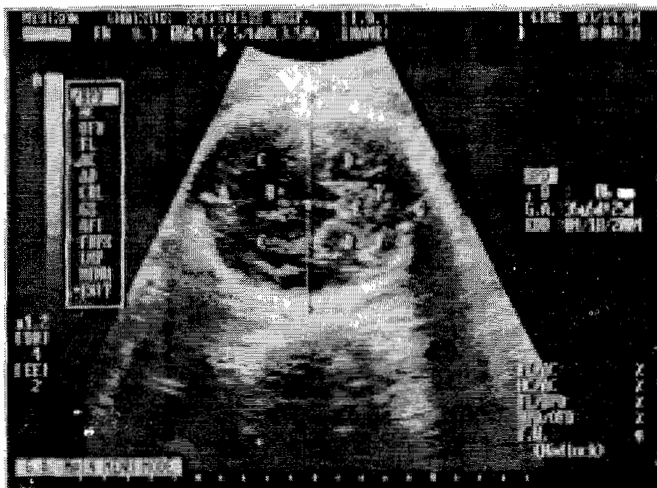


Fig. 3
Anatomical depiction of the thalamic level in a 35 week fetus.

- A - Cavum Septum Pellucidum
- B - Third Ventricle
- C - Thalamus
- D - Choroid Plexus
- E - Ambient Cisterna
- F - cerebellar Peduncles
- G - Occiput
- BPD = 86mm GA = 35 weeks 5 days.

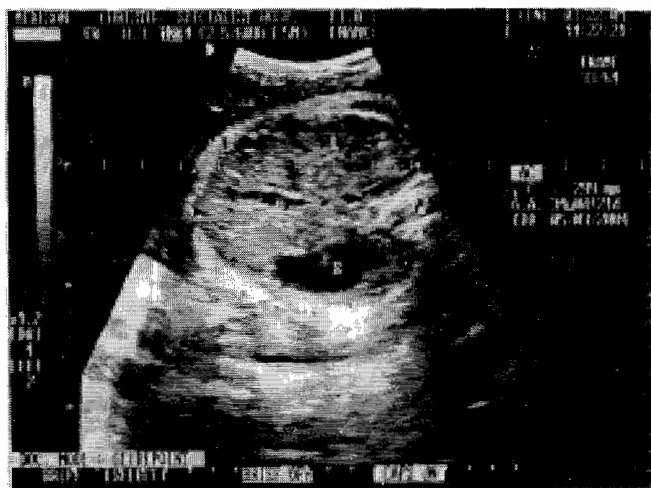

Fig. 4
Transverse section through the fetal abdomen at the level of the stomach and umbilical vein as it branches into the left portal sinus.

- S - Stomach
- V - Left Portal Vein
- L - Liver
- P - Spinal Cord
- M - Abdominal Wall Musculature
- AC = 299mm GA 34 weeks

assessments of gestational age. Head circumference can be calculated by the formula :

$$HC = \frac{D_1 + D_2}{2} = \frac{D_1}{OFD} = \frac{BPD}{PI}$$

(6) *Abdominal diameter (AD)*

The fetal abdomen is measured at the level where the umbilical vein branches into the left portal sinus. The stomach bubble can be seen at this level, and part of the liver tissue of the fetus. (Fig. 4)

(7) *Abdominal Circumference (AC)*

The following formula can be used to calculate the AC -

$$AC = \frac{D_1 + D_2}{2}$$

- D_1 = Diameter from fetal spine to anterior abdominal wall
- D_2 = Transversediameter perpendicular to D_1

Modern machines regularly trace the circumference and the perimeter is displayed. (Fig.4)

7
(8) *Femur Length*

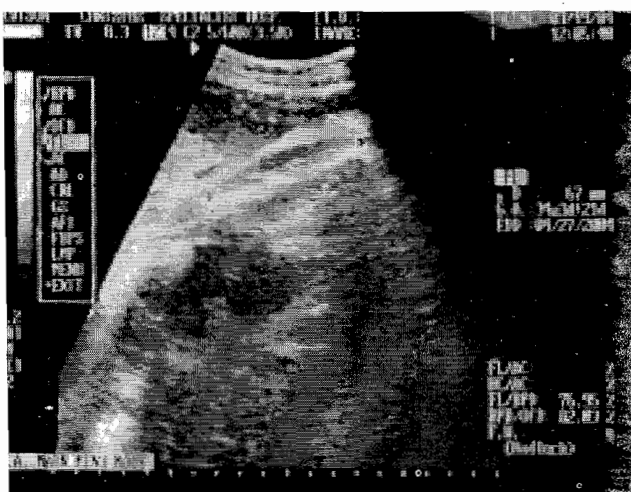


Fig. 5
Longitudinal section of the femur demonstrating a correct measurement (between crosses). The Femoral head is not included FL = 67mm, GA 34 weeks 3 days.

This is a particularly useful biometric parameter especially at the third trimester when the BPD may be affected by moulding growth retardation and congenital abnormalities. The femur is measured from the greater trochanter to the external condyle. Femoral head is not included. (Fig.5)

(9) Orbits

The ocular distance (OD) measure the single fetal orbit, the binocular distance includes both fetal orbits whereas the interocular diameter measures the distance between the two orbits ¹².

(10) Placental Abnormalities

Placental abruptions are of two different types, dissecting and the concealed types. Placenta praevia, although also associated with bleeding, usually is painless. Placenta praevia may be partial, marginal or complete. The texture of the

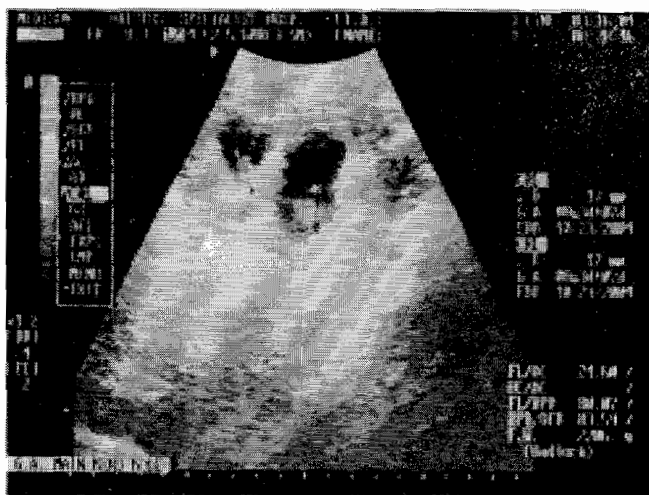


Fig. 6
Twin Pregnancy - Fetal Pole identified in each gestational sac. CRL - 17mm, GA 8 weeks 3 days.

placenta can also be used to determine its age and maturity.

Results and Commentaries

Within the last 15 years, roughly 390,000 routine scans have been done at Christus Specialists' hospital. All the measurements and observations are condensed in a format, tabulated, and the relevant ratios calculated. Appendix 1. The mode of presentation has already been published in my latest book on ultrasound ¹³.

8

By combining multiple parameters, i.e BPD, HC, AC, and FL, many cases of intrauterine growth retardation were diagnosed. It has been discovered clearly that in 95% of the cases, date given by the patients were not reliable. After sometime, it became obvious that many of the women just gave any date without any inkling of whether the date was correct or not. It is therefore imperative that in this society, a routine scan for gestational dating is necessary if the pregnancy is to be properly and accurately monitored.

Fetal weights were determined by Shepard equation ¹⁴ and babies diagnosed to have intrauterine growth retardation (IUGR) were directed to have serial sonograms.

There is strong association between oligohydramnios and IUGR. It has been postulated that the mechanism leading to oligohydramnios in gestations with IUGR is due to uteroplacental insufficiency with fetal hypoxia, and this results in diminished renal plasma flow. Oligohydramnios is found to be closely associated with IUGR and congenital abnormality.

Placental grading using the system of Granium and associates¹⁵ was found very useful. Grade III placenta associated with BPD of 86mm or less suggested a patient at increased risk of IUGR, and this predisposes to pre-eclampsia, particularly in primigravid patients.

Birth Weight more than 4000gm is classically described as macrosomia. A macrosomic fetus has greater incidence of morbidity or mortality and so if pelvic assessment shows inadequate or borderline pelvis, abdominal delivery is advocated.

9

During the first trimester, visualising more than one gestational sac within the uterus is diagnostic of multiple pregnancy. Confirmation is only made when a fetal pole is identified within each gestational sac. Locating the membrane that separates the sac could be the first observation leading to the diagnosis (Fig. 6).

Ultrasound has been immensely useful in monitoring cases of Isoimmunisation. In examining a fetus for hydrops there may be signs of fetal scalp oedema, ascites, pleural and pericardial effusions. There is hyper-placentalis and polyhydramnios. Some patients suspected to have Isoimmunisation problem are sent promptly for blood confirmation, and are advised to have injection of Rhogam within 24 hours of delivery.

Pregnant diabetics with poor glucose control are associated with polyhydramnios. On the other hand, many hypertensive disorders are associated

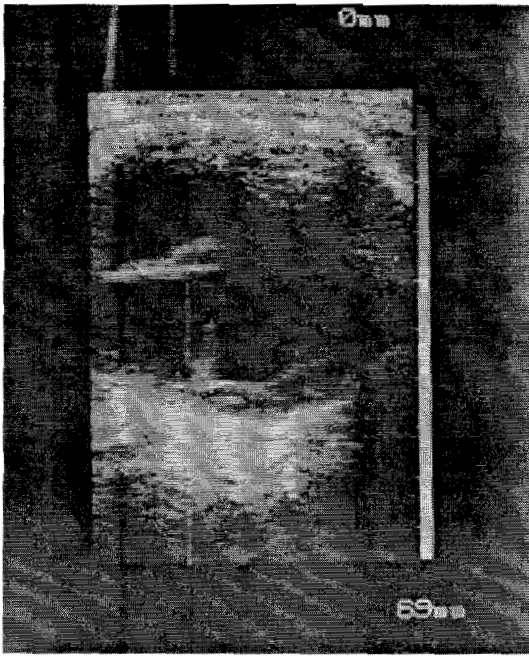


Fig. 7
Hydrocephalic ventriculomegaly. Note the fluid cavity is 69mm in diameter, and the cerebral mantle thinned out and compressed to the peripheral skull.

with oligohydramnios. If intrauterine fetal demise is imminent, obstetric intervention may be sought to effect immediate delivery.

Various congenital abnormalities have been diagnosed. These include ventriculomegaly (hydrocephalic) (Fig.7), microcephaly and hydranencephaly. Spinal bifida, sacrococcygeal teratoma, omphalocele and gastroschisis have also been diagnosed antenatally. Congenital

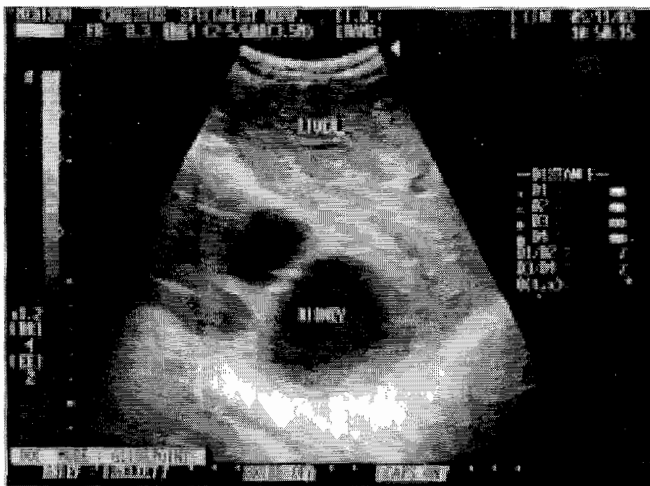


Fig. 8
Fetal liver and kidney showing congenital hydronephrosis. There was associated oligohydramnios.

hydronephrosis, hydroureters and fetal ascites have been diagnosed during the screening exercise. (Fig. 8)

Other congenital abnormalities that have been diagnosed include intestinal atresia, (Fig.9) congenital heart failure in hydrops (Fig. 10).

10

Placenta praevia (Fig. 11) and fibroids in pregnancy (Fig. 12) were readily diagnosed

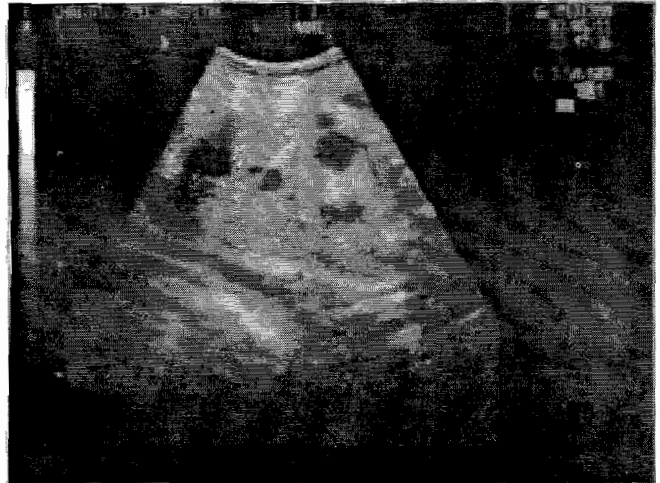

Fig. 9
Transverse section demonstrating dilated bowel loops typical of intestinal atresia.

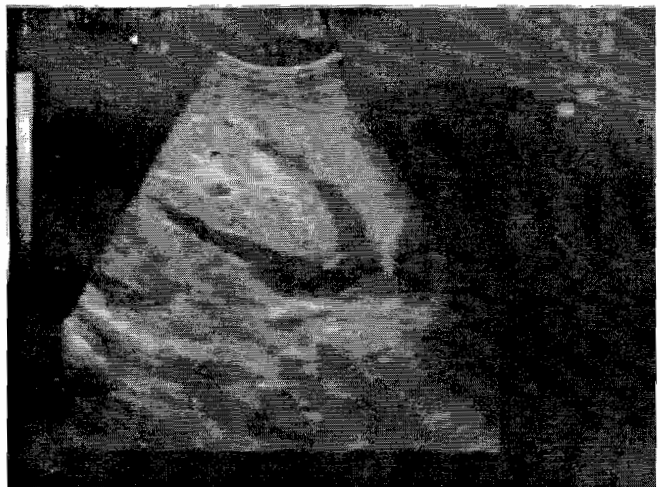


Fig. 10
Congenital Heart failure in hydrops showing grossly dilated hepatic veins. This is as a result of Rhesus isoimmunisation.

during the screening exercise.

11

Conclusion

For the past twenty years, efforts have been

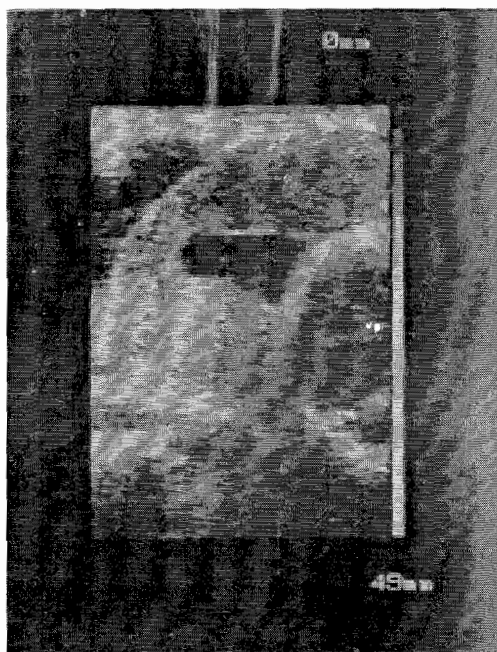


Fig. 11.

Placenta previa Type IV, Caesarean Section is the only solution.

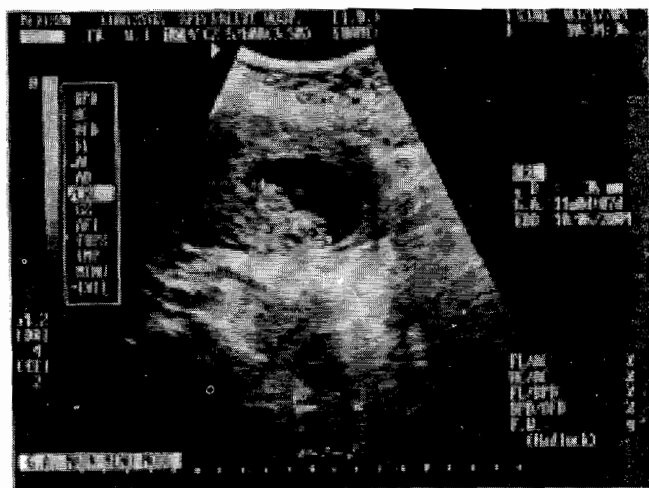


Fig. 12

Fibroids in pregnancy. The fibroid is hypoechoic compared with the myometrium. The fetal skull is hyperechoic.

made towards creating ultrasound awareness in all categories of health workers, particularly among the birth attendants in the faith homes and midwives in maternity centres. This allowed early diagnosis of pathological conditions such as abnormal lie or presentation, placental praevia and various types of congenital abnormalities. Patients were then directed to centres where proper scientific management could be instituted.

Unfortunately, the macabre scenario does not end there yet. Intrauterine surgery is not practicable in this environment yet. Ordinary Caesarean section may be too costly for the poverty stricken and down trodden patient who may not even be able to afford the taxi fare that will convey her to the nearest hospital.

It is apparently obvious that early diagnosis achieved by ultrasound awareness cannot yield ultimate result unless there are means of providing funds at this time of critical need. The National Health Insurance Scheme which has been proposed since 1962 in Nigeria, if implemented, hopefully will relieve some of the burden of health financing, and then Nigeria will be on the road towards reduction in Maternal Mortality Rate (MMR).

12

References

1. Curtin Sc., Recent changes in birth attendant, place of birth and the use of obstetric interventions in United States, 1989 - 1997. *J Nurse and Midwifery* 1999; 44 : 349 - 54.
2. Levi S.; Routine Ultrasound screening of congenital abnormalities. An overview of the European experience. *Ann. NY Acad Sci* 1998; 847 : 86 - 98
3. Royal College of Obstetricians and Gynaecologists. Ultrasound Screening for fetal abnormalities. Report of the RCOG working Party. London; Royal College of Obstetricians and Gynaecologists, 1997.
4. Bricker L, Garcia J, Henderson J; Mugford M. Ultrasound Screening in pregnancy: a systematic review of the clinical effectiveness, cost effectiveness and women's views. *Health Technol. Assess* 200; 4 : 1 - 193
5. Waldenstrom U, Axelsson O, Nilssons, Eklun G, Fall O, Lindeberg S, Sjodin T. Effects of routine one stage ultrasound screening in pregnancy - a randomised controlled trial. *Lancet* 1988; 2 : 585 - 8
6. Tsoi M, Hunter M. Ultrasound scanning in pregnancy: consumer reactions. *J. Reprod. Infant Psychol* 1987; 5 : 43 - 8

7. Flecher J. Evans M. Maternal bonding in early fetal ultrasound examination. N. Eng. J. Med. 1983; 308 : 392.
8. Harrington K, Armstrong V, Freeman J, Aquilina J, Campbell S. Fetal Sexing by ultrasound in the second trimester: Maternal preference and professional ability. Ultrasound Obstet Gynaecol 1996;8:318- 21. 13
9. Lawson J. B. and Stewart D. B. Obstetrics and Gynaecology in the Tropics and Developing Countries 1967 - Page 318.
10. Hohler Cw : Ultrasound Estimation of gestational age, Clin. Obstet. Gynaecol 27 : 2 1984.
11. Hobbins J.C, Winsberg f, and Birkowitz R; Ultrasonograohy in OB/GYN. Baltimore 1983, William & Wilkins Co.
12. Jeanty P and Romero R : Obstetrical Ultrasound, New York, 1984, MiGrain - Hill Book Co.
13. Obembe L . K, Ultrasound Guide to Obstetrics and Gynaecology in a Developing Economy. A Personal Experience in Private Practice. Page 9 - 11 Midmat Publications Ibadan. 2000.
14. Sheperd MJ, Richards VA Berkowitz RI, et al: An evaluation of two equation, AM J. Obstet Gynaecol. 142 : 47 1982.
15. Granum PA, Berkowitz RL, Hobbins JC The ultrasonic changes in the maturing placenta, AM J. Obstet Gynaecol 133 (8) : 915, 1979.

APPENDIX 1

CHRISTUS SPECIALISTS' HOSPITAL (NIG) LTD.
OLIVE HOUSE, OPPOSITE C.A.C. OKE-ANU, ADAMASINGBA, IBADAN
ULTRASOUND REPORT IN OBSTETRICS Tel: 02-2410052, 02-2413760



DATE 2 - 4 - 2004

NAME A-J
HOSPITAL/MATERNITY Apeto Health Centre
REFERRED BY _____

CLINICAL INFORMATION

AGE 25 PARITY 1 + 0 LAST CONFINEMENT 11/21r
LMP 19-8-03 GA 31 + 4 EDD 29-5-2004
(Weight's Rule)

FETAL PARAMETERS

LIE Longitudinal
PRESENTATION Cephalic
POSITION LOT
NO. OF GESTATIONS One
FETAL HEART BEAT Normal

SONOGRAPHIC MEASUREMENTS

GESTATIONAL SAC DIAMETER GSB
CROWN-RUMP LENGTH CRH
BIPARIETAL DIAMETER BPD 77mm
OCCIPITO-FRONTAL DIAMETER OFD 100mm
HEAD CIRCUMFERENCE HC 300mm
ABDOMINAL DIAMETER AD
ABDOMINAL CIRCUMFERENCE AC 265mm
FEMUR LENGTH FL 61mm



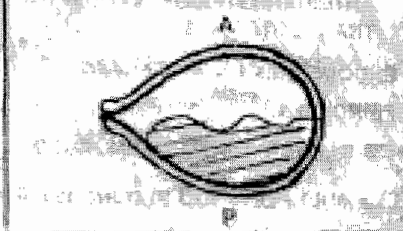
GESTATIONAL AGE GA 31wks 5days
EXPECTED DATE OF DELIVERY EDD 30-5-2004
ESTIMATED FETAL WEIGHT EFW 1713g
Shepard IAC, BPD METHOD

PLACENTA

LOCALISATION Posterior
PRAEVIA TYPE IB
MATURITY - GRADE I

RATIOS

FLIAC 73.65 % (AVG 20%)
FL/BPD 78.90 % (AVG 23% - 40%)
HCIAC 111.70 % (AVG 114% - 131%)
BPD/OFD 72.25 % (AVG 76% - 82%)
(Cephalic Index)



AMNIOTIC FLUID Normal
MAXIMUM LIQUOR DEPTH-MLD 45mm
AMNIOTIC FLUID INDEX (AFI) _____

COMMENTS

Fetal growth is symmetrical. There is good correlation between clinical and ultrasound gestational dating.

Points on date interpretation

- (1) EDD determined earlier in pregnancy is more accurate than later ones.
- (2) EFW has a wide range of normal after 24 weeks.
- (3) Placenta - Previa relates to location - Maturity relates to age and structure.
- (4) Thank for referring this patient. Should you have any further questions, please do not hesitate to call us on 02-2410052.
- (5) For repeat scan, please bring previous report.

[Handwritten signature]