

The Challenges of Vitreoretinal Surgery in Nigeria

Hassan A.O. FRCOphth, FRCS, FWACS
Okonkwo O.N. FRCSEd, DRCOphth

Dr. A.O. Hassan is the founder of Eye Foundation Retinal Institute, Ikeja, Lagos.

INTRODUCTION

THERE seems to be a growing awareness on ocular health amongst the average Nigerians. For one, some state governments now have eye projects where free eye screening and distribution of glasses are done. Lagos state is a good example of this. In some states free cataract surgery camps with implantation of intraocular lens (IOL) is undertaken.

In Nigeria, vitreoretinal surgery unlike Cataract Surgery and Glaucoma Surgery is not readily available. Often the type and extent of vitreoretinal pathology in a presenting patient may be entirely missed by the attending eye care provider. This may be so primarily because the ophthalmologist (in the case were the patient rightly presents to an ophthalmologist) may not have performed a proper fundus examination through a dilated pupil. Even when a dilated exam is attempted, skilled use of a Binocular Indirect Ophthalmoscope is not done.

The usefulness of the Binocular Indirect Ophthalmoscope can never be over emphasized. The Indirect Ophthalmoscope is essential to vitreo-retinal examination because of the stereopsis, wide field, and contrast obtained even with non optimal media. It should be used on its brightest setting (7.5v) in most instances. The + 20 D larger lenses are preferable because greater light - gathering ability increases contrast. If possible, the pupil should be widely dilated, the room dark, and the examiner well dark-adapted.

All Correspondence to Dr. A.O. Hassan

Eye Foundation Retinal Institute, Ikeja, Lagos,
Nigeria

HISTORICAL PERSPECTIVE

External Approach to Retinal Surgery:

Jules Gonin (1870-1935) is widely known as the father of retinal reattachment surgery (treatment for a detached retina). He was born in Lausanne, Switzerland, where he was also educated and pursued his brilliant career. He first treated retinal breaks with a red hot searing probe. Widespread interest was aroused when in 1929 at the International Congress of Ophthalmology in Amsterdam; he reported the surgical cure of 20 of 30 cases of retinal detachment that had existed for 3 weeks or less. He however, reported a cure of only 15 of 35 detachment persistent for more than 3 months.

To Gonin goes the credit not only for developing his operation, but also importantly for promoting and disseminating the new treatment through the publication of 34 papers in Belgian, German, British, American, Swiss and French journals. In each he emphasized the essential role of retinal breaks and the necessity of closing them with a searing method IGNIPUNCTURE.

Ophthalmologists from all over the world visited Lausanne, and Gonin's operation was first introduced across the Atlantic by Schoenbery, who preformed it in the United States in 1929.

In 1934 Gonin published his classic text, Retinal Detachment.

There is a lot to learn from this brief preview, if we are to adequately overcome some of the challenges facing us from the ophthalmologist's point of view.

Many other techniques have contributed to the development and improvement of Gonin's procedure. These include Diathermy technique in place of red-hot searing technique, intravitreal air for retinal break closure; scleral buckling

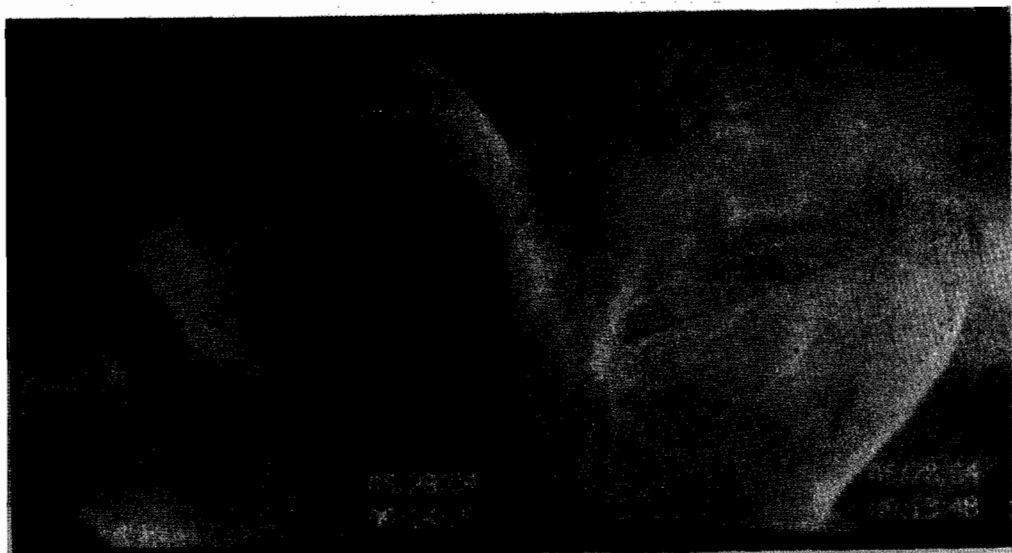


Fig. 1 Right: Horse shoe shaped retinal tear causing a rhegmatogenous retinal detachment.
Left: Infero-temporal retinal tear in the same eye of the patient.
Will require vitrectomy and silicon oil exchange.

introduced and developed by Custodis in 1949, photocoagulation and cryosurgery.

Internal Approach To Retinal Surgery

Robert Machemer is widely acclaimed as the father of vitrectomy procedure. He pioneered the development of the vitreous infusion suction cutter (VISC) in 1971. Today, vitreous surgery which was initially developed for the removal of vitreous opacities is now used to treat a host of Vitreoretinal pathology.

The development of retinal laser photocoagulation by Meyer – Schwickerath in 1956 has led to its use in the management of several retinal conditions.

This historical overview can not be complete without mention of Schepens work in modifying and developing the modern Binocular Indirect Ophthalmoscope in 1945. This has been augmented by the use of Scleral Indentation (Sclera “depression”) a technique with which the periphery of the retina can be brought more clearly into view and, more importantly, peripheral lesions can be viewed in dynamic profile as they are gently massaged by the scleral indenter.

From this brief overview we can see that vitreoretinal surgery has come a long way. Today a wide spectrum of conditions can be managed using Vitreoretinal surgical techniques. This may be for therapeutic or diagnostic purposes. Unfortunately, the situation in Nigeria does show that at the moment there may be no more than 1 or 2 eye centers where vitreoretinal surgery can be offered. This is a big challenge to the entire nation as a whole and the health sector in

particular.

The challenges of vitreoretinal surgery in Nigeria (i.e the challenges facing the advance of vitreoretinal surgery) can be examined from a perspective of 4 points of view.

- a. Ophthalmologist Perspective.
- b. Patients Perspective
- c. Hardware and infrastructure
- d. Recent Advances / New frontiers in Vitreoretinal surgery.

a. Ophthalmologist Perspective

Training: As illustrated in the above example the spread / dissemination of the art and technique was through the training of ophthalmologists who visited Gonin in Lausanne to learn the art. Gonin himself published his work extensively (in various languages), to be read by all and to benefit all. Vitreoretinal surgery has advanced greatly in leaps and bounds over the past years. This has been made possible only by the fruitful cooperation and healthy interaction of not only vitreoretinal surgeons , but also engineers who have fashioned microsurgical instrument used in this delicate surgery. It is important to note that several vitreoretinal surgeons in the developed nation have been awarded patents for work done in microsurgical instrument design and development.

The situation in Nigeria can be previewed by taking a thorough look at the training of the Ophthalmologist. Most residency programs within our borders pay no attention to the teaching of posterior segment examination techniques. Some resident doctors in the past

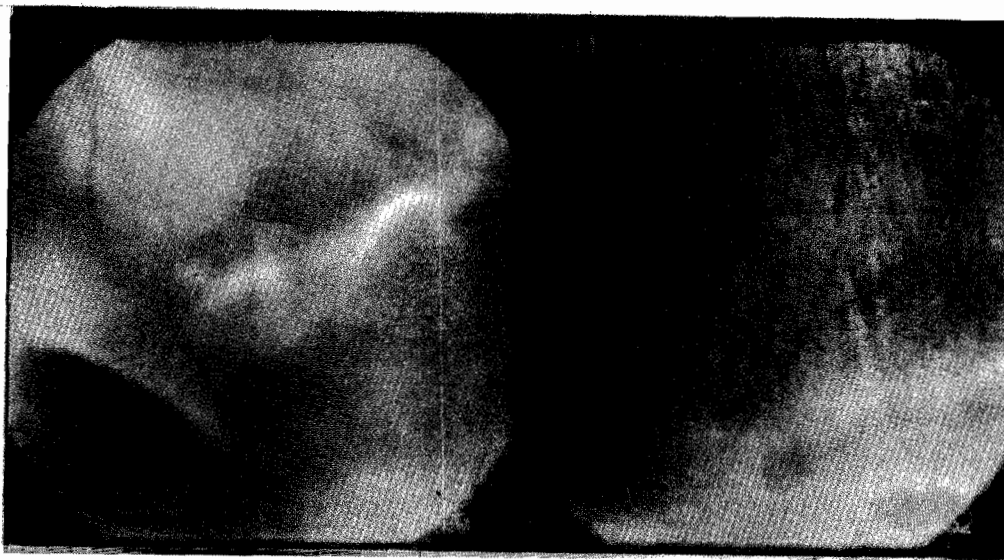


Fig. 2 *Right: Retinal detachment with an inferior retinal dialysis and proliferative vitreoretinopathy. Left: Other eye of the same patient shows a predisposing retinal degeneration in the form of pigmentary lattice. This can be treated prophylactically to prevent a detachment in this other eye.*

could qualify as eye specialists having no training in the use of Binocular Indirect Ophthalmoscope which is the most basic of retinal examination techniques, let alone having used a 3 Mirror contact lens (or any other biomicroscopic technique). The result is that such eye specialists will very often misdiagnose vitreoretinal conditions and therefore would not treat, counsel or make appropriate and timely referral.

As this group of ophthalmologists gets involved in training residents, ultimately the general lack of interest in proper retinal examination by these specialists is handed over to another generation of trainee eye doctors and the problem persists.

The only way forward will be to initiate a program in the 2 colleges (The National Postgraduate College and West African Postgraduate College) stimulating ophthalmic residents to develop the skills of Binocular Ophthalmoscopy during their residency training and not just a dress rehearsal of this technique in preparation for examination. This must be initiated early in the training program. But how can this possibly be done when several eye departments in our teaching hospitals can not boast of a functioning indirect ophthalmoscope. And, when this piece of equipment is available, it is often locked away and not used routinely in the clinics. Binocular Indirect Ophthalmoscopic examination with indentation surely is a must for every ophthalmologist irrespective of whether he or she has an inclination towards the vitreoretinal subspecialty.

We can not but note that though Robert Machemer is acclaimed as the father of the vitrectomy surgical technique which today

accounts for a huge percentage of Vitreoretinal work, this procedure has gone through countless modifications by many other surgeons. Indeed Machemer himself in his article 'Reminiscences after 25 years of Pars Plana Vitrectomy', published in the American Journal of Ophthalmology (AJO), talks about the fruitful cooperation between himself and colleagues. Much has to be said about this fruitful cooperation of vitreoretinal surgeons in the developed nations which has had a very positive effect of advancing the frontiers of Vitreoretinal surgery as a whole.

We deem that the biggest challenge of vitreoretinal surgery in Nigeria will be to create such a forum of Vitreoretinal surgeons. This can only be possible when more ophthalmologists take a keen interest in this field. The chances of this happening are higher when the trainee ophthalmologist has substantial exposure to Vitreoretinal examination techniques and pathology as a junior resident doctor.

This forum of Vitreoretinal surgeons can greatly advance the course of Vitreoretinal surgery in Nigeria. Examples of such a forum in other regions are the Association of Retinal specialists, Macular society, Vitreous society, Jules Gonin Club and Euretina (European Retina, Macular and Vitreous Society). These are all associations of Vitreoretinal surgeons in the developed world who together using their gifts of scientific knowledge and their common resources to promote the prevention, and treatment of vitreoretinal disorders.

As it is said, a tree cannot make a forest. Therefore the task of providing adequate Vitreoretinal service (i.e. qualitative service for all)

cannot be done by one or two vitreoretinal surgeons, but by close to as many vitreoretinal surgeons as we have cataract surgeons. This group of vitreoretinal surgeons can then give proper indigenous (national) statistics from population surveys on the incidence of the various vitreoretinal diseases. They will also evolve appropriate technology and technique best suited for our environment, to manage these Vitreoretinal disorders. Indeed as the worlds most populous black nation, we owe it to our world to inform them on our situation as regards Vitreoretinal pathology.

b. Patient Perspective:

The bulk of a Vitreoretinal specialist's work in Nigeria would include management of Retinal Detachments (and other rhegmatogenous retinal events), and Diabetic Retinopathy. In our environment many of the patients with this 2 conditions and other pathology will often present to the clinic later rather than sooner.

The reason for late presentation is often multifactorial ranging from a misdiagnosis by the optometrist (who would have been busy giving the patient a new set of glasses) or by the

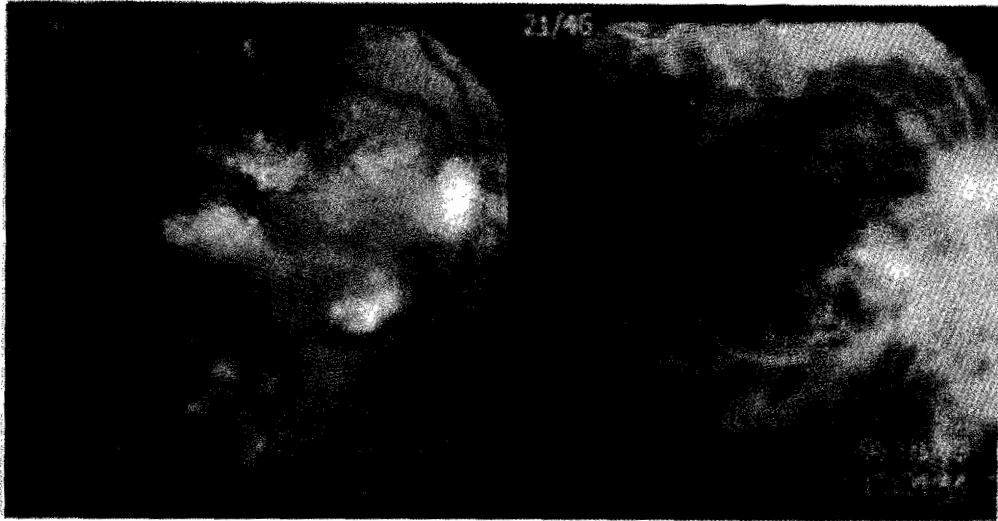


Fig. 3
Right: Shows hard exudates, cotton wool spots and vascular changes with retinal haemorrhage.
Left: Flourescein angiography of same eye showing areas of capillary drop, ischemic retinal changes, and leakage. This patient has a combined hypertensive and severe proliferative diabetic retinopathy. Will require aggressive laser photocoagulation.

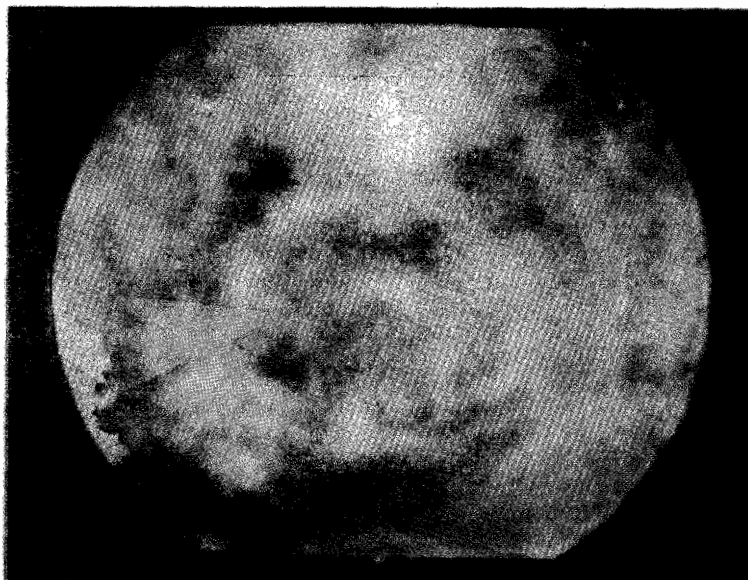

Fig. 4
Shows severe retinal haemorrhage (over the macula, retina, and disc).
A case of Central Retinal Vein occlusion. Some tortuousity of the veins can also be noted.

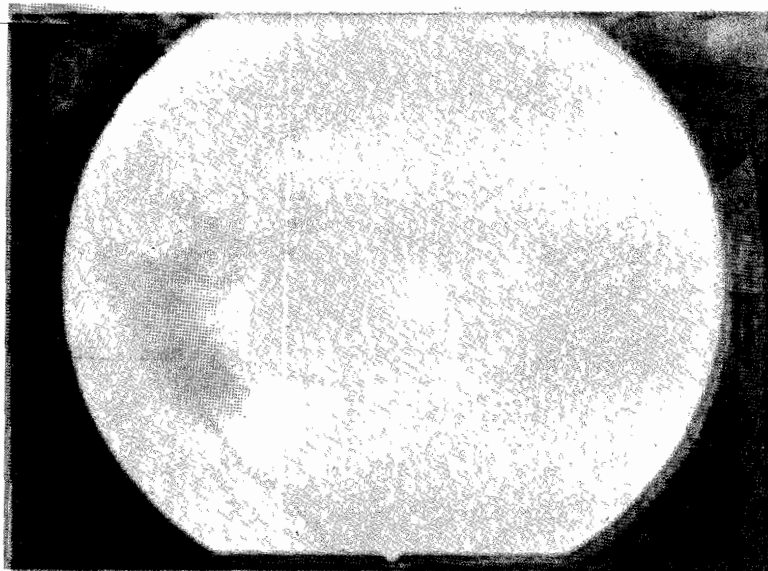


Fig. 5

This patient has a subretinal haemorrhage from a choroidal neovascular membrane involving the macula. This is a representation of Age Related Macular Degeneration (Wet variant). Also seen in Myopes, Ocular Histoplasmosis, and could be Idiopathic.

ophthalmologist (who has not bothered to do a thorough fundus examination through a dilated pupil) or by the patient him / her self who has been properly advised by the eye care provider, but prefers to use alternative remedies (eg. herbs) or is not financially enabled to seek adequate medical care.

The result is that the patient presents only when the vitreoretinal disease is very advanced. At this stage the prognosis for visual recovery is often poor and a more elaborate intervention is required. The patient will require to have more surgery rather than less (translating to more cost for him / her) yet he / she will not necessarily expect to have profound visual recovery. Timely visual stabilization at the entry (Pre operative) vision is what is hoped for.

If it is sometimes difficult for trainee ophthalmologist and even younger eye specialists to conceptualize the pathological changes occurring within the Vitreoretinal region, it is more often difficult for the patient to understand the happenings within his/her eye.

This even becomes more difficult when the patient's visual acuity is not yet significantly reduced. He or she does not understand why, for example, laser photocoagulation of the retina may be required, though the retinal shows presence of new vessels that could result in severe vitreous hemorrhage and will cause the loss of vision. This issue has been greatly helped by the availability of Fundus Imaging Cameras many of which are digitally operated. With this system, images of the retina can be taken (through a dilated pupil

and clear media) allowing and the patient can have a first hand insight into the Vitreoretinal pathology that lies behind.

c. Hard Ware and Infrastructure

The field of Ophthalmology in general is technology driven. While the developed world sets the pace with various microchip equipment, the developing world grapples to find its feet. India is an example of a nation that has blended the advancement of the modern world with its innovative ingenuity resulting in an eye care industry that caters for both the very poor and the very rich.

The field of Vitreoretinal surgery certainly enjoys several hi-tech equipment. For instance, the management of a case of advanced proliferative diabetic retinopathy with severe vitreous hemorrhage will require a 3 port pars plana vitrectomy with endo pan retinal photocoagulation. This will require the use of a vitrectomy machine and a laser machine, apart from an appropriate operating microscope for vitreoretinal use. The cost of all these will amount to several thousand US Dollars. A diabetic vitrectomy will require several accessories and adjunct devices some of which are essential for the management of intraoperative complications. These complications need to be properly managed if a good outcome is expected. Similarly, complex retinal detachments (with proliferative Vitreoretinopathy) will require a vitrectomy technique to reattach the retina.

During the procedure, perfluorochemical (Heavy Liquids) is a necessary adjunct, costing \$150-300.

Heavy Liquids are useful in repair of retinal detachments due to giant retinal tears, subretinal fluid drainage, foreign body removal, epiretinal membrane dissection and in floating of lens material.

State of the art vitrectomy machine (such as the Accurus system) offers better control throughout the period of surgery but will cost as much as \$ 70-80,000.

The Indians by their effort have greatly helped, offering cheaper, alternative technology which the rest of the developing world can borrow from.

The Ultrasound B scan is an invaluable diagnostic tool, which has greatly improved the management of the Opaque media patient (e.g. vitreous hemorrhage). It is best utilized in the hands of a vitreoretinal surgeon skilled in the interpretation of vitreoretinal anatomy in health and in pathological situation. The surgeon has the entire clinical picture in mind at time of ultrasonic examination, making possible better integration of the ultrasonic diagnosis into the thought process. Technicians should not be used for what should be thought of as acoustic ophthalmoscopy.

This piece of instrument is yet another expensive gadget to acquire for a good vitreoretinal practice.

While scleral buckling surgery remains a less expensive technique for the repair of rhegmatogenous retinal detachment, it is not suitable for a wide category of cases in which a detached retinal may be seen with large breaks

(e.g. giant retinal tears), posterior breaks or cases complicated with the development of proliferative vitreoretinopathy.

Vitrectomy technique though more expensive is able to achieve a flat (reattached) retinal in almost all cases.

Pars plana vitrectomy does require a steeper learning curve. It does demand a great deal of training and coordinating, not only for the surgeon, but for the rest of his team, the scrub nurse and assistant being key players also.

Its major advantage being that it offers a wider magnification enabling visualization of small retinal breaks that could have been missed.

d. Recent Advances / New Frontiers in Vitreoretinal Surgery

Like in the case of Gonin's Ignipuncture for the treatment of retinal detachment, a condition which before then had no known treatment, Machemer's vitrectomy heralded the beginning of a new frontier for the treatment of several posterior segment disorders which before then had no known treatment. The original aim being to remove vitreous opacities, vitrectomy has evolved into a technique used for the treatment of various types of retinal detachment, proliferative diabetic retinopathy, macular hole, macular translocation for the treatment of subretinal neovascular membranes, and sub retinal surgery also for the extraction of choroidal membranes.

Despite all these advances in the above

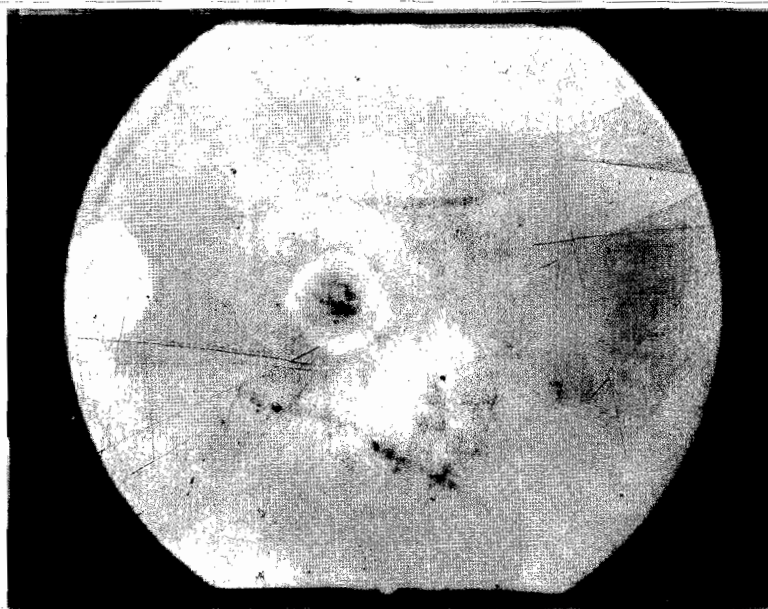


Fig. 6
Shows a full thickness defect involving the central fovea. A yellow ring surrounds this break. This is a Macular hole. A potent cause of loss of central vision. This defect can now be closed surgically.

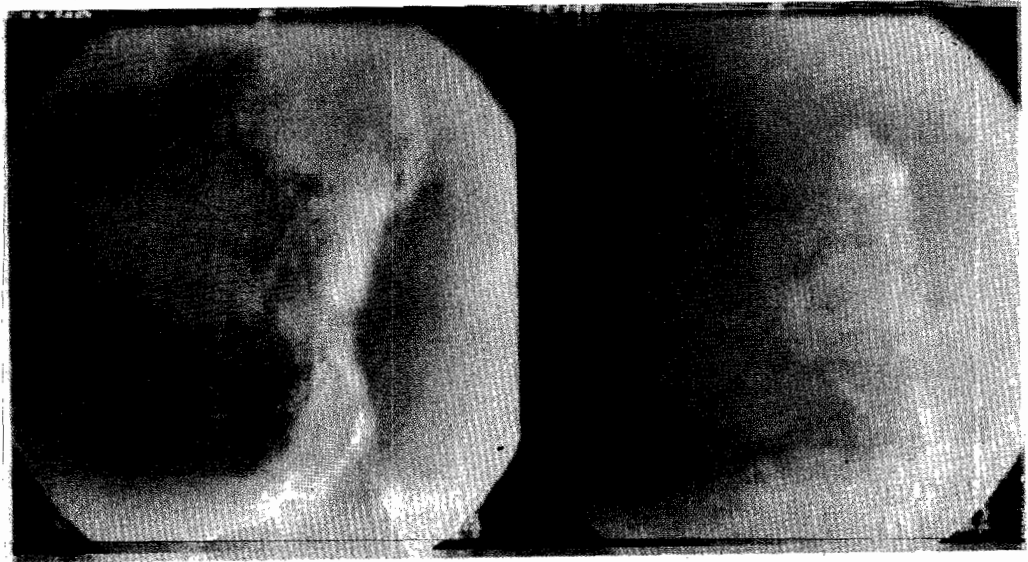

Fig. 7
Showing Seafan Retinopathy seen in Sickle cell patients. Can progress to vitreous haemorrhage and visual loss. Will require panretinal laser photocoagulation to cause regression.

technique, with their proven efficacy and benefit, here in Nigeria we still lag so far behind in the availability of these extremely valuable microsurgical skills. Our patients certainly deserve to be offered these newer modalities of treatment.

We fail them when we can not provide these techniques. This is a major collective challenge. These skills can only be transferred to ophthalmologists who commit themselves to the patient and to humbling, rewarding process of painstaking tutelage. A great respect for details and discipline must be shown. Above all there must be a strong aspiration to greatly refine one's skills in order to have the satisfaction of having given the best to the patient. This is a challenge for the individual surgeon, or would be surgeon.

The challenges of vitreoretinal surgery development in Nigeria, put in a concise way are those which very much rest at the door post of the head of the eye care team- that is, the ophthalmologist. The Ophthalmologists in Nigeria must arise to promote the concept of sub specialization training and improve the quality of training given in the postgraduate colleges to reflect acquisition of skills for posterior segment examination.

Appropriate level of awareness amongst the populace is mandatory if we are to see patients presenting to our clinics sooner rather than later. For instance making patients who are diabetic aware of the risk of ocular involvement. It is a shame how many patients present with advanced diabetic eye disease and have been visiting

physicians for control of their diabetic state, but yet have never been informed of the possibility of eye involvement and need for retinal examination. A proper diagnosis of these vitreoretinal conditions is necessary for a quick and appropriate referral. This applies to all subspecialties of ophthalmology.

We must be innovative and ready to first use our resources in the development of the entire ophthalmic community and ourselves in general before soliciting for outside help.

Like Gonin and Machemer who both faced up to the challenges of their time and overcame them, we in like manner must do the same with our own challenges with as much vigour and challenges. To shrink back from this responsibility is to await the harsh and severe judgment of posterity.

References

1. Hilton, G .F; McLean, J .B; Brinton, D .A Retinal Detachment Principles and Practice, 2nd Ed American Academy of Ophthalmology, Monograph 1
2. Steve Charles, Adam Katz, Byron Wood Vitreous Microsurgery 3 rd Edition
3. Machemer Robert *Reminiscence After 25 years of Pars Plana Vitrectomy.* • Am J Ophthalmol 1995 Apr; 119(4): 505-10