

## AQUAPORIN-4 (AQP-4) IMMUNOGLOBULIN G SEROPOSITIVE NEUROMYELITIS OPTICA: A REVIEW AND CASE REPORT

C. Nwaze, Y. Eghwrudjakpor, N. Chinedu-Anunaso

Regions Stroke and Neuroscience Hospital, Owerri, Imo State, Nigeria.

*Correspondence:*

**Dr. C. Nwaze**

Regions Stroke and Neuroscience Hospital,  
Imo State.

Email: chukwumanwaze@gmail.com

*Submission Date: 6th March, 2023*

*Date of Acceptance: 30th Dec., 2023*

*Publication Date: 30th Jan., 2024*

### ABSTRACT

**Background:** Neuromyelitis optica spectrum disorder (NMOSD) is a relatively new terminology composed to encompass patients with neuromyelitis optica (NMO) and related immunological conditions. The diagnosis of this condition requires a seropositive aquaporin-4 immunoglobulin G (AQP-4 IgG), the presence of at least one core clinical characteristic and the exclusion of alternative diagnoses. Very few cases have been reported in sub-Saharan Africa.

**Objective:** The aim of this article is to report a classical case of NMOSD with AQP-4 IgG seropositivity and normal brain, cervical and thoracic MRI findings.

**Result:** We report a 25-year-old Nigerian woman who presented with recurrent and alternating weakness, pain and numbness of all limbs, associated with episodic painful left-sided tonic spasms and urinary incontinence. She had earlier had symptoms of recurrent, episodic and alternating loss of vision in both eyes, associated with ocular pain.

Examination findings revealed an intact mental status, no cranial nerve deficit and no focal limb weakness. Right-sided deep tendon reflexes were exaggerated. Vital signs were within normal limits. Brain MRI, Cervical spine MRI and Thoracic spine MRI all revealed normal findings. Serum aquaporin-4 IgG assay returned positive with a titer of 1:32.

She was commenced on high dose steroids and there was gradual improvement of symptoms.

**Conclusion:** These findings confirmed the diagnosis of neuromyelitis optica spectrum disorder, and satisfies the diagnostic criteria published in 2015 by the International Panel for NMO Diagnosis (IPND).

**Keywords:** Aquaporin, Neuromyelitis optica, Immunoglobulin

### INTRODUCTION

Neuromyelitis Optica (NMO) is a rare, idiopathic, inflammatory and severe demyelinating disease of the central nervous system, primarily affecting the spinal cord and optic nerves.<sup>1,2</sup> First described in 1894 by Devic<sup>3</sup>, it is characterized by simultaneous or sequential loss of vision, associated with ocular pain, alongside spinal symptoms including symmetric paraplegia, sensory loss below the lesion and incontinence. These symptoms can occur in monophasic or relapsing courses.<sup>2,4</sup>

Following the ground-breaking discovery of the relationship between neuromyelitis optica<sup>5</sup> and the antibody AQP4-IgG a water channel protein, expressed in foot processes of astrocytes of the brain, spinal cord and optic nerve<sup>6</sup>, and other studies supporting this discovery<sup>7-10</sup>, AQP4-IgG was incorporated in the diagnostic criteria.<sup>11</sup> This was

further modified with a new terminology known as Neuromyelitis Optica Spectrum Disorders (NMOSD) to encompass NMO and other CNS lesions which have similar immunopathogenesis and clinical behavior as NMO, and those which may possibly fulfil the NMO criteria in future.<sup>2,11</sup> The diagnostic criteria includes seropositive and seronegative divisions, with the seropositive division needing only one of six core clinical characteristics and the seronegative division requiring more stringent clinical features for diagnosis.<sup>1</sup> It is important to note that although NMOSD was formerly thought to be a severe variant of multiple sclerosis, recent clinical, immunopathogenic and radiological findings have proven that it is indeed a different entity.<sup>5,10,12</sup>

NMOSD has been widely reported in developed countries. However, cases on the African continent have

been quite limited. Some systematic reviews do not include any studies from Africa.<sup>13</sup> There may also be significant under-reporting of available cases partly due to the limited access to MRI, AQP4-IgG testing, and other tests required for appropriate diagnosis.<sup>14</sup> Majority of cases reports in Africa originate from North Africa<sup>15-17</sup>, with a few from Sub-Saharan Africa.<sup>18-20</sup> However, to the best of our knowledge, only one NMO AQP-IgG seropositive case has been reported in Nigeria.<sup>21</sup> In this article, we report a young Nigerian lady with a classical presentation of neuromyelitis optica.

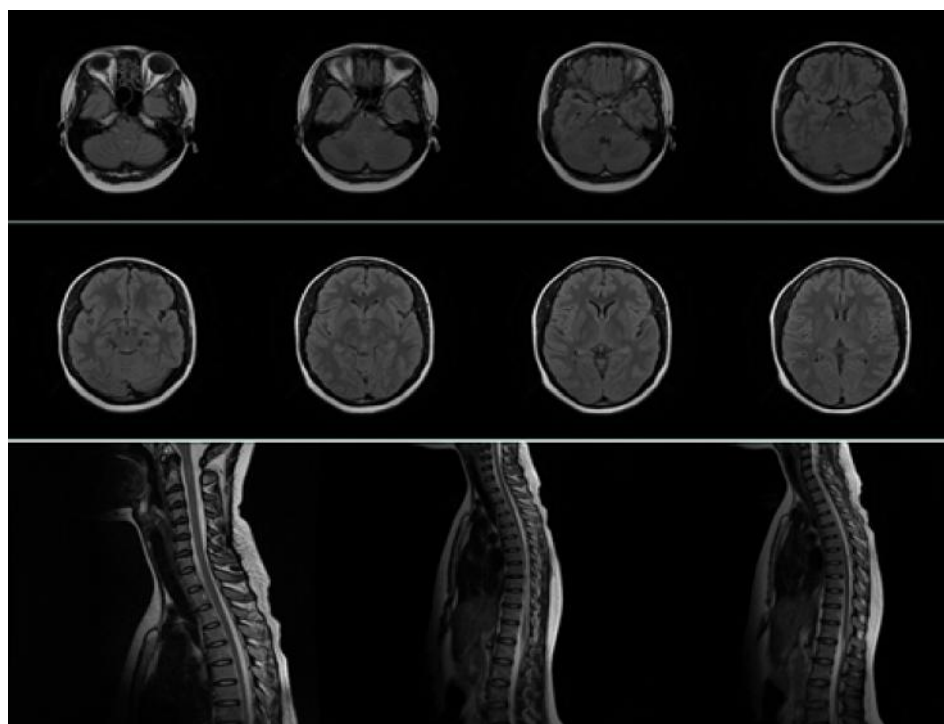
### CASE PROFILE

A 25-year-old right-handed Nigerian lady presented to our clinic for a second opinion concerning a history of recurrent neurological symptoms. As at presentation, she complained of blurry vision in her right eye – just recovering from the latest episode of visual loss. She also complained of generalized body weakness, and pains. Six years prior to presentation, she developed loss of vision in her left eye with associated pain on movement of the eyeball. There was no redness. She visited an ophthalmologist where she received eye drops and vision improved over the next three weeks. She had a similar occurrence two years later with sudden loss of vision in the opposite eye. She then had two recurrences three years later and most recently a week before presentation. These episodes occurred in one eye at a time. Vision in right eye was still recovering at presentation. She also had an episode of hearing loss five years ago (could not

remember which ear) for which symptoms resolved after taking some ear drops following an otorhinolaryngology consultation. In addition, she had an episode of numbness, pain and sudden weakness of the right side of her body two years prior to presentation. She visited a tertiary hospital and was diagnosed of Multiple Sclerosis and was treated with high dose intravenous methylprednisolone which relieved her symptoms. She thereafter had three relapses within a period of two years – either left sided numbness with pain or left sided weakness. Her left sided pain was usually associated with painful tonic spasms with accompanying tonic posture of the upper and lower limbs. There is history of urinary incontinence, but no history of fecal incontinence. No headaches, no loss of consciousness. No history of cough, or difficulty breathing and no history of palpitation.

Examination revealed normal tone in all limbs and muscle power of grade 4 in all muscle groups. Reflexes were exaggerated in the left upper and lower limbs and normal on the right upper and lower limbs, and she had no ankle clonus. There was flexor plantar response on both feet. There was no ataxia or tremor. Her gait was slow, but not wide based or ataxic.

Brain, cervical spine, and thoracic spine MRI revealed normal findings (Figure 1). AQP4-IgG test using immunofluorescence assay titers was positive with a titer of 1:32.



**Figure 1:** T2 FLAIR MRI images showing normal findings in the brain, cervical and thoracic spine.

## DISCUSSION

The incidence and prevalence of NMO have been reported in the range of 0.053-0.73 per 100,000<sup>22-25</sup> and 0.5-10 per 100,000<sup>22,24-28</sup> respectively. Most studies have reported the prevalence of AQP4-IgG seropositive cases between 62% and 100%.<sup>24,25,27</sup> Although scarce, the incidence and prevalence were reportedly highest among those of African descent and lowest among Caucasians.<sup>24,28</sup> Osuntokun reported an incidence of 0.0043/100,000 hospital population in Nigeria,<sup>29</sup> while 16 patients were reported over a course of 7 years in a neurological center in Senegal.<sup>18</sup> Despite these, there is significant underreporting in Africa.

A systematic review and meta-analysis of cases globally revealed a peak incidence between 40-59 years.<sup>30</sup> Studies in the United States report a mean age of onset of 41.1 years while age of onset ranged from 14 to 55 years in Brazilian studies<sup>31</sup>. Neuromyelitis optica has also been repeatedly linked to people of African descent, as seen in our patient. Although this may suggest an underlying genetic susceptibility, the reasons are largely unknown.<sup>24,28,30</sup>

Our index case, a female is not unexpected as the condition is widely known for female preponderance.<sup>22,26,28</sup> However, the age of onset falls at the lower end of the spectrum reported in most prevalence studies, as symptoms reportedly started at the age of 19 years.

The diagnosis of NMOSD as outlined in the new criteria requires one of six core clinical criteria in the presence of AQP-4 IgG seropositivity and a more stringent criteria when AQP-4 IgG is seronegative. These six core clinical criteria represent six anatomical brain regions which have been implicated in literature to be associated with AQP-4 IgG seropositivity. They include the optic nerve, spinal cord, area postrema of the dorsal medulla, brain stem, diencephalon or cerebrum.<sup>1</sup>

Optic neuritis which is suggestive of NMOSD is characterized by loss of vision, which is simultaneously bilateral, involving the optic chiasma, causing an altitudinal visual field defect or severe residual visual loss.<sup>1</sup> Our index patient, however, presented with sequential rather than simultaneous loss of vision. The paroxysmal painful tonic spasms seen in our patient is characteristic of that seen in classical cases of neuromyelitis optica.<sup>1,4</sup> Other core symptoms of neuromyelitis optica spectrum disorders – Area postrema syndrome, acute brainstem syndrome, acute diencephalic clinical syndrome or symptomatic cerebral syndrome<sup>1</sup> were not observed in our patient. Hearing

loss as seen in this patient may be a brainstem or cochlear lesion of neuromyelitis optica, and has been reported in some patients.<sup>32-34</sup>

AQP-4 IgG serology has become the backbone of NMO diagnosis and distinguishes other NMO-like neurological conditions from NMO. This is particularly important in the case of multiple sclerosis (MS) as some conventional medications used in MS (for example interferon-beta) can worsen, and are now contraindicated in NMO.<sup>35,36</sup> As a result of these discoveries, there has been advancement in technology to increase diagnostic accuracy of AQP-4 IgG. Cell-based serum assays has been shown to have a much higher diagnostic accuracy compared to Indirect Immunofluorescence assay and ELISA.<sup>37,38</sup> However, it is not yet widely available.<sup>1</sup>

In the event of a seronegative AQP-4 IgG, or unavailability of AQP-4 IgG testing, a more stringent criteria is applied in the diagnosis of NMOSD. This includes at least two core clinical criteria of which one must be optic neuritis, acute myelitis with longitudinally extending transverse myelitis, or acute postrema syndrome.<sup>1</sup> However, recent studies<sup>39-41</sup> have found that most AQP-4 IgG seronegative patients with clinical and neuro-imaging findings of NMOSD have detectable levels of serum myelin oligodendrocyte glycoprotein (MOG), a myelin protein present at the outermost surface of oligodendrocyte membranes and myelin sheaths.<sup>42</sup> This may indicate a different immunopathogenesis of NMOSD in AQP-4 IgG seronegative patients.<sup>43</sup> This finding is however yet to be thoroughly explored, as well as other possible biomarkers for NMOSD.

Other markers for NMOSD are also considered as supportive criteria in its diagnosis. CSF pleocytosis >50 leukocytes/ $\mu$ L or the presence of neutrophils or eosinophils as well as absence of oligoclonal bands could differentiate NMOSD from MS.<sup>44</sup> CSF glial fibrillary acidic protein may also be useful as a prognostic marker of NMOSD in future.<sup>1</sup>

Neuroimaging findings of NMOSD largely correspond to the diagnostic core clinical characteristics. T2-weighted or Gadolinium-enhanced T1-weighted magnetic resonance imaging would adequately show the lesions. Lesions involving the optic nerve, dorsal medulla, thalamic area or peri-ependymal surfaces of the third and fourth ventricles are characteristic of neuromyelitis optica. However, detection of increased signal extending over three or more vertebral segments (longitudinally extensive transverse myelitic lesions) with central cord predominance is the most specific

neuroimaging feature of neuromyelitis optica, which is uncommon in multiple sclerosis.<sup>1,11</sup>

Once the diagnosis of NMOSD is made, treatment of acute attacks and prevention of subsequent relapse is paramount, as recurring relapses contribute significantly to morbidity. Treatment with a short course of high dose corticosteroids, usually intravenous methylprednisolone at a dose of 1g/day for 3 to 5 days is the mainstay of treatment. This is usually followed by a one-month course of oral corticosteroid, usually prednisolone at 1mg/kg body weight, which is gradual tapered off over a six-month period.<sup>45,46</sup>

Patients with failure to respond to a short course of high dose corticosteroids would benefit from plasmapheresis or plasma exchange (PLEX).<sup>47</sup> PLEX is traditionally commenced the week after non-response to high dose corticosteroids. A retrospective study revealed an advantage with commencing PLEX alongside high dose corticosteroids.<sup>48</sup> PLEX is specifically administered every other day for a two-week period, culminating to a total of 5-7 doses.<sup>45,46</sup>

Maintenance therapy to prevent subsequent relapses should be aggressively pursued with immunosuppressive therapies like intravenous rituximab, and oral mycophenolate mofetil, oral azathioprine, oral methotrexate and a host of others. It is challenging to ascertain the superiority of any of these drugs over another as controlled trials have been difficult to conduct, given the rarity and morbidity associated with this condition.<sup>45,46</sup> Monoclonal antibodies, like satralizumab and eculizumab, were recently shown to have significant effect in long-term prevention of relapse among patients with NMOSD.<sup>49,50</sup> Novel drugs are being developed for managing NMOSD. Recent trials have shown that the use of monoclonal antibodies like IL-6 receptor antagonist (Tocilizumab) led to a significantly longer time to relapse and lower cases of relapse when compared with Azathioprine.<sup>51</sup> Newer agents such as the anti-CD19 (Inebilizumab) and anti-CD20 (Ublituximab) drugs are currently undergoing clinical trials.<sup>52,53</sup>

## CONCLUSION

Neuromyelitis optica is a rare condition, and a challenge to diagnose in our environment. Still poorly understood, it has been the subject of much debate. However, once diagnosed, prompt and aggressive therapy is needed. This condition, if not managed optimally, may cause serious morbidity and disability to the patient. There is, however, still on-going research to discover best medications for neuromyelitis optica.

## REFERENCES

1. **Wingerchuk DM**, Banwell B, Bennett JL, *et al*. International consensus diagnostic criteria for neuromyelitis optica spectrum disorders. *Neurology*. 2015 Jul 14;85(2):177–189.
2. **Wingerchuk DM**, Lennon VA, Lucchinetti CF, *et al*. The spectrum of neuromyelitis optica. *Lancet Neurol* [Internet]. 2007;6(9):805–15. Available from: <https://www.sciencedirect.com/science/article/pii/S1474442207702168>
3. **Devic E**. Myélite subaiguë compliquée de névrite optique. *Bull Med*. 1894;8:1033.
4. **Wingerchuk DM**, Hogancamp WF, O'Brien PC, Weinschenker BG. The clinical course of neuromyelitis optica (Devic's syndrome). *Neurology*. 1999;53(5):1107.
5. **Lennon VA**, Wingerchuk DM, Kryzer TJ, *et al*. A serum autoantibody marker of neuromyelitis optica: distinction from multiple sclerosis. *Lancet*. 2004;364(9451):2106–2112.
6. **Verkman AS**. Aquaporins in clinical medicine. *Annu Rev Med*. 2012;63:303–316.
7. **Zuliani L**, Lopez de Munain A, Olascoaga J, *et al*. NMO-IgG antibodies in neuromyelitis optica: a report of 2 cases. *Neurologia*. 2006;21(6):314–317.
8. **Littleton ET**, Jacob A, Boggild M, Palace J. An audit of the diagnostic usefulness of the NMO-IgG assay for neuromyelitis optica. 2006;
9. **Jarius S**, Franciotta D, Bergamaschi R, *et al*. NMO-IgG in the diagnosis of neuromyelitis optica. *Neurology*. 2007;68(13):1076–1077.
10. **Saiz A**, Zuliani L, Blanco Y, *et al*. Revised diagnostic criteria for neuromyelitis optica (NMO). *J Neurol*. 2007; 254 (9):1233–1237.
11. **Wingerchuk DM**, Lennon VA, Pittock SJ, *et al*. Revised diagnostic criteria for neuromyelitis optica. *Neurology*. 2006;66(10):1485–1489.
12. **Lennon VA**, Kryzer TJ, Pittock SJ, *et al*. IgG marker of optic-spinal multiple sclerosis binds to the aquaporin-4 water channel. *J Exp Med*. 2005;202(4):473–477.
13. **Sokhi D**, Suleiman A, Manji S, *et al*. Cases of neuromyelitis optica spectrum disorder from the East Africa region, highlighting challenges in diagnostics and healthcare access. *Eneurologicalsci*. 2021;22:100320.
14. **Holroyd K**, Vogel A, Lynch K, *et al*. Neuromyelitis optica testing and treatment: Availability and affordability in 60 countries. *Mult Scler Relat Disord*. 2019;33:44–50.
15. **Salama S**, Marouf H, Reda MI, *et al*. Clinical and radiological characteristics of neuromyelitis optica spectrum disorder in the North Egyptian Nile Delta. *J Neuroimmunol*. 2018;324:22–25.

16. **Bennis A**, El Otmani H, Benkirane N, *et al.* Clinical course of neuromyelitis optica spectrum disorder in a moroccan cohort. *Mult Scler Relat Disord.* 2019;30:141–148.
17. **Daoudi S**, Bouzar M. Neuromyelitis optica spectrum disorders in Algeria: a preliminary study in the region of Tizi Ouzou. *Mult Scler Relat Disord.* 2016;6:37–40.
18. **Gaye NM**, Fall M, Diop AM, *et al.* Neuromyelitis optica spectrum disorders (NMO-SD) in a sub-Saharan Africa country: a preliminary study of sixteen Senegalese cases. *Mult Scler Relat Disord.* 2019;27:179–183.
19. **Assadeck H**, Daouda MT, Omar EA, *et al.* Inflammatory demyelinating diseases of the central nervous system in Niger. *Rev Neurol (Paris).* 2019;175(4):261–268.
20. **Esser M**, Bhigjee AI, Moodley AA, *et al.* The neuromyelitis optica presentation and the aquaporin-4 antibody in HIV-seropositive and seronegative patients in KwaZulu-Natal, South Africa. *South Afr J HIV Med.* 2017;18(1):1–7.
21. **Balarabe SA**, Adamu MD, Watila MM, Jiya N. Neuromyelitis optica and myasthenia gravis in a young Nigerian girl. *Case Reports.* 2015;2015: bcr2014207362.
22. **Cabrera-Gómez JA**, Kurtzke JF, González-Quevedo A, Lara-Rodríguez R. An epidemiological study of neuromyelitis optica in Cuba. *J Neurol.* 2009;256(1):35–44.
23. **Cabre P**, Gonzalez-Quevedo A, Lannuzel A, *et al.* Descriptive epidemiology of neuromyelitis optica in the Caribbean basin. *Rev Neurol (Paris).* 2009;165(8–9):676–683.
24. **Jacob A**, Panicker J, Lythgoe D, *et al.* The epidemiology of neuromyelitis optica amongst adults in the Merseyside county of United Kingdom. *J Neurol.* 2013;260(8):2134–2137.
25. **Asgari N**, Lillevang ST, Skejoe HPB, *et al.* A population-based study of neuromyelitis optica in Caucasians. *Neurology.* 2011;76(18):1589–1595.
26. **Etemadifar M**, Dashti M, Vosoughi R, *et al.* An epidemiological study of neuromyelitis optica in Isfahan. *Mult Scler J.* 2014;20(14):1920–1922.
27. **Houzen H**, Niino M, Hirotani M, *et al.* Increased prevalence, incidence, and female predominance of multiple sclerosis in northern Japan. *J Neurol Sci.* 2012;323(1–2):117–122.
28. **Flanagan EP**, Cabre P, Weinshenker BG, *et al.* Epidemiology of aquaporin 4 autoimmunity and neuromyelitis optica spectrum. *Ann Neurol.* 2016;79(5):775–783.
29. **Osuntokun BO**. The pattern of neurological illness in tropical Africa: experience at Ibadan, Nigeria. *J Neurol Sci.* 1971;12(4):417–442.
30. **Papp V**, Magyari M, Aktas O, *et al.* Worldwide incidence and prevalence of neuromyelitis optica: a systematic review. *Neurology.* 2021;96(2):59–77.
31. **Mealy MA**, Wingerchuk DM, Greenberg BM, Levy M. Epidemiology of Neuromyelitis Optica in the United States: A Multicenter Analysis. *Arch Neurol [Internet].* 2012 Sep 1;69(9):1176–80. Available from: <https://doi.org/10.1001/archneurol.2012.314>
32. **Kremer L**, Mealy M, Jacob A, *et al.* Brainstem manifestations in neuromyelitis optica: a multicenter study of 258 patients. *Mult Scler J.* 2014;20(7):843–847.
33. **Gratton S**, Amjad F, Ghavami F, *et al.* Bilateral hearing loss as a manifestation of neuromyelitis optica. *Neurology.* 2014;82(23):2145–2146.
34. **Tugizova M**, Feng H, Tomczak A, *et al.* Case series: Hearing loss in neuromyelitis optica spectrum disorders. *Mult Scler Relat Disord.* 2020;41:102032.
35. **Warabi Y**, Matsumoto Y, Hayashi H. Interferon beta-1b exacerbates multiple sclerosis with severe optic nerve and spinal cord demyelination. *J Neurol Sci.* 2007;252(1):57–61.
36. **Palace J**, Leite MI, Nairne A, Vincent A. Interferon Beta treatment in neuromyelitis optica: increase in relapses and aquaporin 4 antibody titers. *Arch Neurol.* 2010;67(8):1016–1017.
37. **Waters PJ**, McKeon A, Leite MI, *et al.* Serologic diagnosis of NMO: a multicenter comparison of aquaporin-4-IgG assays. *Neurology.* 2012;78(9):665–671.
38. **Waters PJ**, Pittock SJ, Bennett JL, Jarius S, Weinshenker BG, Wingerchuk DM. Evaluation of aquaporin 4 antibody assays. *Clin Exp Neuroimmunol.* 2014;5(3):290–303.
39. **Kitley J**, Woodhall M, Waters P, *et al.* Myelin-oligodendrocyte glycoprotein antibodies in adults with a neuromyelitis optica phenotype. *Neurology.* 2012;79(12):1273–1277.
40. **Kitley J**, Waters P, Woodhall M, *et al.* Neuromyelitis optica spectrum disorders with aquaporin-4 and myelin-oligodendrocyte glycoprotein antibodies: a comparative study. *JAMA Neurol.* 2014;71(3):276–283.
41. **Li X**, Zhang C, Jia D, *et al.* The occurrence of myelin oligodendrocyte glycoprotein antibodies in aquaporin-4-antibody seronegative Neuromyelitis Optica Spectrum Disorder: A systematic review and meta-analysis. *Mult Scler Relat Disord [Internet].* 2021;53:103030. Available from: <https://www.sciencedirect.com/science/article/pii/S2211034821002972>
42. **Peschl P**, Bradl M, Höftberger R, *et al.* Myelin oligodendrocyte glycoprotein: deciphering a target

- in inflammatory demyelinating diseases. *Front Immunol.* 2017;8:529.
43. **Marignier R**, Bernard-Valnet R, Giraudon P, *et al.* Aquaporin-4 antibody–negative neuromyelitis optica: distinct assay sensitivity–dependent entity. *Neurology.* 2013;80(24):2194–2200.
  44. **Jarius S**, Paul F, Franciotta D, *et al.* Cerebrospinal fluid findings in aquaporin-4 antibody positive neuromyelitis optica: results from 211 lumbar punctures. *J Neurol Sci.* 2011;306(1–2):82–90.
  45. **De Seze J**, Kremer L, Collongues N. Neuromyelitis optica spectrum disorder (NMOSD): a new concept. *Rev Neurol (Paris).* 2016;172(4–5):256–262.
  46. **Bruscolini A**, Sacchetti M, La Cava M, *et al.* Diagnosis and management of neuromyelitis optica spectrum disorders–An update. *Autoimmun Rev.* 2018;17(3):195–200.
  47. **Watanabe S**, Nakashima I, Misu T, *et al.* Therapeutic efficacy of plasma exchange in NMO-IgG-positive patients with neuromyelitis optica. *Mult Scler J.* 2007;13(1):128–32.
  48. **Bonnan M**, Cabre P. Plasma Exchange in Severe Attacks of Neuromyelitis Optica. de Seze J, editor. *Mult Scler Int* [Internet]. 2012;2012:787630. Available from: <https://doi.org/10.1155/2012/787630>
  49. **Yamamura T**, Kleiter I, Fujihara K, *et al.* Trial of satralizumab in neuromyelitis optica spectrum disorder. *N Engl J Med.* 2019;381(22):2114–2124.
  50. **Pittock SJ**, Berthele A, Fujihara K, *et al.* Eculizumab in aquaporin-4–positive neuromyelitis optica spectrum disorder. *N Engl J Med.* 2019;381(7):614–625.
  51. **Zhang C**, Zhang M, Qiu W, *et al.* Safety and efficacy of tocilizumab versus azathioprine in highly relapsing neuromyelitis optica spectrum disorder (TANGO): an open-label, multicentre, randomised, phase 2 trial. *Lancet Neurol.* 2020;19(5):391–401.
  52. **Mealy MA**, Levy M. A pilot safety study of ublituximab, a monoclonal antibody against CD20, in acute relapses of neuromyelitis optica spectrum disorder. *Medicine (Baltimore).* 2019;98(25).
  53. **Cree BAC**, Bennett JL, Kim HJ, *et al.* Inebilizumab for the treatment of neuromyelitis optica spectrum disorder (N-MOMentum): a double-blind, randomised placebo-controlled phase 2/3 trial. *Lancet.* 2019;394(10206):1352–1363.