

## NON-COMMUNICATING HYDROCOELE OF THE CANAL OF NUCK: A RARE FINDING IN A RURAL-DWELLING NIGERIAN WOMAN

K.I Egbuchulem<sup>1</sup>, B.A. Akinboyewa<sup>2</sup>, C.O Onwurah<sup>3</sup>

1. Division of Paediatric Surgery, Department of Surgery, University College Hospital, Ibadan.
2. Department of Anaesthesia, University College Hospital, Ibadan.
3. Final Year Medical Student, Faculty of Clinical Sciences, University of Ibadan, Ibadan.

*Correspondence:*

**Dr. K.I Egbuchulem**

Division of Paediatric Surgery,  
Department of Surgery,  
University College Hospital,  
Ibadan.

Email: ifeanyiiegbuchulem@yahoo.com

*Submission Date: 16th March, 2023*

*Date of Acceptance: 30th Oct., 2023*

*Publication Date: 1st Nov., 2023*

### ABSTRACT

**Background:** The surgical condition termed hydrocoele of the canal of Nuck is one of the rarest clinical entities in the female group. It occurs due to the failure of obliteration of the derivative of the peritoneum, the processus vaginalis. It usually presents with painless inguinal swellings and is sometimes associated with features of intestinal obstruction if there is hernia coexisting with it that has become obstructed. Abdominopelvic ultrasonography and magnetic resonance imaging provide the basis for diagnosis, where these imaging modalities are available. However, a definite diagnosis may only be made during surgery. Definitive treatment includes groin exploration and excision of the cyst with high ligation of the neck of the sac up to the peritoneal pouch, along with repair of the inguinal hernia, if present.

**Case Presentation:** We present a rare case of a 34-year-old woman who presented with clinical features of a left inguinolabial swelling post-surgery, and diagnosed as left recurrent irreducible inguinal hernia. Intraoperatively, a cystic swelling with serous collection was observed. She had hydrocoelectomy and repair of the left groin surgical wound.

**Conclusion:** Hydrocoele of the canal of Nuck may be misdiagnosed as inguinal hernia because of its rarity, lack of adequate knowledge regarding the entity and paucity of literature on the subject matter. This report is to furthermore increase our level of awareness of this condition especially after a previous groin surgery.

**Keywords:** Canal of Nuck, Hydrocoele, Rural Nigerian woman.

### INTRODUCTION

Hydrocoele of the canal of Nuck is an uncommon condition seen in the female adult population. It is an anatomical extension of the parietal peritoneum that has developed into an analogous entity, and when it fails to obliterate, hydrocoele could develop.<sup>1-3</sup>

Hydrocoele of the canal of Nuck was first described by Anton Nuck in the seventeenth century, and the fluid filled processus vaginalis (Hydrocoele) within the inguinal canal of the female is named after him.<sup>4</sup> The incidence of a patent processus vaginalis decreases with age. In newborns, 80-94% have patent processus vaginalis.<sup>5</sup> As many as 30% of adults are discovered to have a patent processus vaginalis at autopsy. Why all patient with patent processus vaginalis do not develop into hydrocoele is not well understood. Hydrocoele of the canal of Nuck occurs more in adult females and less in infants and girls.<sup>6</sup>

We report a case of an adult female who initially was thought to have a left recurrent irreducible Inguinolabial Hernia status post a previous left groin

hernia repair. She had groin exploration with finding of a left cystic swelling within the canal of Nuck. The aim of this report is to draw the attention of practitioners to the occurrence of this rare finding, and to make them raise their index of suspicion and consider this as a possible differential diagnosis in young females who present to them with inguinolabial swelling especially after previous groin surgery.

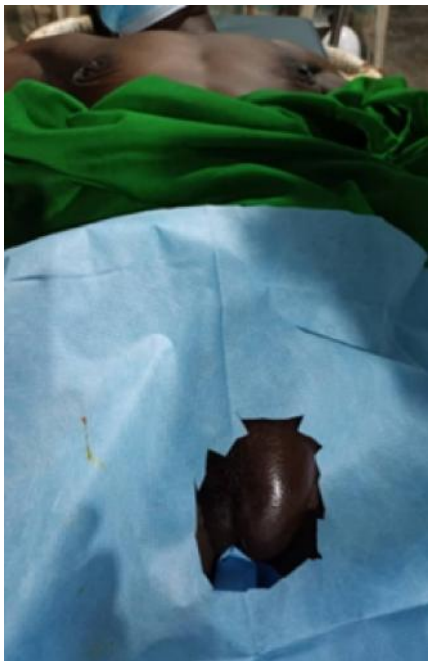
### CASE PRESENTATION

She is a 34-year-old woman, trader and farmer who lives in Ago-are area of Oyo State in western Nigeria. She presented to a surgical outreach with complaints of progressive painless swelling in the left groin. Symptoms were said to have been noticed after a left inguinal repair which she had three months earlier at a secondary health facility for an inguinal hernia. The procedure was said to be largely uneventful. There was no family history suggestive connective tissue disorder and she neither takes alcohol nor smoke cigarette. There is no history of chronic cough,

constipation, or abdominal swelling. There were no features suggestive of intestinal obstruction.

On general examination, she was not found to be obese, no swelling on the right groin region, the left groin revealed a previous well-healed scar, no positive cough impulse, an irreducible left Inguinolabial swelling, with soft consistency and non-tender, measuring approximately 10 × 4 centimeters. Transillumination was unremarkable and vital signs were within normal limits.

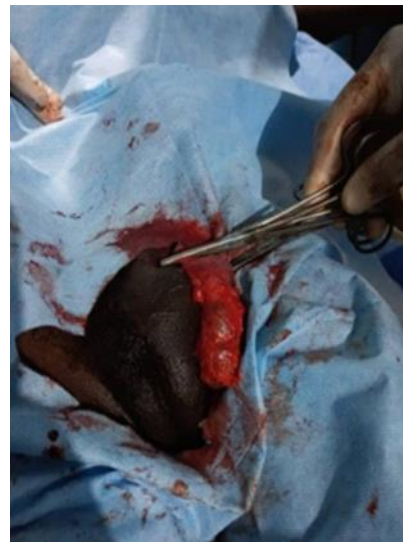
A preoperative clinical diagnosis of Left Recurrent Irreducible Inguinolabial hernia was made. (Figure 1). Laboratory investigations done were within normal limits. The patient was prepared for surgery as per the routine for groin swellings and consents were obtained.



**Figure 1:** Pre-Operative picture of the left inguinolabial swelling.

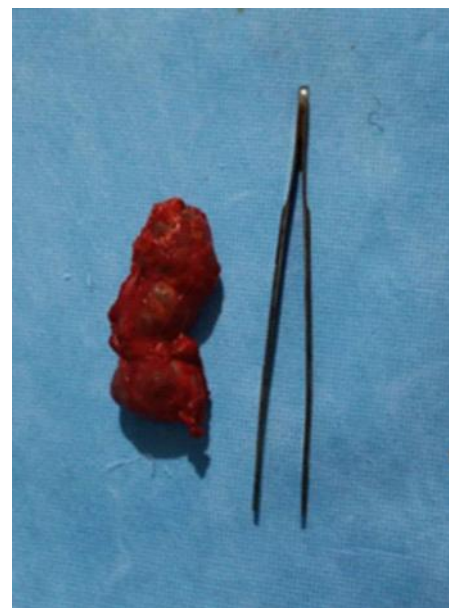A left groin exploration was done under a sub-Arachnoid block type of anaesthesia. The findings of dilated left canal of Nuck with a cystic swelling containing serous fluids (Figures 2) were in keeping with a left non-communicating hydrocele of the canal of Nuck (Type 3).<sup>7</sup>

This cystic lesion extended up to the deep ring, (Figure 3) and this was excised after high ligation of the sac with Vicryl 2/0 suture and the external oblique aponeurosis, subcutaneous layer of the surgically created groin wound were repaired with non-absorbable suture. The immediate post-operative period was uneventful.



**Figure 2:** Intra Operative photograph of the left inguinal region being explored, with a cystic swelling containing serous fluid within it delivered into the wound, suggestive of hydrocele of the canal of Nuck

The patient was discharged on the second post-operative day. A follow-up visits to the clinic in the second and sixth post operative weeks showed satisfactory wound healing.



**Figure 3:** An 8 x 3 centimeters cyst of the canal of Nuck.

## DISCUSSION

Inguinal hernia is the commonest presentation of Inguinal and Inguino-labial swellings in females; however, differential diagnoses do exist though rare. As we tend to see in males with encysted hydrocele of the spermatic cord, hydrocele of the canal of Nuck is an analogous entity in females.<sup>2,3</sup> Huang *et al.*, reported

that the incidence of the hydrocoele of the canal of Nuck in female children was 1% (only 6 cases out of 580) female inguinal hernia cases admitted in Chang Gung Children's Hospital, Taiwan over a 6-year period.<sup>8</sup> The Dutch anatomist, Anton Nuck in the seventeenth century (1691), who described the fluid-filled processus vaginalis in the inguinal canal had this named after him.<sup>4</sup> During embryogenesis, the processus vaginalis, which is an extension of the parietal peritoneum, accompanies the round ligament up to the labia majora and is usually obliterated within the first year of life. Failure to obliterate, results in the formation of hydrocoele of the canal of Nuck. The development of hydrocoele of the canal of Nuck can result following trauma, filariasis and majorly idiopathic however, it is a very rare occurrence following a previous groin surgery.<sup>2,9</sup>

This was the finding in our patient.

Anatomically, there are three types of hydroceles of the canal of Nuck described in the literature.

- i. Type 1 is like encysted hydrocele, which is non-communicating with the peritoneal cavity and is the most common type.
- ii. Type 2 is freely communicating with the peritoneal cavity and resembles congenital hydrocele in males, which may have associated indirect hernia.
- iii. Type 3 is the rarest form, accounting for less than 1% of cases, which occurs owing to partial constriction at the deep ring that allows the distal part to descend into the inguinal canal, with the proximal part being retroperitoneal.<sup>7,10</sup>

Our index patient presented with one of the rarest types – Type 3, and probably the first of its kind because it followed a previous left inguinal herniorrhaphy.

Clinically, hydrocele of the canal of Nuck usually presents with swelling in the inguinal area extending up to the labia majora, it is cystic and non-reducible, features which characterizes hydrocele. The cyst may or may not be trans-illuminant. There may be no features of intestinal obstruction except there is a communicating hydrocele with a dilated internal ring or there is a co-existing hernia component.<sup>2</sup> Sometimes, the cystic swelling may be confused with components of endometriosis if it is communicating with the peritoneal cavity through the fallopian tube and the deep ring,<sup>11</sup> however that was not the case here as there was no such communication.

As a superficial lesion, groin ultrasonography can complement the clinical diagnostic acumen of the physician with findings of a well-defined hypoechoic or anechoic, sausage- or comma-shaped cystic mass

lying superficial and medial to the pubic bone in the inguinal canal, with posterior acoustic enhancement through translucency.<sup>12</sup> Magnetic Resonance Imaging (MRI) is also helpful with the findings of a well-defined, thin-walled, sausage-shaped cystic lesion, which is hyperintense on T2 - weighted image and hypointense on T1 – weighted image in the inguinal area.<sup>13</sup> However, preoperative radiological investigations such as ultrasonography and MRI could not be performed in this case because of the non-availability in this remote, rural and resource-poor setting. As per our protocol, these investigations are not mandatory for clinically diagnosed cases such as hernia or hydrocele.

The definitive management includes open groin exploration surgery, which serves as a final diagnosis and treatment. However, laparoscopic excision of a cyst with associated hernia repair has been documented in the literature with a rewarding outcome.<sup>14</sup>

As it is commonly associated with inguinal hernia, dissection must be carried out to the deep inguinal ring<sup>5</sup>, along with high ligation of the neck of the peritoneal pouch and this were the operative details in this patient.<sup>15</sup>

Hydrocoele of the canal of Nuck may be misdiagnosed as inguinal hernia because of its rarity, lack of adequate knowledge regarding this entity and paucity of literature on the subject matter, furthermore at least a third of the cases are associated with inguinal hernia.<sup>16</sup> This typifies our experience.

## CONCLUSION

Hydrocoele of the canal of Nuck though rare, should be considered as one of the differential diagnoses of groin swelling in females. The outcome of management is comparable to other groin surgeries especially in the absence of preoperative ultrasonographic imaging as was the case in our index patient. Practitioners in resource-poor settings should therefore consider an intra-operative diagnosis when such a case is suspected even in the face of near-absence hi-tech diagnostic facilities.

## REFERENCES

1. **Mandhan P**, Raouf Z, Bhatti K. Infected hydrocele of the canal of Nuck. *Case Rep Urol*. 2013; 2013:275257. doi:10.1155/2013/275257.
2. **Kono R**, Terasaki H, Murakami N. Hydrocele of the canal of Nuck: a case report with magnetic resonance hydrography findings. *Surg Case Rep*. 2015; 1:86. doi:10.1186/s40792-015-0086-5.
3. **Schneider CA**, Festa S, Spillert CR, *et al.* Hydrocele of the canal of Nuck. *N J Med*. 1994;91(1):37–38.

4. **Anderson CC**, Broadie TA, Mackey JE. Hydrocele of the canal of Nuck: ultrasound appearance. *Am Surg.* 1995;61(11):959–961.
5. **Ameh EA**, Garba ES. Infected hydrocoele of the canal of Nuck in a neonate. *Urol Int.* 2003; 71 (2):226-227.
6. **Ortenberg J**. Hydrocoele and hernia in children. *emedicine.com*
7. **McCune WS**. Hydrocele of the canal of Nuck with large cystic retroperitoneal extension. *Ann Surg.* 1948;127(4):750–753.
8. **Huang CS**, Luo CC, Chao HC, *et al.* The presentation of asymptomatic palpable movable mass in female inguinal hernia. *Eur J Pediatr.* 2003; 162:493-495.
9. **Kucera PR**, Glazer J. Hydrocele of the canal of Nuck. A report of four cases. *J Reprod Med.* 1985;30(5):439–442.
10. **Baral S**, Bajracharya P, Thapa N, Chhetri RK. Bilateral Hydrocele of the Canal of Nuck: A Rare Presentation in an Adult Female. *International Medical Case Reports Journal* 2020;13 313–316.
11. **Okoshi K**, Mizumoto M, Kinoshita K. Endometriosis-associated hydrocele of the canal of Nuck with immunohistochemical confirmation: a case report. *J Med Case Rep.* 2017; 11(1): 354.
12. **Manjunatha Y**, Beeregowda Y, Bhaskaran A. Hydrocele of the canal of Nuck: imaging findings. *Acta Radiol Short Rep.* 2012;1(3).
13. **Park SJ**, Lee HK, Hong HS, *et al.* Hydrocele of the canal of Nuck in a girl: ultrasound and MRI appearance. *Br J Radiol.* 2004;77(915):243– 244.
14. **Qureshi NJ**, Lakshman K. Laparoscopic excision of cyst of canal of Nuck. *J Minim Access Surg.* 2014;10(2):87–89.
15. **Wiener ES**, Touloukian RJ, Rodgers BM, *et al.* Hernia survey of the Section on Surgery of the American Academy of Pediatrics. *J Pediatr Surg.* 1996;31(8):1166–1169.
16. **Jagdale R**, Agarawal S, Chhabra S, Jewan SY. Hydrocoele of the canal of Nuck: Value of Radiological Diagnosis. *Journal of Radiology Case Reports.* 2012;6(6):18-22.