

INITIAL EXPERIENCE WITH 3D-ULTRASOUND AS AN ADJUNCT TO 2D-ULTRASOUND IN FETAL ANOMALY DIAGNOSIS IN A NIGERIAN DIAGNOSTIC FACILITY

J.A. Akinmoladun^{1,2}, V.O. Oboro¹, and T.I. Adelokun¹

1. OMVIAL 3D Fetal Diagnostic Centre, Ibadan

2. Department of Radiology, Faculty of Clinical Sciences, College of Medicine, University of Ibadan, Ibadan

Correspondence:

Dr. J.A. Akinmoladun

Department of Radiology,

Faculty of Clinical Sciences,

College of Medicine,

University of Ibadan,

Ibadan

Email: jaakinmoladun@yahoo.com

ABSTRACT

Introduction: Two-Dimensional ultrasound (2DUS) has been the preferred screening method for fetal abnormalities for several decades. Three-dimensional ultrasound (3DUS) is a technique that converts standard 2D grayscale ultrasound images into a volumetric dataset which allows visualization of the fetus in all three dimensions at the same time. It provides an improved overview and a more clearly defined demonstration of adjusted anatomical planes. The use of 3D imaging is however limited to being an adjunct to 2DUS in the visualization of fetal anomalies. The objective of this study is to highlight the importance of adding three-dimensional ultrasound (3DUS) to two-dimensional ultrasound (2DUS) during fetal anomaly screening.

Methodology: This is a descriptive study conducted at a private fetal diagnostic center, in Nigeria between January 2014 and December 2016. The diagnosis of fetal anomalies was first made with 2DUS after which they were evaluated with 3D ultrasound images displayed on the monitor.

Results: Nine fetuses with various fetal anomalies diagnosed on 2DUS were selected for further evaluation with 3DUS. These anomalies include a neck mass, lumbar spinal abnormality, bilateral cleft lip, thanatophoric dysplasia, anencephaly, omphalocele, posterior urethral valve with anhydramnios and ambiguous genitalia diagnosed. These anomalies were better demonstrated on 3DUS.

Conclusion: 2DUS remains the mainstay imaging modality in screening for fetal anomalies. However, 3DUS may complement 2DUS by allowing better delineation of anomalies and gives the parents a better visualization and understanding of identified anomalies, thereby assisting in informed decision making.

Keywords: Two-dimensional; Three-dimensional; Ultrasound; Fetal; Anomalies.

INTRODUCTION

Two-Dimensional ultrasound (2DUS) has been the preferred screening method for fetal abnormalities for several decades^{1,2}. This is because of its advantages which include safety for the mother and fetus, cost-effectiveness, easy accessibility and real time imaging. Also, the images on 2DUS are obtained more easily, rapidly, efficiently and accurately with most fetal abnormalities being detected^{2,3}. Screening for fetal abnormalities otherwise known as fetal anomaly scans was initially done in the second trimester between 18-22 weeks. However, in the last decade, this screening has moved from the second into the first trimester because of the advent of high resolution ultrasound machines which image the fetus in greater detail at all gestational ages^{4,5}. In the hands of experienced sonologists/sonographers, anatomic surveys between 11 and 14 weeks can now be carried out with good visualization rates of many structures. Some structural

anomalies will nearly always be detectable in the first trimester e.g. anencephaly, holoprosencephaly, facial cleft and conjoined twins⁵⁻⁸.

Three-dimensional ultrasound (3DUS) is a technique that converts standard 2D grayscale ultrasound images into a volumetric dataset. The technique was developed for problem-solving (particularly in obstetric/gynecologic examinations) and to potentially reduce the operator dependence of ultrasound imaging^{9,10}. 3DUS allows visualization of the fetus in all three dimensions at the same time, providing an improved overview and a more clearly defined demonstration of adjusted anatomical planes¹⁰. It allows visualization of the fetal surface as well as more accurate volume and weight measurements thus improving the detection rate of structural fetal abnormalities in early gestation^{11,12}. The use of 3D

imaging as a primary screening tool is however limited, therefore it can only be best utilized as a second-stage test¹¹. Many studies have been done to determine the advantages of 3DUS over 2DUS¹⁰⁻¹³. Some of these studies showed that 3DUS only act as an adjunct to 2DUS in the visualization of fetal anomalies¹⁰⁻¹². However, some studies were able to discover some more complicated fetal malformations on 3DUS that were missed by 2DUS¹³.

3DUS has only been recently introduced to this part of our country and it has been shown to clearly demonstrate the abnormalities seen on 2DUS and also helps the parents in understanding the anomalies better¹¹. We hereby present some of the anomalies detected by 2DUS that were confirmed with 3DUS with a review of literature. Future studies will be aimed at determining if 3DUS is able to detect more anomalies than 2DUS.

MATERIALS AND METHODS

This is a pictorial description of selected nine fetuses with anomalies detected on 2DUS and confirmed by 3DUS. The study was conducted at the OMVIAL 3D fetal diagnostic Centre, in Ibadan, Oyo state, Nigeria between January 2014 and December 2016. Voluson P8 General Electric (GE) ultrasound machine was used in acquiring the images. The diagnosis of fetal anomalies was first made with 2DUS and the machine was later switched to the 3D mode, with the anomaly displayed in 3 orthogonal planes which led to the acquisition of a 3D image which was then displayed on the screen. The scans were done by a sonographer and confirmed by fetal imaging sonologist. This imaging system provided conventional two-dimensional (2D) sonographic images and also generated within seconds high-quality 3D images in the surface and transparent modes with no need for an external workstation. Informed consent was

obtained from all the mothers who participated in the study.

RESULTS

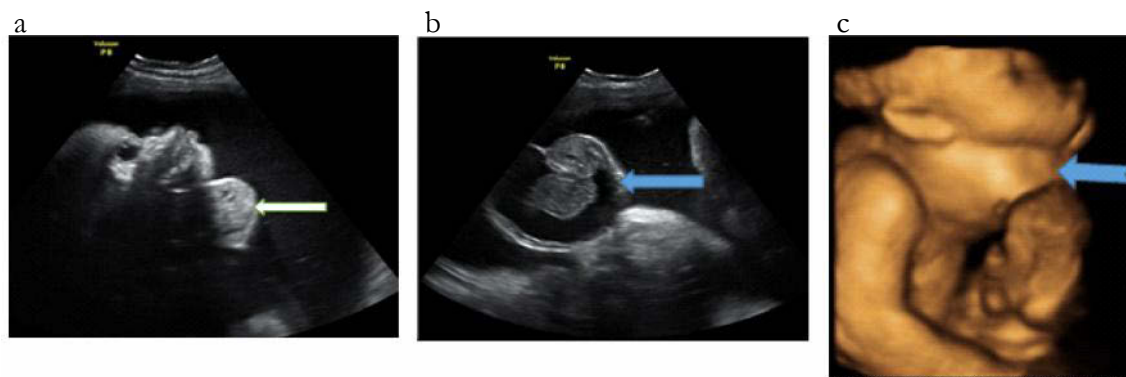
Using this imaging system, we obtained 2D and 3D images of the selected anomalies. Nine different fetuses with anomalies had both 2D and 3DUS done (Table 1). A good fetal profile image was acquired for some of the mothers (Figure 1) on 3D with a corresponding

Table 1: Frequency of the selected fetal anomalies detected on 2DUS that were demonstrated on 3DUS

Anomalies	Frequency(n)
Neck Mass	1
Vertebral anomaly	1
Bilateral cleft lip	1
Omphalocele	2
Thanatophoric dysplasia	1
Anencephaly	1
Posterior urethral valve	1
Ambiguous genitalia	1
Total	9

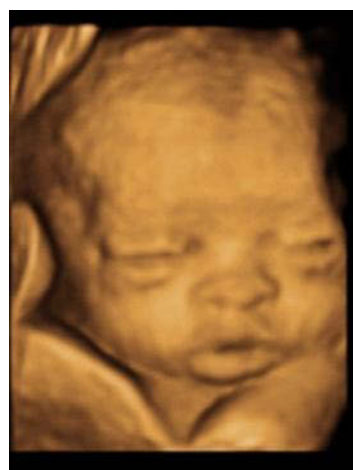

Figure 1: Surface rendered 3D ultrasound image of a normal fetal face



Figures 2a: 2-dimensional ultrasound image of a fetus in sagittal plane at 32 weeks gestational age showing a huge mass in the fetal neck (white arrow).
2b: A tranverse view of the mass showing enlarged thyroid glands with fluid surrounding them (blue arrow).
2c: 3-dimensional surface rendered image of the fetus in a slightly oblique plane confirming the anterior neck mass (notched blue arrow).

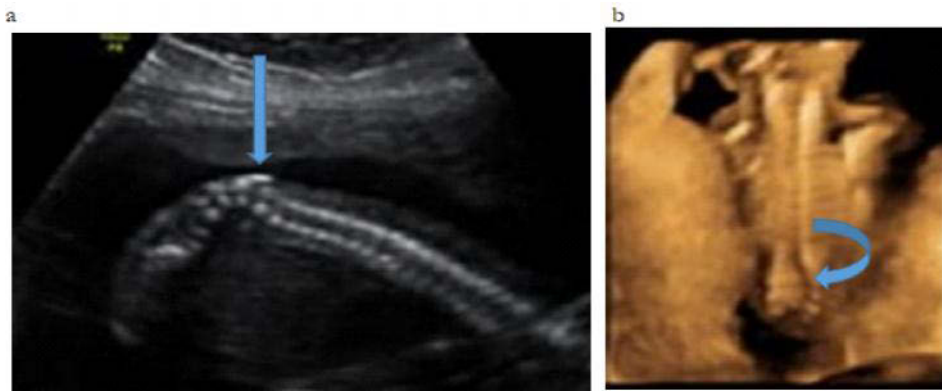


Figure 3a: 2 dimensional image of a 22 week old fetus in sagittal plane showing distortion of the usual vertebral alignment in the lower lumbar and sacral vertebral bodies (block arrow).
Figure 3b: a 3 dimensional surface rendered image of the same fetus confirming the vertebral body anomaly (curved arrow)

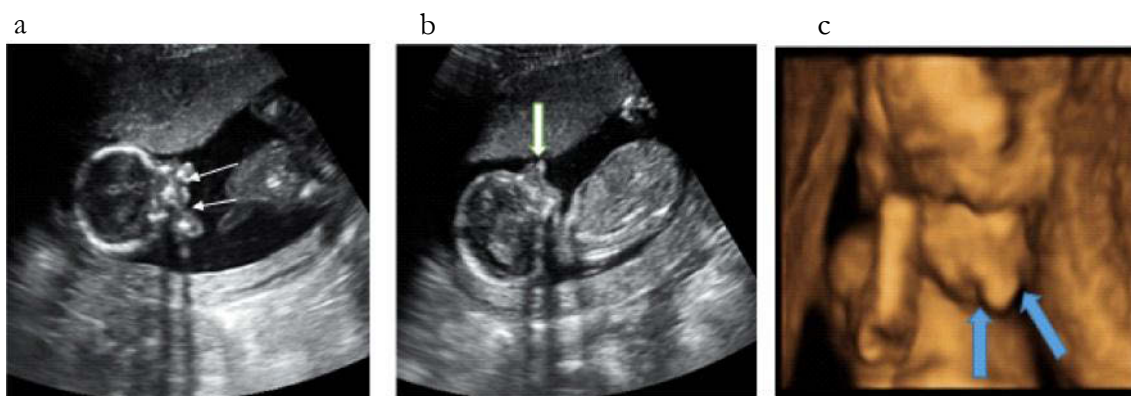
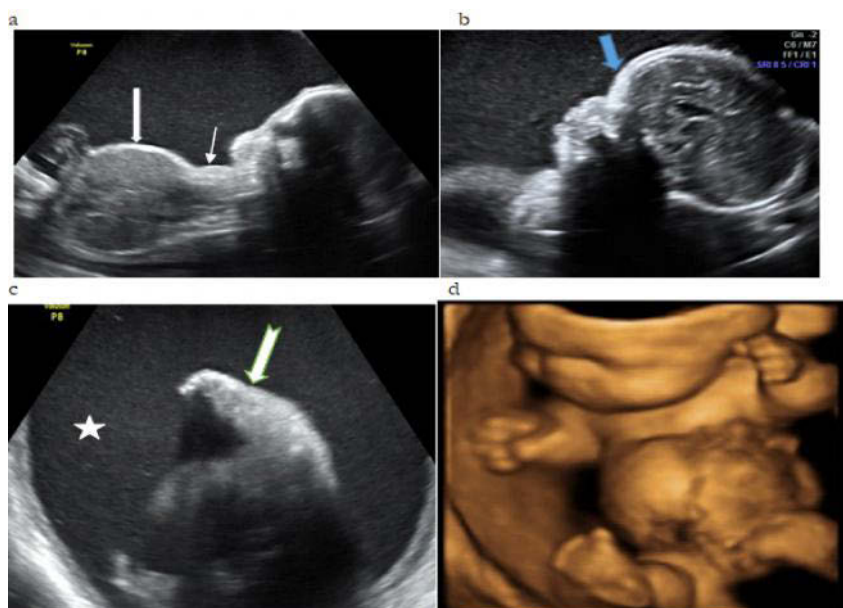


Figure 4a: 2-dimensional coronal image of a 15 week old fetus showing bilateral cleft of the upper lip (slim white arrows)
4b - A sagittal view of the same fetus showing an abnormal median profile (thick white arrow)
4c - Surface rendered 3-dimensional image of the fetus confirming the bilateral cleft (thick blue arrows)



Figures 5a: 2-dimensional images of a fetus with thanatophoric dysplasia showing a small chest (slim arrow) and a protuberant abdomen (thick arrow).
5b: 2-dimensional images showing macrocephaly with frontal bossing (blue arrow)
5c: 2-dimensional images showing a short upper limb (notched arrow) with polyhydramnios (star)
5d: A surface rendered 3-dimensional image of the fetus confirming the macrocephaly, small chest, protuberant abdomen and short limbs

surface rendered 3D image. The first anomaly was that of a 32-week old fetus with neck mass (Fig. 2a-c). The second anomaly was a 22-week old fetus with spinal bifida at the lower lumbar region (Fig. 3a-b). The third anomaly is a 15-week old fetus with bilateral

cleft lip (Fig. 4a-c). The fourth anomaly is a 33-week old fetus with thanatophoric dysplasia (Fig. 5a- d). The fifth anomaly is that of a 28-week fetus with anencephaly (Fig. 6a&b). The sixth and seventh anomalies were two different cases of omphalocele

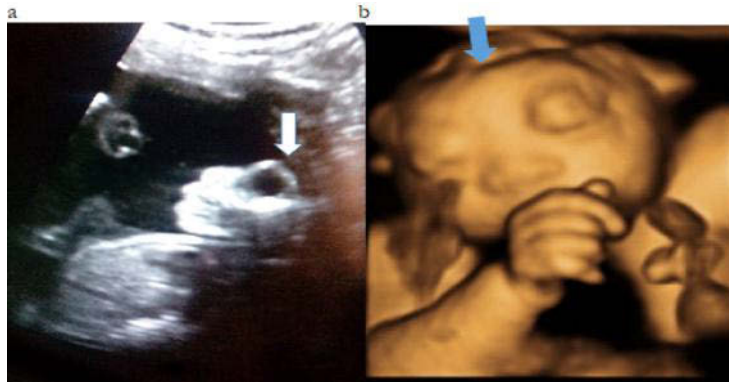


Figure 6a: 2-dimensional ultrasound image of a fetus showing absence of the cranium giving a frog eye appearance (white arrow).

6b: 3-dimensional image of the fetus confirming the absent cranium (blue arrow)

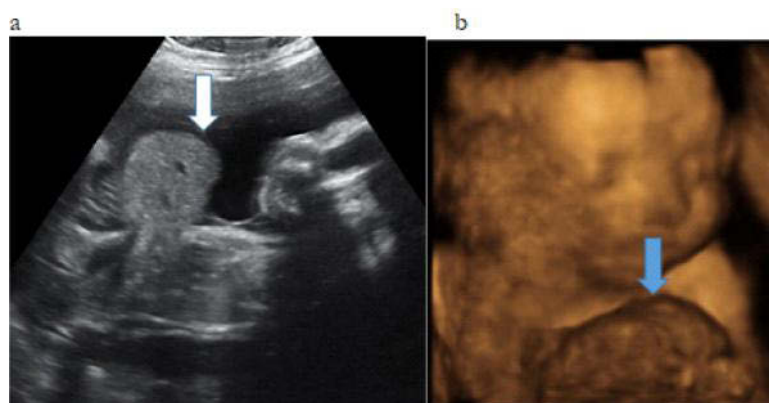
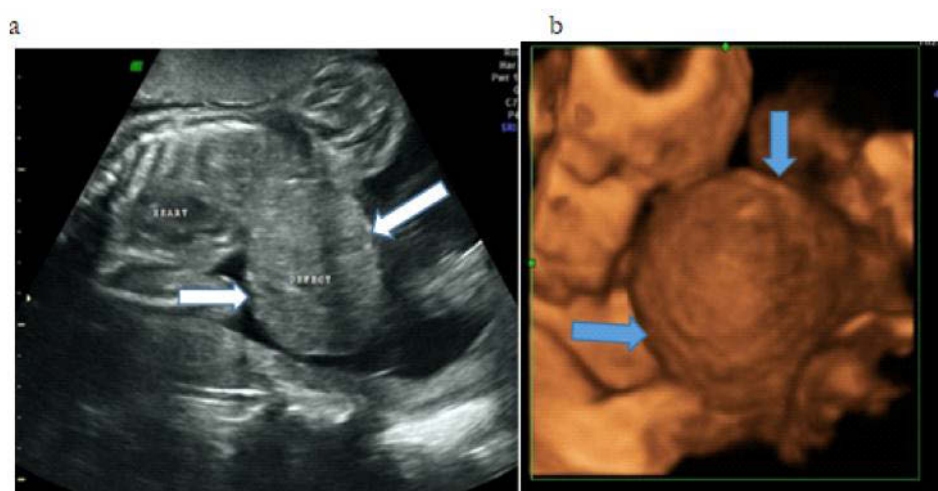

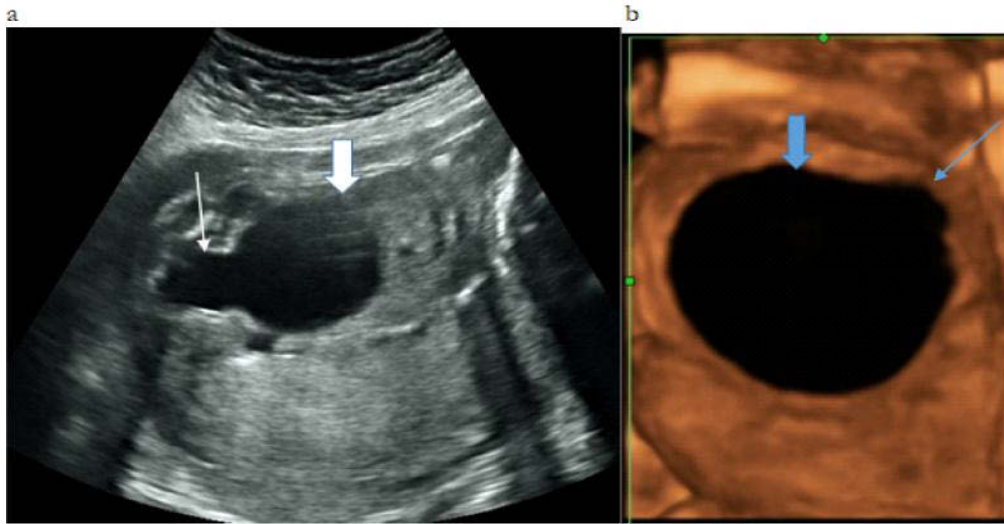
Figure 7a: 2-Dimensional image of a fetus showing an anterior abdominal defect with the herniated content covered by a membrane (white arrow) consistent with omphalocele

7b: 3-Dimensional image of the fetus showing the herniated abdominal content over the fetal chest anterior (blue arrow).



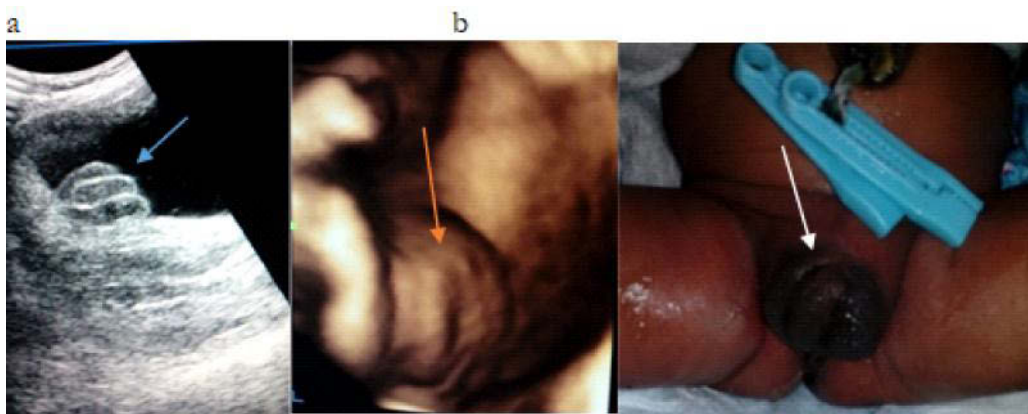
Figures 8a: 2-Dimensional image of a fetus showing an anterior abdominal defect with the herniated content covered by a membrane (white arrows) consistent with omphalocele

8b: 3-Dimensional image of the fetus showing the herniated abdominal content below the head (blue arrows).



Figures 9a: a 2-dimensional ultrasound of the fetal abdomen showing distension of the bladder (thick white arrow) and dilated posterior urethra giving the keyhole configuration (slim white arrow). There is associated severe oligohydramnios

9b: 3-dimensional minimum rendering mode showing the distended urinary bladder (thick blue arrow) and part of the dilated posterior urethra (slim blue arrow)



Figures 10a: 2-dimensional image of the fetal genitalia showing a fetal genitalia which gives a 'curly flower' appearance (blue arrow) consistent with an ambiguous genitalia.

10b: 3D surface rendered ultrasound image of the genitalia (orange arrow) with non-visualization of the labia as well as the phallus.

10c: the fetus post-delivery showing enlarged clitoris with no phallus (white arrow) confirming the diagnosis.

(Fig. 7&8). The eighth anomaly is an 18-week old fetus with posterior urethral valve with anhydramnios (Figure 9). The ninth anomaly is that of ambiguous genitalia diagnosed at 34weeks GA (Figure 10a-c)

DISCUSSION

Kazunori Baba was the first to work on a 3D ultrasound system in 1984 and he succeeded in obtaining 3D fetal images by processing the raw 2D images on a mini-computer in 1986⁹. He successfully produced 3D images of the fetus but these were inferior to that produced on conventional 2DUS scanners. At the same time, it took an average of ten minutes to generate each 3D image making the setup

impractical for routine clinical use^{9,14}. However, since then there has been various advancements in the image production and it has evolved into a powerful technique with different modalities now available¹¹⁻¹⁵. In contrast to conventional 2DUS that only allows imaging in a single plane, 3DUS offers several image displays that do not exist in 2D imaging which include scanning in the coronal plane, improved assessment of complex anatomic structures, surface analysis of minor defects, volumetric measurements of organs, "plastic" transparent imaging of fetal skeleton, spatial presentation of blood flow arborization and storage of scanned volumes and images^{16,17}. In obstetrics, in particular, the amniotic fluid surrounding the fetus offers ideal preconditions for the assessment of the

surface of the embryo/fetus which is the basis for the surface rendering mode.¹⁸

All the surface rendered modes in this study were made possible because of adequate fluid that surrounded the fetuses.

3DUS has brought so many benefits to fetal ultrasound imaging which includes its ability to enhance maternal-fetal bonding, improved comprehension of some fetal anomalies by parents, improved recognition and better confirmation of certain anomalies such as cleft lips, polydactyl, micrognathia, malformed ears, club foot, vertebral malformations and other anomalies appearing on the surface of the fetus.^{19,20} Three-dimensional ultrasound allows visualization of the fetal malformations in all three dimensions at the same time, providing an improved overview and a more clearly defined demonstration of adjusted anatomical planes.^{20,21} The mothers of the selected fetuses in this study were able to understand the anomalies better after seeing the 3D images which informed their decisions on whether to continue with the pregnancy or not.

Despite all the benefits of 3DUS to imaging, there has been many conflicting studies on whether 3D ultrasound adds any other information to what has already been detected on 2DUS. Some studies have shown that 3DUS was able to discover some complicated fetal malformations that were missed by 2DUS and were also able to precisely show the fetal malformations more than 2DUS did.^{13,15} According to the authors, the modality can be a powerful adjunctive tool to 2DUS in providing a more comprehensible impression of congenital anomalies¹². However, some other studies showed that 3D ultrasound did not give any additional information to what has been detected on 2DUS^{11,12}. No additional information was added in our own study. The 3D images only demonstrated the anomalies that were detected on 2D and made it clearer to the parents.

Ghi *et al.*¹¹, Nyberg *et al.*¹² and Bronshtein *et al.*²² in their studies found out that 2D ultrasound was 100% accurate in identifying the type of fetal anomaly with no false positives. Whereas when 3D ultrasound was systematically applied in these fetuses, it failed to provide additional diagnostic information to that of the 2D examination. The conclusion from these studies was that the accuracy of conventional 2D ultrasound in the detection of fetal anomalies was very high, and was not increased by the use of 3D ultrasound. All anomalies in our study were detected on 2DUS and confirmed on 3DUS. No additional diagnostic information was given by the 3D images in our study.

Some other authors found that although conventional 2-dimensional sonography (2DUS) is able to detect many kinds of fetal malformations, the detection rate in low-risk pregnancies could be poor especially in the primary care setting. Therefore, the adjunctive use of 3DUS will increase the detection rate and quality of assessment of fetal anomalies¹⁵.

In a study by Stanojevic *et al.*²³, all GI anomalies initially diagnosed with 2D ultrasound were confirmed by 3D ultrasound and the major advantage of 3D over 2D ultrasound was the more comprehensive anatomical information about GI anomalies, especially in providing the level of defects in the fetuses with diaphragmatic hernia and obstructive intestinal anomalies. This was not confirmed in our study because there were no GI anomalies among the selected cases. In a study by Yigiter *et al.*¹⁴, out of one thousand twenty-four pregnant women, seventy-six patients had a total of 190 anomalies that were evaluated by both 2D and 3DUS. 3DUS images provided additional information and confirmed diagnoses in 130 (69%) anomalies. The authors then concluded that in comparison of 3DUS with 2DUS, 3DUS offers more diagnostic information in evaluating fetal malformations, particularly malformations of the face and cranium, spine, extremities and body surface, thereby making 3DUS an excellent adjunctive tool to 2DUS in the evaluation of fetal anomalies. This was confirmed in our study as anomalies of the cranium, face, neck and spine among the selected cases were clearly demonstrated on 3DUS.

In a study by Ruano *et al.*¹³, prenatal 2DUS was compared to prenatal 3D-US and 3D-HCT (High Resolution Computed Tomography) in the evaluation of skeletal dysplasia. They found that 3DUS identified more abnormalities than did 2DUS and gave more details about the skeletal abnormalities. Although 3DHCT was able to identify significantly more skeletal findings than 3DUS, 3DUS is preferred to 3DHCT because of its lower cost and the absence of fetal irradiation.

Gonçalves *et al.*²⁴ in a study on fetal anomalies using both 3D and 3DUS on 45 fetuses with 82 congenital anomalies, complete agreement between 2DUS and 3DUS/4D ultrasonography was observed in 90.4% of the findings. Two of the cases with discordant were cardiac anomalies while the third was a skeletal dysplasia. There was also no significant difference in diagnostic conformity to neonatal outcomes when the two methods were compared.

Dyson *et al.*¹⁰ in a study with Sixty-three fetuses with 103 anomalies which were scanned prospectively with

both 2DUS and 3DUS. 3DUS images provided additional information in 53 anomalies (51%), were equivalent to 2DUS in 46 anomalies (45%), and were disadvantageous in four anomalies (4%). The 3DUS was most helpful in the evaluation of fetuses with facial anomalies, hand and foot abnormalities, axial spine and neural tube defects. Additional information provided by 3DUS images impacted clinical management in 5% of the fetuses.

The use of 3DUS has been found to be of tremendous benefit in the diagnosis of some facial anomalies like cleft lip and Palate when compared with 2DUS. In a study by Pretorius *et al.*²⁰ who examined fetal face using both 3DUS and 2DUS, 3DUS confirmed a normal lip in 92% of fetuses compared with 76% with 2DUS. They concluded that 3DUS offers more potential in being more definitive in the diagnosis of cleft palate than 2DUS. There have also been some advances in the 3DUS evaluation of the fetal heart. A fetus with bilateral cleft was among the fetuses evaluated in this study but no cardiac anomaly was evaluated.

There is some contemplation on whether 3DUS should replace 2DUS in screening for anomaly during the routine mid trimester fetal ultrasound. Roy-Lacroix *et al.*²⁵ in a study observed that even though 3DUS could excellently image the fetal lumbar and thoracic spine as well as give a good four chamber view, it has some limitations in the assessment of some fetal parts like the fetal head, upper limbs and the placenta, making it a second-stage test rather than a screening tool. The use of 3DUS as a screening tool was not evaluated in this study but this may be considered as a future study.

CONCLUSION

With all the benefits and advantages of 3DUS over 2DUS, it has limitations if used as a screening tool for fetal anomalies. It can only complement, rather than substitute, the conventional 2DUS. 2DUS remains the mainstay modality in the screening fetal anomalies with 3DUS serving as an adjunct.

REFERENCES

1. **Rao R**, Platt LD. Ultrasound screening: Status of markers and efficacy of screening for structural abnormalities. *Semin Perinatol* 2016; 40(1):67-78.
2. **Grenert L**, Persson PH, Gennser G. Benefits of ultrasonic screening of a pregnant population. *Acta Obstet. Gynecol. Scand* 1978; suppl.78: 5-14.
3. **Levi S**. Routine Ultrasound Screening of Congenital Anomalies: An Overview of the European Experience. *Annals of the New York Academy of Sciences* 1998; 847: 86-98.
4. **Martinez-Ten P**, Adiego B, Illescas T, *et al.* First-trimester diagnosis of cleft lip and palate using three-dimensional ultrasound. *Ultrasound Obstet Gynecol* 2012; 40: 40-46.
5. **D'Alton ME**, Cleary-Goldman J. Additional benefits of first trimester screening. *Semin Perinatol* 2005. 29(6): 405-411.
6. **Economides DL**, Whitlow BJ, Braithwaite JM. Ultrasonography in the detection of fetal anomalies in early pregnancy. *Br J Obstet Gynecol* 1999; 106: 516-523.
7. **Donnelly JC**, Malone FD. Early fetal anatomical sonography. *Best Practice & Research Clinical Obstetrics and Gynaecology* 2012; 26: 561-573.
8. **Lawrence DP**. Should the first trimester ultrasound include anatomy survey? *Seminars in Perinatology* 2013; 37: 310- 322.
9. **Baba K**, Okai T, Kozuma S, *et al.* Real-time processable three-dimensional US in obstetrics. *Radiology* 1997; 203: 571.
10. **Dyson RL**, Pretorius DH, Budorick NE, Three-dimensional ultrasound in the evaluation of fetal anomalies. *Ultrasound Obstet Gynecol* 2000; 16:321-328.
11. **Ghi T**, Perolo A, Banzi C, *et al.* Two-dimensional ultrasound is accurate in the diagnosis of fetal craniofacial malformation, *Ultrasound Obstet Gynecol* 2002; 19: 543-551.
12. **Nyberg DA**, Sickler GK, Hegge FN, *et al.* Fetal cleft lip with and without cleft palate: US classification and correlation with outcome. *Radiology* 1995; 195: 677-684.
13. **Ruano R**, Molho M, Roume J, Ville Y, Prenatal diagnosis of fetal skeletal dysplasias by combining two-dimensional and three-dimensional ultrasound and intrauterine three-dimensional helical computer tomography, *Ultrasound Obstet Gynecol* 2004; 24: 134-140.
14. **Yigiter AB**, Kavak NS. Evaluation of fetal anomalies by two and three-dimensional ultrasound, *Gynaecol Perinatol* 2007;16(2):62-67.
15. **Baba K**, Satoh K, Sakamoto S, *et al.* Development of an ultrasonic system for three-dimensional reconstruction of the foetus. *J Perinat Med* 1989; 17:24.
16. **Merz E**, Bahlmann F, Weber C. Volume scanning in the evaluation of fetal malformations: a new dimension in prenatal diagnosis. *Ultrasound Obstet Gynecol* 1995; 5:222-227.
17. **Xu HX**, Zhang QP, Lu MD, Comparison of two-dimensional and three-dimensional sonography in evaluating fetal malformations. *J Clin Ultrasound* 2002; 30:515-525.

18. **Timor-Tritsch IE**, Platt LD. Three-dimensional ultrasound experience in obstetrics. *Curr Opin Obstet Gynecol* 2002; 14: 569–575.
19. **Sedgmen B**, McMahon C, Cairns D, *et al.* The impact of two-dimensional versus three-dimensional ultrasound exposure on maternal–fetal attachment and maternal health behavior in pregnancy. *Ultrasound Obstet Gynecol* 2006; 27: 245–225
20. **Pretorius DH**, House M, Nelson TR, Hollenbach KA. Evaluation of Normal and Abnormal Lips in Fetuses: Comparison Between Three- and Two-Dimensional Sonography. *AJR* 1995; 165:1233-1237.
21. **Steiner H**, Staudach A, Spitzer D, Schaffer H. Diagnostic techniques: Three-dimensional ultrasound in obstetrics and gynaecology: technique, possibilities and limitations. *Human Reproduction*, 1994; 9(9): 1773–1778.
22. **Bronshtein M**, Blumenfeld I, Kohn J, Blumenfeld Z. Detection of cleft lip by early second-trimester transvaginal sonography. *Obstet Gynecol* 1994; 84: 73–76.
23. **Stanojevic M**, Hughes MK, Zaputovic K, *et al.* The Role of 2D and 3D ultrasound in Evaluation of Fetal Gastrointestinal Anomalies, *Donald School Journal of Ultrasound in Obstetrics and Gynecology* 2014;(3):316-320
24. **Goncalves LF**, Nien JK, Espinosa J, *et al.* What does 2-dimensional imaging add to 3- and 4-dimensional obstetric ultrasonography? *J Ultrasound Med* 2006;25(6):691–699.
25. **Roy-Lacroix ME**, Moretti F, Ferraro ZM, *et al.* A comparison of standard two-dimensional ultrasound to three-dimensional volume sonography for routine second-trimester fetal imaging. *Journal of Perinatology* 2017; 37: 380–386.