

BILATERAL GANGLIONIC HAEMORRHAGIC STROKE COMPLICATING SUSPECTED MENINGOCOCCAEMIA: A CASE REPORT

S.A. Omenai¹, O.O. Okonkwo¹, A.A. Salami¹, A.A. Labaeka² and C.A. Okolo¹

1. Department of Pathology, University College Hospital, Ibadan.
2. Department of Paediatrics, University College Hospital, Ibadan.

Correspondence:

Dr. C.A. Okolo

Department of Pathology,
University College Hospital,
Ibadan
Email: clemabuokolo@yahoo.ca

ABSTRACT

Haemorrhagic stroke in pyogenic meningitis is a rare complication accounting for about 2% of all complications^{1,2}. It often results from disseminated intravascular coagulation, which is a complication of bacterial meningitis and portends a poor prognosis. A superimposed intracranial haemorrhage, although extremely rare, is associated with high mortality rate.

We report a child who had haemorrhagic stroke during the acute phase of bacterial meningitis. The diagnosis was made during post mortem examination. It was discovered that she had suffered haemorrhagic necrosis of both basal ganglion nuclei.

Early imaging is advised in meningitis patient presenting with altered levels of consciousness to detect cerebrovascular complications.

INTRODUCTION

Meningitis is a severe infection of the leptomeninges caused by either viruses, bacteria, parasites or fungi. Mortality rates is as low as 2% in infants and children and as high as 20-30% in neonates and adults³. Cerebral vasculopathy is a complication of bacterial meningitis and ischaemic stroke is much more common than haemorrhagic stroke and it usually occurs during the acute phase of meningitis^{1,2,4,5}. Bacterial meningitis remains a leading cause of mortality from infectious disease globally, and the neurologic complications associated with this disease is a major contributor to mortality associated with the disease⁶.

In the paediatric age groups, meningitis usually develop after an encapsulated bacteria which had colonised the nasopharynx are disseminated into the blood and through haematogenous route breach the blood-brain barrier and colonise the leptomeninges where they rapidly multiply⁷. The body's immune system mounts a response against the microbes. Studies done in rabbits with C3 deficiency have demonstrated the importance of the complement system in meningitis⁸. Genetic deficiencies in the important early response cytokines such as TNF- α , IL-1 β and IL-6 predisposes an individual to central nervous system infections that could also run a fulminant course⁸⁻¹¹.

Cerebral vasculopathy in bacterial meningitis can occur from infection by varying organisms such as *Streptococcus pneumoniae*, *Neisseria meningitidis*, *Haemophilus influenzae* and *Staphylococcus aureus*^{4,7,12,13}. Haemorrhagic stroke from bacterial meningitis is rare^{1,14}. Various pathophysiological mechanisms have been proposed, and these

includes focal hyper-perfusion from loss of cerebral autoregulation, disseminated intravascular coagulation (DIC), localized vasculitis, and microaneurysm formation^{1,5}. This adverse event confers a worse prognosis on the meningitis with higher morbidity and mortality^{1,15}. Early diagnosis of cerebrovascular event complicating meningitis, would allow for prompt surgical intervention to improve prognosis⁵.

We report the case of nine-year-old female child who presented and died within 24 hours of presentation from bilateral basal ganglia haemorrhages due to acute bacterial meningitis.

CASE REPORT

A nine-year-old female that was seen in paediatric clinic with history of fever, sore throat, non-productive cough, vomiting and generalized body weakness. She was a known asthmatic. She was nebulized and placed on antibiotics and antimalarials. Her condition deteriorated later in the night. She was brought into the children emergency unit with complaints of fever of six hours and lack of response to call of two hours duration. She was admitted into the intensive care unit and managed as a case of meningitis. She was acutely ill, anicteric and not cyanosed. There was tachycardia, the blood pressure was 90/60mmHg. She was tachypnoeic and dyspnoeic. There were crepitations in the lower lung zones. The Glasgow coma score (GCS) on presentation was 13, the neck was supple, Kernig's and Brudzinski's sign were negative. Her pupils were 3mm bilaterally and reacted briskly to light. Muscle tones and reflexes were normal and there was

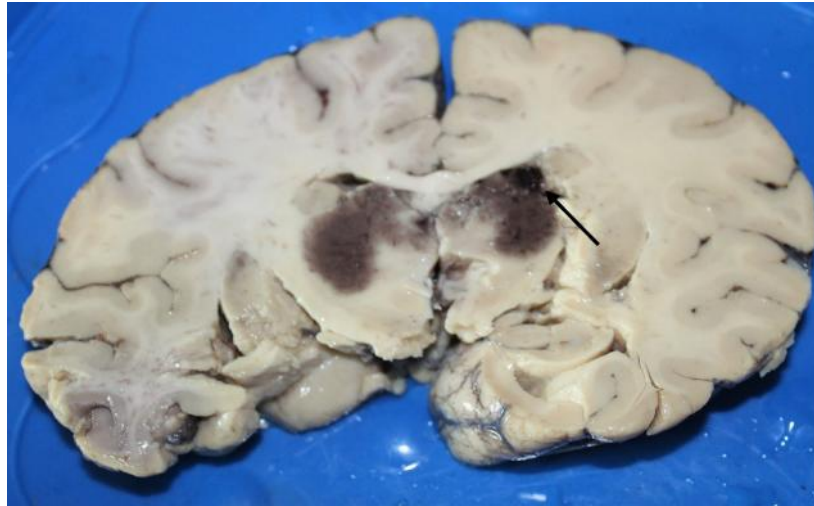


Fig. 1: Coronal section of the cerebral hemispheres showing bilateral ganglionic haemorrhage with haematoma on the right caudate nuclei (arrow).

no facioparesis. There was thrombocytopenia with platelet count of 85,000/mm³, INR was elevated with a value of 3.5 and Prothrombin time was deranged and the value was 41 seconds. The blood culture did not yield any growth. Her GCS dropped to 6 within two hours of admission, she had two episodes of tonic convulsions and went into shock that was refractory despite intravenous boluses and adequate inotropic support. Nasogastric tube aspirate was bloody and blood stains were seen in her perineum.

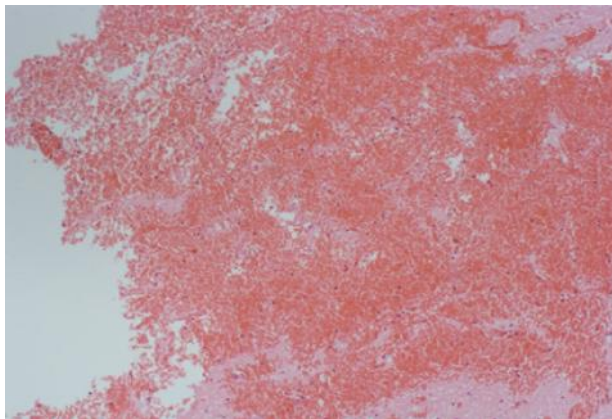


Fig. 2: Section showing haemorrhagic necrosis of cerebral tissue (H&E x 100).

She desaturated with SPO₂ of 65% while on 100% oxygen. Her GCS further dropped to 3 within fourteen hours of admission. She was managed with intravenous antibiotics, fluids, steroids and anti-malarial. Cranial imaging was not done prior to her death. She spent a total of seventeen hours on admission before demise, although there was no growth on blood culture and a lumbar puncture was deferred, she was managed as a possible case of meningococcaemia.

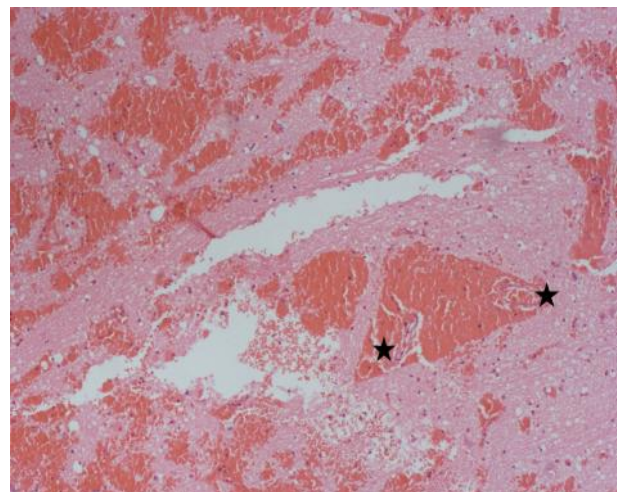


Fig. 3: Section showing multifocal haemorrhagic necrosis, small vessels thrombi and bleeding into the Virchow Robbin perivascular space. (H&E x 100).

At autopsy, there was a linear ecchymosis on the arm. Ecchymosis was also seen on the right ventricular wall. There was mesenteric and splenic haematoma with haemorrhagic gastropathy. The lungs were markedly congested and show features of diffuse alveoli damage with microthrombi. The histology of the kidneys shows extensive tubular necrosis and both adrenal glands show haemorrhagic infarctions. The brain was heavy and weighed 1600g (1150-1250g) with greyish-white exudates over the convexities of the parietal lobes and superior cerebellar hemispheres there were no frank pus seen. Coronal sections of the cerebral hemispheres showed bilateral basal ganglia haemorrhages affecting both lenticular nuclei and sparing the caudate (Fig 1). Histology of the brain sections show haemorrhagic infarction of the basal ganglia with associated microthrombi (Fig. 2 and 3).

The patient had no features of hypertension and the vessels only show mild fatty streaks of the abdominal aorta.

DISCUSSION

Intravascular coagulation is a common complication of bacterial meningitis and it is associated with a poorer prognosis^{16,17}. Streptococcus pneumonia, Neisseria meningitidis, Haemophilus influenza and Staphylococcus aureus have been associated with cases of DIC^{4,7,16}. Streptococcus pneumonia has also been reported to cause necrosis of bilateral basal ganglia following meningoencephalitis in a 4 month old baby complicated by vasculitis¹³. This current case was seen in an older child, with bilateral haemorrhagic necrosis of the basal ganglia that was caused by disseminated intravascular coagulation with consumptive coagulopathy. The coagulation profile done was deranged with thrombocytopenia and elevated prothrombin time, these findings support consumptive coagulopathy. Blood culture yielded no growth and molecular analysis for microbial organisms could not be done.

Vasculopathy results when endothelial cells of vessels are exposed to bacterial toxins and inflammatory cytokines. This then activates both the intrinsic and extrinsic pathways of coagulation leading to DIC¹⁸. The large arteries at the base of the brain to the small intimate pial and intraparenchymatous arteries as well as cortical veins can be involved by this process in meningitis¹⁷. In a study by Katchanov *et al*, streptococcus pneumonia was the most common cause of cerebral infarct and patients still develop this complication even while on antibiotics⁴. Cerebral vasculopathy can be predicted by altered level of consciousness with reduced CSF white blood cells⁴. The index case had altered level of consciousness while she was on empiric antibiotics. She did not have a lumbar puncture and CSF analysis could not be done that would have predicted the onset vasculopathy. Unlike the index case, most reported cases of vasculopathy affecting the basal ganglia in meningitis are due to infarctive necrosis^{13,19,20}.

Haemorrhagic stroke occurring in meningitis is rare and has been postulated to result from aneurysms that results from inflammation of vessels, the haemorrhages could be subarachnoid or intraparenchymal¹.

Most reported cases of vasculopathy were seen in patients with longer clinical history of the disease but has also been observed in a case of fulminant pneumococcal meningitis^{12,19,20}. Such was this index case that died within 24 hours of presentation to the hospital. She had refractory shock which may have resulted from septic shock and the haemorrhagic necrosis of the

adrenals. The sharp drop of the Glasgow coma score within hours of presentation was possible due to the ganglionic haemorrhage that further worsened the prognosis of a patient who already had acute lung injury, adrenal haemorrhage and was in refractory shock. Meningococcaemia is the most common cause of Waterhouse-Friedrichson syndrome but can also be seen in septic shock resulting from haemophilus influenza, staphylococcus and streptococcus pneumonia^{16,21,22}.

Increased vascular permeability and endothelial dysfunction within the lungs led to acute respiratory distress syndrome seen as diffuse alveolar damage during post mortem examination, which was responsible for the clinical signs of crepitations.

CONCLUSION

Haemorrhagic stroke is a rare event in vasculopathy complicating bacterial meningitis and portends worsening prognosis. Ischaemic necrosis is a more common event resulting from thrombi within the cerebral vasculature. Patients with fulminant meningitis with features of marked altered consciousness should have early imaging to rule out vascular events that may further complicate the disease condition.

REFERENCES

1. **Gironell A**, Domingo P, Mancebo J, *et al*. Hemorrhagic stroke as a complication of bacterial meningitis in adults: Report of three cases and review. Clin Infect Dis. 1995; 21(6): 1488–1491.
2. **Swartz MN**. Bacterial meningitis: more involved than just the meninges. N Engl J Med. 1984; 311(14):912–914.
3. **Saez-Llorens X**, McCracken Jr. GH. Bacterial meningitis in neonates and children. Infect Dis Clin North Am. 1990;4(4):623–644.
4. **Katchanov J**, Heuschmann PU, Endres M, Weber JR. Cerebral infarction in bacterial meningitis: Predictive factors and outcome. J Neurol. 2010;257(5):716–720.
5. **Matsumoto A**, Mino S, Nishiyama T. Intracranial hemorrhage caused by bacterial meningitis: Case report and review of the literature. Asian J Neurosurg. 2019;14(1):234.
6. **Julayanont P**, Ruthirago D, DeToledo JC. Bacterial meningitis and neurological complications in adults. southwest Respir Crit care chronicles. 2016; 4(14): 5–16.
7. **Saez-Llorens X**, McCracken jr GH. Bacterial meningitis in children. Lancet. 2003; 361(9375): 2139–2148.
8. **Love S**, Perry A, Ironside J, Budka H. Greenfield's Neuropathology - Two Volume Set. CRC Press; 2018. 1192–1223.

9. **Dale AP**, Read RC. Genetic susceptibility to meningococcal infection. *Expert Rev Anti Infect Ther.* 2013;11(2):187–199.
10. **Lundbo LF**, Harboe ZB, Clausen LN, *et al.* Genetic Variation in NFKBIE is Associated With Increased Risk of Pneumococcal Meningitis in Children. *EBioMedicine.* 2016;3:93–99.
11. **Sanders MS**, van Well GTJ, Ouburg S, *et al.* Genetic variation of innate immune response genes in invasive pneumococcal and meningococcal disease applied to the pathogenesis of meningitis. *Genes Immun.* 2011;12(5):321–334.
12. **Zou H**, Pan KH, Pan HY, *et al.* Cerebral hemorrhage due to tuberculosis meningitis: a rare case report and literature review. *Oncotarget.* 2015;6(42).
13. **Magnus J**, Parizel PM, Ceulemans B, *et al.* Streptococcus pneumoniae meningoencephalitis with bilateral basal ganglia necrosis: An unusual complication due to vasculitis. *J Child Neurol.* 2011;26(11):1438–1443.
14. **Siddiqui B**, Chevenon M, Nandi M, *et al.* The first documented case of hemorrhagic stroke caused by Group B streptococcal meningitis. *IDCases.* 2015;2(4):118–119.
15. **Gupta R**, Maraiyesa T, Conry B. Bilateral haemorrhagic basal ganglia infarction associated with early-onset group B streptococcus meningitis. *BMJ Case Rep.* 2018;2018:bcr-2017-223085.
16. **Kowalik MM**, Smiatacz T, Hlebowicz M, *et al.* Coagulation, coma, and outcome in bacterial meningitis - An observational study of 38 adult cases. *J Infect.* 2007;55(2):141–148.
17. **Pfister HW**, Borasio GD, Dirnagl U, *et al.* Cerebrovascular complications of bacterial meningitis in adults. *Neurology.* 1992;42(8):1497–1504.
18. **Van Deuren M**, Brandtzaeg P, Van Der Meer JWM. Update on meningococcal disease with emphasis on pathogenesis and clinical management. *Clin Microbiol Rev.* 2000;13(1):144–66.
19. **Johkura K**, Nishiyama T, Kuriowa Y. Bilateral basal ganglia infarctions in a patient with Streptococcus pneumoniae meningitis. *Eur Neurol.* 2002;48(2):123.
20. **Vernino S**, Wijdicks EFM, McGough PF. Coma in fulminant pneumococcal meningitis: New MRI observations. *Neurology.* 1998;51(4):1200–1202.
21. **Koogler TK**, Arangelovich V, Humilier M, *et al.* Staphylococcus aureus sepsis and the Waterhouse-Friderichsen syndrome in children. *N Engl J Med.* 2005;353(12):1245–1251.
22. **Hamilton D**, Harris MD, Foweraker J, Gresham GA. Waterhouse-Friderichsen syndrome as a result of non-meningococcal infection. *J Clin Pathol.* 2004;57(2):208–209.