

HISTOMORPHOLOGICAL PATTERN OF UROLOGIC MALIGNANCIES IN ILE-IFE, SOUTH-WESTERN NIGERIA

M.C Igbokwe¹, T.A Badmus¹, A.A Salako¹, A.O Komolafe², R.A David³, O.Z Omoyiola², A Laoye³,
I.A Akinbola³, C.I. Onyeze³ and R.N Babalola³

1. Department of Surgery, Obafemi Awolowo University, Ile-Ife/Urology Unit, Obafemi Awolowo University Teaching Hospitals Complex, Ile-Ife, Nigeria.
2. Department of Histopathology and Forensic Medicine, Obafemi Awolowo University Teaching Hospitals Complex, Ile-Ife, Nigeria.
3. Urology Unit, Obafemi Awolowo University Teaching Hospitals Complex, Ile-Ife, Nigeria.

Correspondence:

Dr. M.C. Igbokwe

Department of Surgery,
Obafemi Awolowo University, Ile-Ife/
Urology Unit, Obafemi Awolowo University
Teaching Hospitals Complex, Ile-Ife,
Nigeria
Email: martini4life@yahoo.com

ABSTRACT

Introduction: The last decade witnessed a remarkable rise in the prevalence of several malignant diseases in Nigeria. Whether Urologic malignancies (UM) have followed the same trend remains to be studied. The pattern of UM diagnosed in a Nigerian tertiary hospital is hereby presented. Our aim was to determine the pattern and prevalence of histologically diagnosed UM in Obafemi Awolowo University Teaching Hospitals Complex, Ile-Ife, Nigeria.

Materials and Methods: A 10-year retrospective review of all patients diagnosed with UM was carried out between January 2005 and December 2014. Data was obtained from the patients' case files and the Ife-Ijesha Cancer registry. Information obtained included demographic characteristics, site of origin and histology. Data was analysed with Statistical package for Social sciences (SPSS) Version 20.

Results: A total of 4675 malignancies were histologically confirmed during the study period. UM accounted for 420 (8.9%) of total malignancies. Prostate cancer was the commonest UM with 315 (75%) cases. Others include renal tumours 62(14.8%), bladder tumours 29 (6.9%), testicular tumours 13(3.1%) and scrotal tumour 1(0.2%). UM were commoner in males (348, 88.8%) than females (47, 11.2%) and accounted for 13.8% and 2.18% of all tumours in males and females respectively.

Conclusion: This study revealed a rising prevalence of UM most especially Prostate and Renal Cancers among other malignancies in Ile-Ife.

Keywords: Pattern, Urologic malignancies, Ile-Ife.

INTRODUCTION

Urologic malignancies (UM) are encountered worldwide with varying patterns and prevalence¹. UM are major causes of morbidity and mortality with a significant effect on age-adjusted life years in afflicted individuals². Technological advancement in diagnostic modalities, minimal access surgery and modern drugs have changed the face of diagnosis and treatment of UM². Nigeria, the most populous black nation in the world has witnessed an increasing burden of UM in the past decade especially Prostate cancer (PCa)^{3,4}.

Reports from tertiary centres in different geo-political zones of Nigeria have shown some epidemiological peculiarities in the pattern of UM with higher reports

of bladder cancer in the Northern part of Nigeria⁵. In the oil-rich Southern Nigeria, certain genetic predisposing factors and environmental exposure have been alluded to in the aetio-pathogenesis of some UM^{6,7}.

From previous studies, UM account for a significant burden of cancer patients in Nigeria. Prostate and bladder cancer have been shown to be the commonest malignancies across Nigeria in papers from South-south and North-western Nigeria respectively^{5,8}. There is however paucity of information on the recent pattern of UM in South-western Nigeria.

This study aims to analyse the pattern of GUM diagnosed at the Ife-Ijesha cancer registry over a 10-year period.

MATERIALS AND METHODS

A 10-year retrospective review of all patients with histological diagnosis of GUM between January 2005 and December 2014 at Obafemi Awolowo University Teaching Hospitals Complex, Ile-Ife was done. Data was obtained from the patients case files and the Ife-Ijesha Cancer registry. Information obtained include demographic characteristics, site of origin and histologic details. The diagnosis was based on the World Health Organization's classification of varied urological cancers. Data was analysed with Statistical package for Social Sciences (SPSS) Version 20.

RESULTS

UM accounted for 8.9% (420 of 4675) of malignancies diagnosed within the study period. Of all malignancies diagnosed and registered in the cancer registry, there was a marginal male predominance with male cancers numbering 2517 (53.8%) and female cancers 2158 (46.2%). Overall, UM made up 14.82%

of male malignancies and 2.18% of female malignancies. UM were commoner in males 373 (88.8%) than females 47 (11.2%) with a male:female ratio of 9 : 1. The mean age of patients with UM were 53.5 years. Mean ages for different urologic tumours are depicted on Table 1.

The primary organs affected were the Prostate (315;75%), the kidney (62;14.8%), the bladder (29;6.9%), the testis (13;3.1%) and the scrotum (1;0.24%).

The peak age for prostate cancer was in the 7th decade of life with histology of Adenocarcinoma accounting for all. Renal Cell Carcinoma was the second commonest malignancy and was seen more commonly in females (37; 59.7%) than males (25; 41.3%) with the clear cell variant making up greater than one third of the patients. Bladder tumours ranked third and were more commonly found in men (19;65.6%) than women (10;34.4%) with transitional cell carcinoma variant making up more than half of the cases. Other histological details are as seen on Table 2. Testicular tumours and a solitary case of scrotal squamous cell

Table 1: Summary of genito-urinary malignancies in Ile-Ife (From Ife-Ijesha Cancer Registry).

Tumours	Total (% of total Malignancies)	% of Adult Urologic Malignancies	Mean Age (years)
Prostate Cancer	315 (6.74)	75	69.80
Renal Cancer	62 (1.33)	14.76	41.70
Bladder Cancer	29 (0.62)	6.90	63.60
Testicular Cancer	13 (0.28)	3.10	30.60
Scrotal Cancer	1 (0.022)	0.24	62.00
Total	420 (8.98)	100	

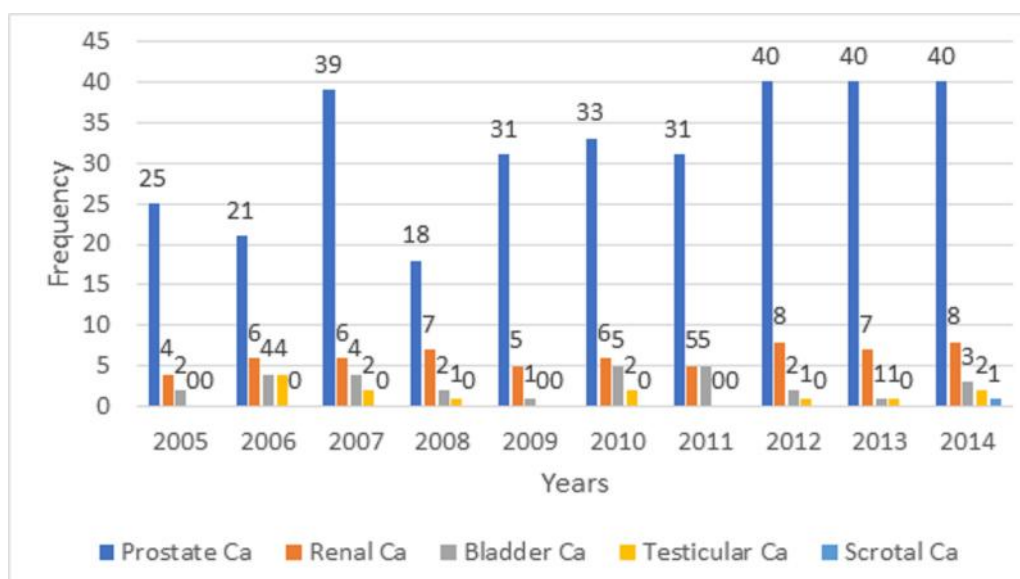


Figure 1 : Distribution of Genito-urinary tract malignancies in Ile-Ife between 2005 and 2014

Table 2: Histopathological breakdown of GUM in Ile-Ife.

Tumours	Histological details	Frequency (%)
Prostate Cancer	Adenocarcinoma	315 (100)
	High grade PIN	7
Bladder Cancer	Transitional Cell Carcinoma	16 (55.2)
	Squamous Cell Ca	6 (20.7)
	Adenocarcinoma	4 (13.8)
	Metastatic Cancers	3 (10.3)
Renal Cancer	Renal Cell Carcinoma	37 (59.7)
	Clear Cell RCC	11 (17.7)
	Chromophobe	7 (11.3)
	Papillary	3 (4.8)
	Sarcomatoid	1 (1.6)
	Mixed	1 (1.6)
	Multi-locular Cystic	1 (1.6)
	Collecting Duct	1 (1.6)
Testicular Cancer	GCT	5 (38.4)
	Seminoma	4 (30.8)
	Paratesticular tumours	2 (15.4)
	Rhabdomyosarcoma	1 (7.7)
	Adenomatoid tumour	1 (7.7)
Scrotal Cancer	Squamous Cell Carcinoma	1 (100)

carcinoma accounted for the rest. No cases of renal pelvis, ureteral, urethral or penile tumours were managed during the study period.

DISCUSSION

This review shows that over the last decade, UM accounted for 8.4% of all histologically diagnosed malignancies in our immediate community. This suggests that 1 in every 10 cases of cancer is a UM. This was similar to findings in Jos, Korle-Bu and Zambia⁹⁻¹¹. It was however less prevalent than in studies from Kano and India^{2, 8}. Compared to the year 2005, the 60% rise in overall prevalence of UM from 2011-2014 are mostly attributable to Prostate and Renal Cancers. This could be attributed to more recent community-based health education and screening programs in Ile-Ife community associated with higher number of apparently healthy patients presenting for routine prostate specific antigen checks, ultrasound scans and prostate biopsies. There has also been a rise in incidental diagnosis of renal tumours during routine ultrasound scans in Ile-Ife in recent times¹². Dauda and his associates also corroborated a rise in the prevalence of UM in North-eastern Nigeria¹³.

Historically, it was believed that PCa was relatively rare among men of African descent¹⁴, our study contrarily buttresses the high prevalence of PCa in our environment accounting for 75% of all UM. There is overwhelming evidence in literature that PCa is the commonest UM^{3, 8, 9, 13, 15, 16}. In Nigeria, PCa has surpassed

Hepatocellular carcinoma as the commonest malignancy in men³. Adenocarcinoma was the dominant histological type of PCa in our study which is similar to other local and international reports^{1, 8}.

Findings of renal cell carcinoma (RCC) as the second commonest urological cancer in this study is contrary to majority of studies from across Nigeria where bladder tumour has since been reported as the second commonest UM^{5, 8, 9, 13}. Perhaps the relative rural environment devoid of exposure to industrial carcinogens as well as paucity of schistosoma endemic streams may account for this peculiarity.

This study shows that the mean age for RCC was 41.7 years and it was found to be more common among women with Male: Female ratio of 1: 1.5. The lower mean age and increased prevalence among women was a sharp contrast to a previous report from our center where a mean age of 47.5 years and male: female ratio of 13:5¹⁷. In Nigeria, Tijani and Mbaeri *et al* in Lagos and Nnewi respectively, also found a higher incidence of RCC in females^{18, 19}. Reasons for these differences were attributed to the increased number of women with incidentally discovered RCC during routine ultrasound in pregnancy. The clear cell variant was the commonest histological type in this study, this was different from the papillary cell variant which was reported by Ofuru and his associates reported in Port-Harcourt, Nigeria⁵.

Bladder tumours were the third commonest urological malignancy in our study with male:female ratio of 2:1. This ratio was similar to findings by Forae in Benin and Takure *et al* in Ibadan, both in Nigeria^{20,21} however males were observed to have a much higher ratio of 5.6: 1 in Port-Harcourt⁵. Urothelial tumour (transitional cell carcinoma) was the commonest histological type found in our report. This is in keeping with the global trends². Even in the Northern part of Nigeria, there seems to be a change in the trend of bladder tumours with higher incidence of urothelial tumours compared to Squamous cell Carcinoma as was seen two decades ago due to endemicity of schistosomiasis in these parts^{9, 22}. We generally believe that the semi-urban setting of our immediate environment with a paucity of chemical industries and schistosoma infested streams may have accounted for a lower prevalence of bladder tumours. Testicular tumours were found to be rare with no change in prevalence over the 10-year period under review and it accounted for 3.1% of all urologic malignancies. This is slightly higher than 0.5-2% which is quoted worldwide as incidence of testicular cancer^{8, 23, 24}.

Germ cell tumours (GCT) accounted for 38.4% and were the commonest histologic sub-type in this study. This was similar to findings from previous local and international studies^{23, 25}. Paratesticular tumours especially rhabdomyosarcoma still appear to be relatively common in our community accounting for about half of the patients. This corroborates the report from Salako *et al*, in 2010 in our hospital who found paratesticular tumours accounting for 38.5% of testicular tumours with majority being rhabdomyosarcoma²⁶. There was solitary case of scrotal squamous cell carcinoma which is a rare disease²⁷.

CONCLUSION

There is an obvious increase in the prevalence of UM in Ile-Ife, mostly accounted for by Prostate and Renal Cancers. This is possibly attributable to increased health education and awareness among indigenes. Renal cancer seems to have replaced bladder cancer as the second commonest UM in Nigeria. There is need for a larger scale National study in order to identify the true pattern of urologic malignancies in Nigeria.

ACKNOWLEDGEMENT

We would like to acknowledge the members of the Urology and Histopathology Departments of the Obafemi Awolowo University Teaching Hospitals Complex, Ile-Ife, Nigeria for the support in completing this review.

REFERENCES

1. **Smita Chandra**, Harish Chandra, Dushyant Singh Gaur. Male Genitourinary Tumors: 14 Years Experience in Garhwal Region of India. Indian Medical Gazette. 2014.
2. **Yuvaraja TB**, Waigankar S, Bakshi G, Prakash G. Genitourinary cancers: Summary of Indian data. South Asian Journal of Cancer. 2016;5(3):122-124.
3. **Ogunbiyi JO**, Shittu OB. Increased Incidence of Prostate Cancer in Nigeria. Journal of National Medical Association. 1999;91:159-164.
4. **Mohammed AZ**, Nwana EJC, Anjorin AS. Histological pattern of prostatic diseases in Nigerians. African Journal of Urology. 2005; 11(1): 33-38.
5. **Ofuru V.**, Ekeke N., Obiorah C. Genitourinary malignancies in Port Harcourt, Nigeria. Port Harcourt Medical Journal. 2017;11(1):10-14.
6. **Hsing AW**, Tsao L, Devesa SS. International trends and patterns of prostate cancer incidence and mortality. Int J Cancer 2010; 2002;85:60-67.
7. **Ferlay J**, Shin HR, Bray F, *et al*. Estimates of worldwide burden of cancer in 2008: GLOBOCAN 2008. Int J Cancer 2010; 2008;127: 2893-2917.
8. **Abubakar Abdulkadir**, Sule A. Alhaji, Haruna M. Sanusi. Pattern of urological cancers in Kano: North-western Nigeria. Sub-Saharan African Journal of Medicine. 2016;3(4):182-187.
9. **Mandong BM**, Iya D, Obekpa P.O, Orkar K. Urological Tumours in Jos University Teaching Hospital, Jos, Nigeria (A Hospital-Based Histopathological Study). The Nigerian Journal of Surgical Research. 2000;2(3):108-113.
10. **Klufio GO**. A review of genitourinary cancers at the Korle-Bu teaching hospital Accra, Ghana. West Afr J Med. 2004;23(2):131-134.
11. **Elem B**, Patil PS, Pattern of Urological Malignancy in Zambia A Hospital-based Histopathological Study. BJU International. 1991;67(1):37-39.
12. **Salako AA**, Badmus TA, Badmos KB, *et al*. Renal cell carcinoma in a semi-urban population of south-western Nigeria. East African Medical Journal. 2017;94(1):37-43.
13. **Dauda MA**, Misauno MA, Ojo EO, Nnadozie U.U. Pattern of urological malignancies seen at Federal Medical Centre Gombe North Eastern Nigeria. Nigerian Journal of Medicine : Journal of the National Association of Resident Doctors of Nigeria. 2012;21(2):237-240.
14. **Osegbe DN**. Prostate cancer in Nigerians: Facts and Nonfacts. J Urol. 1997;157:1340-1343.
15. **Ekwere PD**, Egbe SN. The changing pattern of prostate cancer in Nigerians: Current status in the South-eastern states. J Natl Med Assoc. 2002;94: 619-627.

16. **McDavid K**, Lee J, Fulton JP. Prostate cancer incidence and mortality rates and trends in the United States and Canada. *Public Health Rep.* 2004;119:174-186.
17. **Badmus TA**, Salako AB, Arogundade FA., *et al.* Malignant Renal Tumors in Adults: A Ten-Year Review in a Nigerian Hospital. *Saudi Journal of Kidney Diseases and Transplantation* 2008;19(1): 120-126.
18. **Tijani KH**, Anunobi CC., Ezenwa EV, *et al.* Adult renal cell carcinoma in Lagos: Experience and challenges at the Lagos University Teaching Hospital. *African Journal of Urology.* 2012 18(1):20-23.
19. **Mbaeri TU**, Orakwe JC, Nwofor AM, *et al.* Malignant renal tumours in adults in Nnamdi Azikiwe University Teaching Hospital, Nnewi, Nigeria. *Niger J Med.* 2012;21(4):377-80. Epub 2013/01/12.
20. **Forae G**, Ugiagbe E, Mekoma D. A descriptive study of bladder tumors in Benin City, Nigeria: An analysis of histopathological patterns. *Saudi Surgical Journal.* 2016;4(3):113-117.
21. **Takure AO**. Odubanjo MO., Adebayo SA, *et al.* Histopathologic Pattern Of Bladder Cancers In Ibadan Southwest Nigeria: An Update *J West Afr Coll Surg.* 2015;5(2):17-42.
22. **Ochicha O.**, Alhassan S., Mohammed A.Z., *et al.* Bladder cancer in Kano - A histopathological review. *West African Journal of Medicine.* 2003;22(3):202-204.
23. **Moller H.** Trends in incidence of testicular cancer and prostate cancer in Denmark. *Hum Reprod.* 2001;16:1007-1011.
24. **Carlsen E**, Giwercman A, Keiding N, Skakkeback NE. Evidence for decreasing quality of semen during the past 50 years. *Br Med J.* 1992; 305:609-612.
25. **Magoha GA.** Testicular cancer in Nigerians. *East African medical journal.* 1995;72(9):554-556. Epub 1995/09/01.
26. **Salako A.A.**, Onakpoya U.U., Osasan S.A., Omoniyi-Esan G.O. Testicular and para-testicular tumors in south western Nigeria. *Afr Health Sci.* 2010;10(1):14-17.
27. **Azike J.E**, Chukwujama N.O, Oguike T.C. Squamous cell carcinoma of the scrotum in a Nigerian: Case report. *Rare Tumors.* 2009;1(1):e2.