

NECROTURIA WITH ACUTE URINARY RETENTION: A RARE PRESENTATION OF BILATERAL WILMS' TUMOUR

T.T. Ibiyeye¹, A.A. Abolarinwa² and R.I. Osuji²

1. Department of Surgery, Federal Medical Center, Lokoja, Kogi State, Nigeria.
2. Department of Surgery, College of Medicine, Lagos State University, Ikeja, Lagos State, Nigeria.

Correspondence:

Dr. A.A. Abolarinwa
College of Medicine,
Lagos State University,
Ikeja, Lagos State,
Nigeria
Email: docbeebee@yahoo.com

ABSTRACT

Background: Wilms' tumour is one of the most common solid abdominal tumours in children in sub-Saharan Africa. Most cases present with an asymptomatic abdominal mass. We report a 2 year old male child who presented with acute urinary retention of 6 hours duration. He had a left flank mass and ascites, with a piece of necrotic tissue protruding from the urethral meatus. The urinary retention was relieved by manual removal of the necrotic tissue and passage of a Foley's urethral catheter. Abdominal ultrasound and computed tomographic scan revealed bilateral Wilms' tumour. The child commenced neoadjuvant chemotherapy and he has made significant improvement.

Conclusion: This is a rare mode of presentation of bilateral Wilms' tumour which presented with a diagnostic dilemma. The need to palpate the abdomen of children who come to the hospital, cannot be over-emphasized.

Key words: Bilateral Wilms', Tumour; Necroturia, Acute urinary retention.

INTRODUCTION

Wilms' tumour is the most common solid abdominal tumour in children in sub-Saharan Africa.^{1,2,3} It accounts for 6% of malignancy in children in USA,^{4,5} and is seen frequently in children less than 5 years,⁴ with 90% of Wilms' tumour diagnosed before the age of 7.^{1,5} The peak incidence is between the ages of 2-5.⁴ Most patients present with an asymptomatic abdominal mass.^{1,5} Other modes of presentation may include hematuria, fever, weight loss, and abdominal pain.^{1,5} Presentation may however be unusual like this index case, requiring a high index of suspicion for diagnosis. To our knowledge, there is no previous reported case of this nature.

CASE PROFILE

A 2 year old male child was referred to our facility on account of inability to pass urine of 6 hours duration with associated straining, painful abdominal swelling, and protrusion of a fleshy mass from the urethral meatus, which became more prominent with straining. There was no history of abdominal or perineal trauma, no history of insertion of a foreign body into the urethra, no previous history of hematuria and fever. The child however had a 3 months history of progressive abdominal distention.

Examination revealed a male child in obvious distress. A 4cm long, fleshy necrotic mass was seen protruding through the urethral meatus, with bleeding from the tip of the mass (Fig. 1)

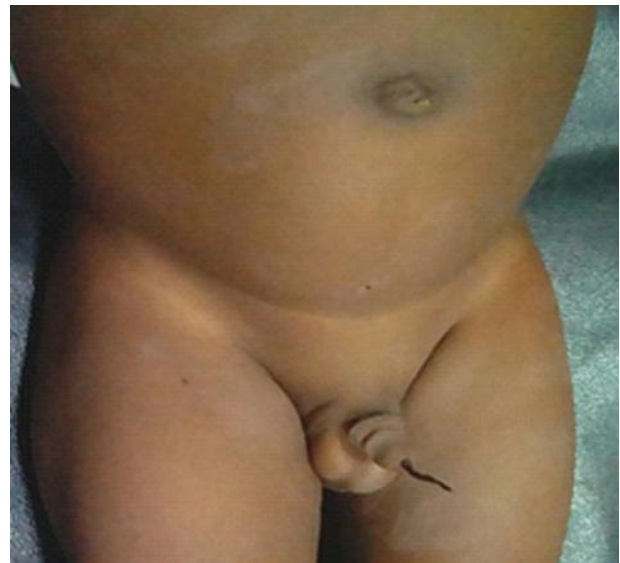

Fig. 1: The necrotic tissue protruding through the urethral meatus

The abdomen was distended with a tender suprapubic swelling. There was a palpable mass in the left flank which was firm, non tender, not ballotable and did not cross the midline. There was ascites.

The fleshy material was manually extracted and sent for histology. (Fig. 2)

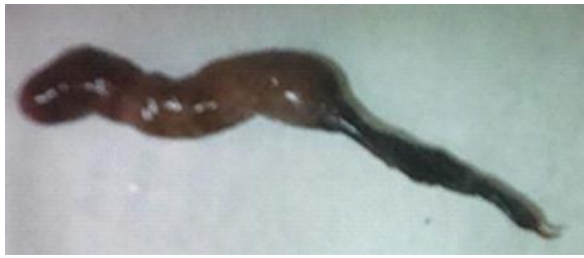

Fig. 2: The necrotic tissue after extraction

The child was catheterized, and 250mls of clear urine was drained. Laboratory investigations revealed a packed cell volume of 20% and microscopic hematuria. His renal function tests were normal. He had an abdominal ultrasound scan which showed bilateral solid renal masses with a dilated right pelvi-

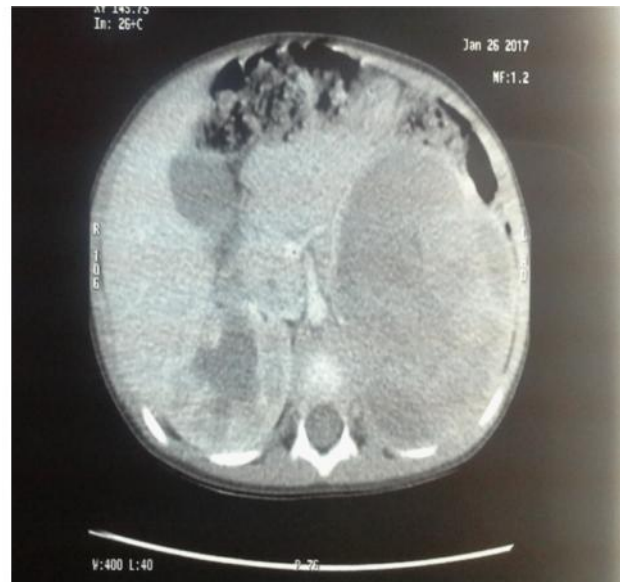
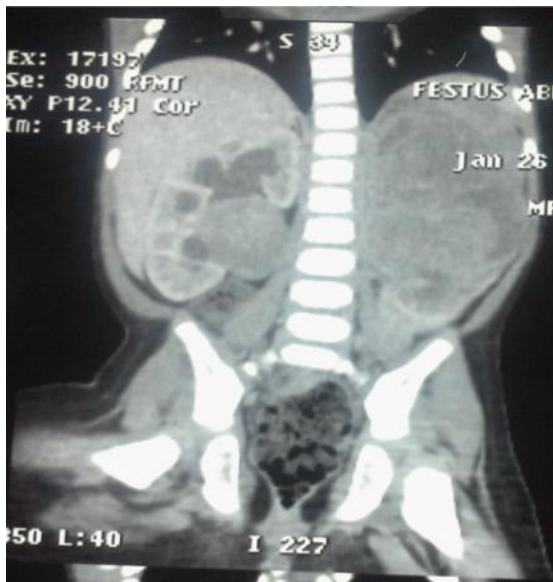

Fig. 3A and 3B: A coronal reformat and axial image of the abdominal CT scan before neoadjuvant chemotherapy

calyceal system. An abdominal CT scan showed bilateral renal masses compressing the adjacent small bowel and colon, a right intra-pelvic tumour with moderate hydrocalycosis (Fig. 3)

The histology of the extracted tissue was confirmed to be necrosis. His chest x-ray result was normal.

A clinical diagnosis of bilateral Wilms' tumour was made. He commenced neo-adjuvant chemotherapy using the SIOP protocol for the management of nephroblastoma. A significant response was noted following the commencement of chemotherapy as there was resolution of the ascites and a clinical reduction in the size of the mass, which became barely palpable after the first course was given.

DISCUSSION

Wilms' tumour also known as Nephroblastoma, is the most common abdominal tumour in children in the Sub-Saharan Africa.^{1,2,3} Wilms' tumour is mostly unilateral,⁶ however, bilateral Wilms' tumours are seen in about 5-7% of patients. This can be synchronous or metachronous.⁷ Olukayode *et al*,¹ reported an incidence of 25% bilateral Nephroblastoma on CT scan evaluation of 12 patients presenting with abdominal distention at Lagos University Teaching Hospital, all occurring in boys.

In the developed world, the diagnosis is usually made early, hence their better prognosis. However, this is not so in our environment.³ An asymptomatic abdominal mass is the most common presentation, noticed while bathing the baby or during a routine

abdominal examination by a pediatrician.¹ Patients may however present with fever, abdominal pain, malaise and anemia.^{1,5} Osuoji *et al*,³ in a retrospective review of 35 patients, reported all 35 patients presented late with abdominal masses, and other symptoms including hematuria, fever, weight loss, varicocele, cough and pleural effusion.

Macroscopic hematuria is not common in a typical Wilms' tumour.⁸ This is however a frequent presentation in intra-pelvic Wilms' tumour or when the tumour has broken into the renal pelvis.⁹ These group of tumours may present in ways that are different from the classical Wilms' tumour.⁹ Our patient's presentation was quite unusual, the necroturia may have been from the right intra-pelvic tumour.

No report was found on necroturia and acute urinary retention in Wilms' in our literature search. However, reports of intra-pelvic Wilms' were noted to present with mostly hematuria.^{8,9} Although we did not do a cystoscopy, we strongly believe that the necrotic tissue was from either of the renal masses.

The management of bilateral Nephroblastoma can be challenging. However, a significant reduction in the size of the tumour usually occurs with the use of pre-operative chemotherapy, making renal salvage surgery feasible.⁷ We were able to shrink both tumours with neo-adjuvant chemotherapy. Subsequent treatment plan shall depend on the stage of residual tumours in the kidneys on follow-up evaluation.

CONCLUSION

The need for abdominal examination in a child who presents with urinary symptoms cannot be overemphasized.

REFERENCES

1. **Olukayode AA**, Osuoji R, Akinola R, *et al.* Pattern of computed tomography scan findings in children with Wilms' tumor in a tertiary hospital in Lagos, Nigeria. *Indian J Med Paediatr Oncol.* 2014;35:31-35.
2. **Wabada S**, Abubakar A, Adamu A, KABir A, IB G. Case Report A Retroperitoneal Extra-Renal Wilms' Tumour/ : A Case Report. *Niger J Clin Pract.* 2017;20:388–391.
3. **Osuoji R**, Williams O, Ajai O, *et al.* Wilms' Tumour: Experience in a Developing Tertiary Center in Nigeria. *East Cent Afr J surg.* 2011;16:51–57.
4. **Nguyen SN.** A Case Report of Wilms' Tumor. *J Rare Dis Diagn Ther.* 2016;2:3–5.
5. **Yarboro TL.** Atypical presentation of Wilms' tumor: Evaluation and early diagnosis. *J Natl Med Assoc.* 1969; 90:51–53.
6. **Senthilnathan R**, Bagdu R, Senthilganesh K, Senthilbarathi C. Interesting Presentation of Wilms' Tumour. *J Indian Assoc Pediatr Surg.* 2004; 9:193–197.
7. **Özyörük D**, Emir S. The management of bilateral Wilms tumor. *Transl Pediatr.* 2014;3:34–38.
8. **Nakachi S**, Matsumoto H, Nakazato I, Yoshimi N. Botryoid Wilms tumor of the renal pelvis: A case report. *Hum Pathol Case Reports. The Authors;* 2017;9:10–12.
9. **Yang SO**, Joung Y, Han KS, *et al.* Adult's Wilms' Tumor Mimicking Renal Pelvis Tumor. *Korean J.* 2007;48:558–560.