

TERATOMA IN A TERTIARY HOSPITAL IN SOUTH-EAST NIGERIA: A FIFTEEN-YEAR RETROSPECTIVE STUDY AT FETHA, ABAKALIKI, EBONYI STATE

F. Edegbé¹, C.O. Okani², A.A. Obasi³ and P.O. Ezeonu⁴

1. Department of Histopathology, Federal Teaching Hospital, Abakaliki, Ebonyi State, Nigeria
2. Department of Histopathology, Chukwuemeka Odumegwu Ojukwu University, Awka Campus, Anambra State, Nigeria (Formerly, Anambra State University, Awka Campus.)
3. Department of Surgery, Federal Teaching Hospital, Abakaliki, Ebonyi State, Nigeria
4. Department of Obstetrics and Gynaecology, Federal Teaching Hospital, Abakaliki, Ebonyi State, Nigeria

Correspondence:

Dr. C.O. Okani

Department of Histopathology,
Chukwuemeka Odumegwu
Ojukwu University,
Awka Campus,
Anambra State,
Nigeria
Email: co.okani@coou.edu.ng

ABSTRACT

Any neoplastic growth within a tissue or an organ harboring components derived from more than one germ layer is called a teratoma. Teratoma may be monodermal or polydermal in origin and they can also be classified as mature or immature teratomas. In a retrospective study of teratomas histologically diagnosed in the Department of Pathology, Federal Teaching Hospital Abakaliki (FETHA), Ebonyi State, the entire specimens received at the Department for histological assessment over a fifteen-year period (2000-2014), was 6,548. However, only 28 (0.4%) of the entire specimens represented teratoma. Twenty five (89.3%) of the teratomas were females and only 3(10.7%) were males, giving a male to female gender ratio of 1:8.3. The most common site of occurrence was the ovary accounting for 18(64.3%) followed by the sacrococcyx representing 4(14.3%) cases. All the 28(100%) cases of teratomas were benign neoplasm (mature cystic teratomas) containing two or three germ cell layers with one of the cases noted as a giant teratoma. We observed an important bimodal age distributions; with a first peak occurring between 0-10 years (in the first decade of life) and a second peak (in the 3rd decade) between 20-30 years of age.

Keywords: Teratoma, Germ cells

INTRODUCTION

Teratomas refer to neoplasms composed of multiple tissues arising from the three germ layers foreign to the site in which they arise and are known as germ cell tumours. Germ cell tumours are diverse group of neoplasms that originate in the primordial germ cells of the yolk sac. These primordial germ cells are formed in the gonads and extragonadal sites during embryogenesis. There are migration anomalies in tissue differentiation, leading to development of one tumour cell that has full range of histogenetic tissue elements of ectoderm, mesoderm and endoderm¹. Teratomas occurrence is worldwide.²⁻⁵

Several publications on teratomas from Africa are available. Akang (Ibadan, South-West Nigeria) documented that teratomas occurred more in females with the ovary being the commonest site of involvement.² From outside Africa, Petr Havránek and co-workers, and Girwalkar-Bagle and co-workers have also noted that sacrococcyx is another common site of involvement in childhood teratoma.⁶⁻⁸ Several other researchers also documented teratomas involving the cervical⁹, gastric¹⁰ and renal¹¹ tissues. It is pertinent

to note that there is paucity of documentation on teratoma which have emanated from South-East Nigeria. This review, therefore, aims at establishing a hospital-based incidence and histopathological features of teratomas in Abakaliki, Ebonyi State, South-East Nigeria.

MATERIALS AND METHODS

Surgical specimens received at the Department of Pathology, Federal Teaching Hospital, Abakaliki, Ebonyi State, between January, 2000 and December, 2014 constituted the materials for the study. All the cases of teratoma diagnosed during the period under review were retrieved from the Histopathology Department's Surgical Daybook and from the requisition forms. The corresponding clinical data, gross descriptions of histopathologically diagnosed cases were extracted and carefully recorded. The H&E (haematoxylin and eosin) stained slides of each case were also retrieved for reconfirmation of the original diagnosis. If the slides were unavailable, new slides were produced from the archived formalin-fixed paraffin-embedded tissue blocks (FFPB).

The tumours were classified according to 2004 WHO classification¹². Cases in which the demographic data were absent and both the histology slides and blocks could not be retrieved were excluded from the study.

RESULTS

During the 15 year period of the study, a total number of 6,548 biopsy specimens were received at the department. Out of these, 28 cases were diagnosed as teratomas giving an overall frequency of 0.4%. The age range was 7 days to 53 years with a mean age of 2.3 years. Nine cases occurred in children and 19 cases involved adults. Fig. 1 shows the age-group and sex distribution of the patients with teratomas. Teratomas in this study displayed a bimodal age distribution with the first peak occurring in the first decade of life while the second occurred in the third decade of life. There



Fig. 2: Scale is in millimeter, Gross picture of the largest sacral mature cystic teratoma in a three-week old child measuring 30cm x 30cm x 10cm

Table 1: Site and sex distribution of 28 patients with teratomas seen at FETHA, Ebonyi.

ANATOMICAL SITE	MALE	FEMALE	TOTAL (%)
Ovary	-	18	18(64.3%)
Sacrococcyx	1	3	4 (14.3%)
Back	-	1	1 (3.6%)
Ear	1	-	1 (3.6%)
Fallopian tube	-	1	1(3.6%)
Penis	1	-	1(3.6%)
Supraorbit	-	1	1(3.6%)
Thyroid	-	1	1(3.6%)
TOTAL	3(10.7%)	25(89.3%)	28(100%)

were 25 (89.3%) females and 3 (10.7%) males giving a female to male ratio of 8.3:1 (Table 1). The sites (Fig. 3) of involvement of the teratomas include: ovary-18 (64.3%), sacrococcyx-4 (14.3%), back-1 (3.6%), ear-1 (3.6%), fallopian tube-1 (3.6%), penis-1 (3.6%), supraorbit-1 (3.6%), and thyroid gland-1 (3.6%). The sizes of the tumours ranged from 5cm x 4cm x 2cm to 20cm x 20cm x 5cm. Cut sections showed various sizes of cystic spaces containing variable tissue elements which include: tuft of black hair, fat, bony spicules, fleshy and fibrous tissue. The largest tumour is shown in fig. 2.

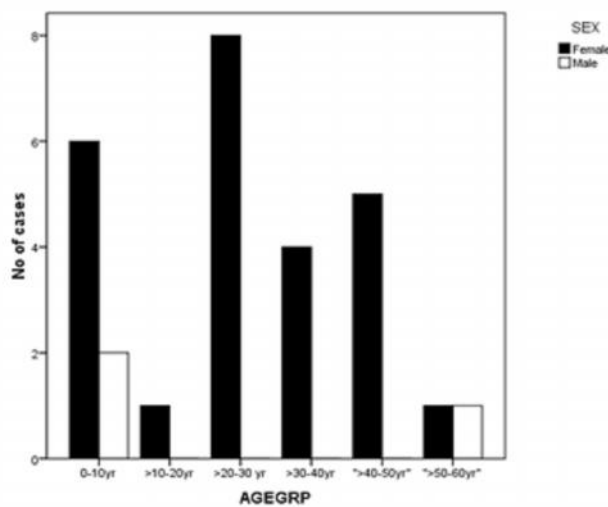


Fig. 1: Age and sex distribution of patients with teratomas

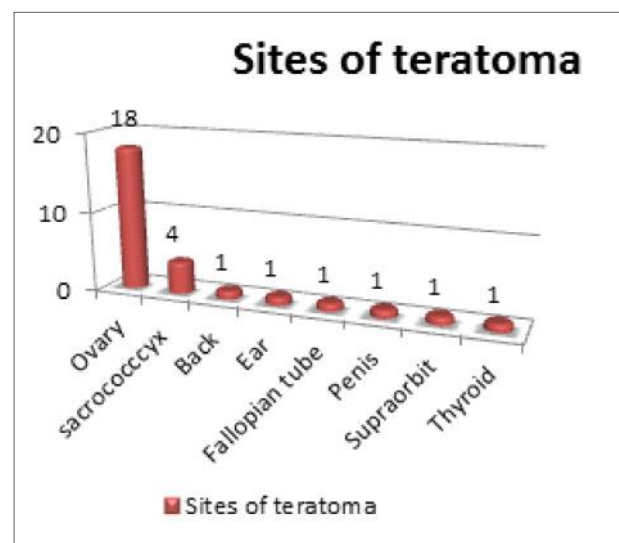


Fig. 3: Various sites of teratomas

All the slides for the 28 cases of teratoma were available for histopathological review. These neoplasms displayed various sizes of cysts and varying combination of ectodermal (skin with sweat glands, pilosebaceous units, glial tissue and uveal tissue), mesodermal (cartilage, bone, fat and smooth muscle) and endodermal (intestinal epithelium and respiratory epithelium) differentiation. The cases seen in this study were all mature teratomas. Immature teratomas were absent. Fig. 4 shows a photomicrograph of a mature cystic teratoma of the sacrum from a 7-year old female.

DISCUSSION

Teratomas accounted for 0.4% of the total surgical biopsies during the period in review. This is similar to the teratomas frequency of 3.4 per 1000 surgical biopsies² recorded by Akang at Ibadan, South-West Nigeria. Teratomas were more common in females 25(89.3%) than males 3(10.7%) with a female to male ratio of 8.3:1 and this finding is similar to that observed by some authors in both African and Caucasian countries.^{4,13,15} The commonest site of occurrence of teratoma in this study is the ovary which corresponds to other studies done in Nigeria and Europe.^{6,16,17} All of the gonadal teratomas in the present series were mature and all occurred in the ovary. This is unlike the findings in the series of ovarian childhood tumours reported by Junaid in South-West Nigeria¹⁸ where 86.4% of teratomas in children less than 15 years of age were mature and 13.6% were immature. There was no case of testicular teratoma in the present study, and this may not be unconnected to the relative small number of teratomas in this index case. However, paucity of testicular teratomas is in agreement with previous documentations which suggested that there is rarity of testicular germ cell neoplasms generally in blacks.¹⁹ In Nigerian²⁰ and Zimbabwean²¹, teratomas have been reported as an infrequent tumour of the testes. In a series of 35 childhood and adolescent tumours from Ibadan, Junaid¹⁸ observed only one teratoma in an under 5 year-age group and none in the older age groups.²² This contrasts with Caucasian study which reported testicular teratomas in up to 7% of teratomas.

However, Marsden and co-workers¹⁶ from Manchester, England, study was in contrast to this index study which showed all the teratomas as mature cystic teratomas (benign tumours). Marsden and co-workers¹⁶ documented that 88.4% of cases were benign, 8.1% malignant and 3.5% of uncertain malignant potential¹⁶. In another study of 45 childhood teratomas from South Africa, Bezuidenhout and co-workers¹⁷ noted that although mature teratomas were most common (60%), immature teratomas accounted for 35% of cases. Giant teratomas have been described

by several authors in different sites. In the index case, the sacrococcygeal teratoma measured 30cm x 30cm x 10cm (Fig. 2). This is similar to a reported case of giant sacrococcygeal teratoma which measured 25cmx25cm.²³ The present study demonstrated a bimodal peak age distribution of teratomas in the first and third decades of life. This compares with the bimodal peak of age distribution of teratomas reported in a review of teratomas in Ibadan by Akang.⁶

In summary, teratomas are uncommon in Abakaliki, accounting for 4 per 1000 biopsy specimens. It occurred in all age groups displaying a bimodal peak age incidence. Females were more affected than males with the ovary being the commonest site of involvement. Benign neoplasms of the mature cystic types predominate and conspicuously, testicular teratoma was absent.

CONCLUSION

Benign cystic teratomas of the ovary are the commonest type of germ cell tumours seen in a tertiary healthcare institution in South-East Nigeria and females are at least eight times likely to be diagnosed with teratomas than males. There is no immature or malignant teratomas in this study apparently due to relatively small number of teratomas but vigilance is required in histopathological examination of all ovarian and non-ovarian tumors obtained from teratoma prone sites.

REFERENCES

1. **Shahar S1**, Morton NE. Origin of teratomas and twins. *Hum Genet* 1986; 74:215-218
2. **Akang EE**, Odunfa AO, Aghadiuno PU. A review of teratomas in Ibadan. *Afr J Med Med Sci.* 1994; 23(1):53-60
3. **Bezuidenhout J**, Schneider JW, Hugo F, Wessels G. Teratomas in infancy and childhood at Tygerberg Hospital, South Africa, 1973 to 1992. *Arch Pathol Lab Med* 1997;121(5):499-502
4. **Mambo NC**. Teratomas in children: review of cases in the 0-12 year age group seen at Harari Hospital over ten year period, 1960-1969. *Cent Afr J Med.* 1974;20(11):231-235
5. **Gabra HO**, Jesudason EC, McDowell HP, *et al*. Sacrococcygeal teratoma: A 25 year Experience in a UK regional centre. *J Pediatr Surg* 2006; 41: 1513-1516
6. **Akang EE**, Odunafa AO, Aghadiuno PU. Childhood teratomas in Ibadan, Nigeria. *Hum Pathol* 1992; 23(4):449-533
7. **Petr Havránek**, Allan Rubenson, Dorothea GÜth, *et al*. Sacrococcygeal teratoma in Sweden: A 10-year national retrospective study. *J pediatric Surg.* 1992 Nov; 27 (11): 1447-1450

8. **Girwalkar-Bagle A**, Thatte WS, Gulia P. Sacrococcygeal teratoma: A case report and review of literature. *Anaesth Pain & Intensive Care* 2014;18(4):449-451
9. **Thomas HO**. Cervical teratoma. *Brit J Surg* 1957; 44:625-627
10. **Matias C**, Huang YC. Gastric teratoma in infancy: report of a case and review of world literature. *Ann Surg* 1973; 178(5): 631–636
11. **Okani CO**, Aramide KO, Edegbe FO, *et al* Intrarenal teratoma: report of two cases seen in a 31-year retrospective study at the University College Hospital, Ibadan. *Niger J Med*. 2014 Jul-Sep;23(3):271-5
12. **Eble JN**, Sauter G, Epatein JI, Sesterhenn IA. World Health Organization Classification of Tumours. Pathology and genetics of tumours of the urinary system and male genital organs. IARC Press, Lyon, 2004: 217-278
13. **Mabogunje OA**, Nirodi NS, Lawrie JH, Edington GM. Teratoma in Nigerian children. *East Afr Med J* 1980; 50(7):461-468
14. **Abdul-Aziz A**, Tauqeer AM, Mohammad KB, Ali AE. Sacrococcygeal teratomas. *Saudi Med J* 2004; 25 (3): 367-369
15. **Berry GI**, Keeling J, Hilton C. Teratoma in infancy and childhood- A review of 91 cases
16. **Marsden HB**, Birch JM, Swindell R. Germ cell tumours of childhood: a review of 137 cases. *J Clin Pathol* 1981; 34:879-883
17. **Bezuidenhout J**, Schneider JW, Hugo F, Wessels G. Teratomas in infancy and childhood at Tygerberg Hospital, South Africa, 1973-1992. *Arch Path Lab Med* 1997; 121:499-502
18. **Junaid TA**. Ovarian neoplasms in children and adolescents in Ibadan. *Cancer* 1981; 47(3):610-614
19. **Exelby PR**. Testis cancer in children. *Semin Oncol* 1979;6(1):116-120
20. **Onuigbo WI**. Teratomas in the Igbos of Nigeria. *J Natl Cancer Inst* 1976;57(5): 1191-1192
21. **Bezuidenhout Juanita**, Schneider Johann W, Francois Hugo, Wessels Glynn. *Archives of Pathology & Laboratory Medicine*; Northfield Vol. 121, Iss. 5, (1997): 499-502.
22. **Junaid TA**. Testicular cancer in children and adolescents in Ibadan, Nigeria, *Urol* 1981;18:510-513
23. **Yam BR**, Rabin K, Amir B, *et al*. Giant sacrococcygeal teratoma in an adult: Case report. *Br J Neuros* 2009;23(6) : 628-629