

MAXILLARY FIRST PREMOLAR WITH THREE ROOT CANALS: A CASE REPORTA.O Sulaiman¹, O.O Dosumu¹ and McKing Amedari²

1. Department of Restorative Dentistry, University College Hospital, Ibadan.
2. Dental Center, University College Hospital, Ibadan.

*Correspondence:***Dr. A.O. Sulaiman**

Department of Restorative Dentistry

University College Hospital

Ibadan

Tel: +2348055066685

E-mail: tayooja@yahoo.co.uk

ABSTRACT

The maxillary first premolar is the most commonly bi-rooted tooth with occasional presentation of three roots system; it is a transitional tooth between incisors and molars. Although it usually has two canals, it may rarely have three and this third canal can easily be missed. Thus meticulous knowledge of tooth morphology, careful interpretation of angled radiographs, proper access cavity preparation and a detailed exploration of the interior of the tooth is needed to ensure a proper endodontic treatment. This article reports a rare finding of three canals in a maxillary first premolar with non well defined root outline radiographically during an elective root canal treatment.

Keywords: Maxillary First Premolar, Endodontic Treatment, Elective, Root Canal Morphology

INTRODUCTION

A clear understanding of the human teeth anatomy is a prerequisite to achieving proper access cavity preparation, thorough cleaning, disinfection and obturation of the pulp space. These objectives can be achieved by detecting the anatomical variations of the tooth under treatment. One of the major reasons for failure of root canal therapy is the inadequate knowledge about the anatomy of the pulp space in the root canals¹. Root canals are left untreated when the dentist fails to identify them particularly in teeth that have additional root canals^{1,2}.

The maxillary first premolar has two cusps with the buccal cusp prominently larger than the palatal cusp. This tooth is said to exhibit the greatest variation in root anatomy and root canal morphology^{2,3,4}. Radicular irregularities consist of fused roots with separate canals, fused roots with interconnections or “webbing”, fused roots with a common apical foramen and the unusual but always to be considered three-rooted tooth⁵. Variations in number and type of root canals are probably some of the most widely described anomalies in literature. The presence of two canals may be considered normal but racial differences in the root canal morphology of this and other premolars have been established^{2,6,7}. The anatomy of a maxillary premolar with three canals, mesio buccal, distobuccal and palatal is similar to the adjacent maxillary molars and they are sometimes referred to as small molars or radicular³. In a case of three root canals, the buccal orifices are not clearly visible with the mouth mirror. Directional positioning of the endodontic explorer or a small file may identify the canals^{3,5,8}.

The incidence of one root varies from 22% to 49.9%; two roots, 50.6% to 72% and three roots, 0 to 6%⁹⁻¹³. Several studies^{9,14,15} dealing with the canal morphology of the first maxillary premolar have revealed that in most instances they have two canals, although teeth with one or three canals do exist^{9,13-15}. Mariusz et al¹⁶ found 9.2% of first maxillary premolars with three canals.

This article presents the case of a maxillary first premolar with three canals in a non well defined root outline radiographically which is a rare clinical occurrence in our environment.

CASE REPORT

A 50 year old woman reported at our clinic with a request for replacement of her missing teeth in the upper right quadrant.

Pre operative radiograph of the right maxillary first premolar showed a radiopaque filling material on the distal aspect, coronally. The mesio distal width of the middle third of the root was approximately equal to the mesio distal width of the middle third of the crown with no clearly defined pulpal outline [Fig 1].

Comprehensive rehabilitative treatment plan for the replacement of the missing teeth in the affected quadrant with a fixed prosthesis entailed an elective root canal therapy on the right maxillary first premolar to serve as mesial abutment for the prosthesis. The procedure was commenced under local anaesthesia. Exploration of the pulp chamber was carried out with appropriate Nickel Titanium files sizes 10, and 15;

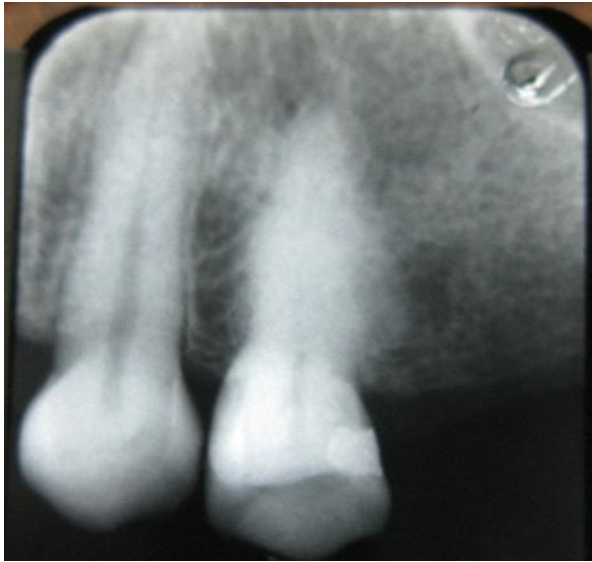

Fig. 1: Pre-operative radiograph showing 43| with the mesiodistal width of the midportion of the root of 4_| ~ the crown mesiodistal width

leading to clinical and subsequent radiographic confirmation of three canals: the palatal, mesiobuccal, and distobuccal canals [Fig2].

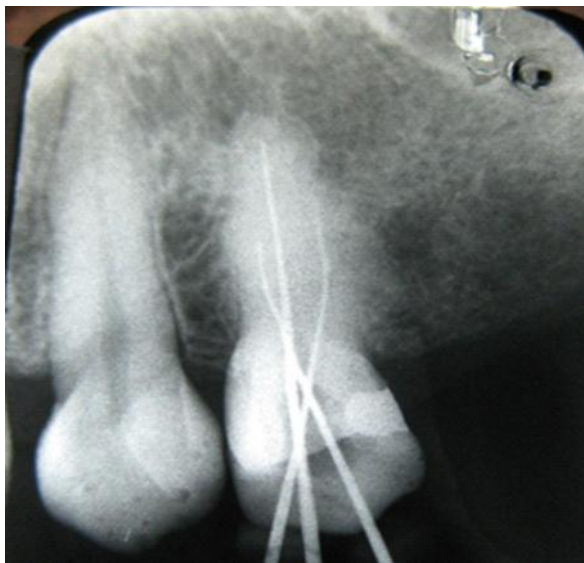


Fig. 2: Periapical radiograph of 4_| showing the three canals – the palatal, mesiobuccal and distobuccal like a miniature maxillary molar.

Bio mechanical preparation was carried out using the step back technique with recapitulation to the original working length. Apical preparation was done to size 25file, and coronal preparation to size 35file, all under copious irrigation with sodium hypochlorite. The canals were dried with paper points and the access cavity restored with zinc phosphate cement over cotton wool pledget, A week later, the patient was reviewed and she felt slight tenderness to percussion with the base

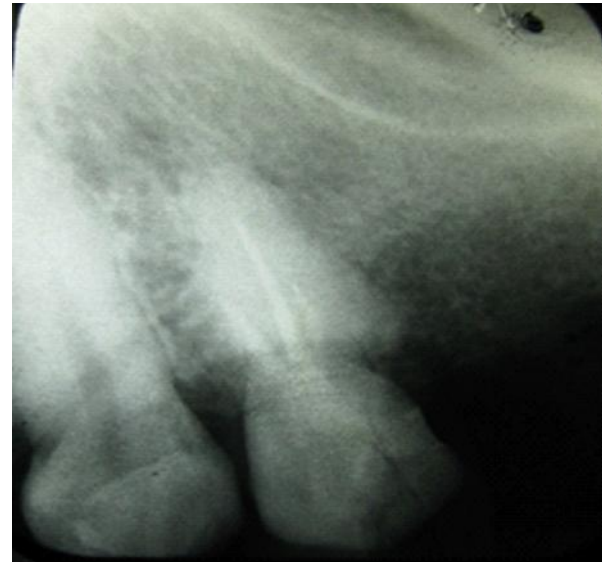

Fig 3: Periapical radiograph of the obturated canals of 4_|

of the mouth mirror but assessing the canals, they were found to be dry and uninfected.

Biomechanical preparation was again carried out by smoothing the wall of the canals followed by copious irrigation with sodium hypochlorite. Drying was achieved with paper points and the canals obturated with gutta percha and a resin sealer (AH26) using the lateral condensation technique [Fig3]. Two months later the patient was reviewed and the tooth was asymptomatic. A post space was prepared and a nickel titanium post cemented in with zinc phosphate cement. The tooth was prepared to serve as a mesial abutment for four-unit fixed-fixed bridge prosthesis.

DISCUSSION

The process of identifying and accessing root canals is particularly challenging in endodontic treatment of a tooth with atypical canal configuration. The maxillary first premolar has a highly variable canal and root morphology, frequently with separate canals and two foramina (72%)^{9,17}. In the past many dentists had treated the maxillary first premolar presuming them to have just two canals¹⁴. Studies have revealed that up to 6% of these teeth have three canals^{1,9,18}.

For a successful root canal treatment, it is essential to identify, clean and shape the root canal properly before placing a hermetic filling. The presence of an untreated canal; inadequate debridement and incomplete obturation of the root canal system are common reasons for failure of endodontic treatment¹⁹. A root canal may be left untreated because the dentist fails to recognize its presence^{20,21}. It is extremely important that clinicians use all the armamentarium at their

disposal to locate and treat the entire root canal system. It becomes humbling therefore being aware of the complexity of the spaces the operator is expected to access, shape, clean and fill.

Visualization of three canals in a maxillary premolar on pre operative radiographs can often be difficult. The root canal configuration resembles that of a miniature three canal maxillary molar [Fig 2]; the canals being classified as mesio buccal, palatal and the distobuccal²¹. Although the pre operative radiography gives a two dimensional image of a three dimensional object, there are some guides that suggest the presence of a third canal/root. Whenever there is an abrupt straightening or loss of radioluscent canal in the pulp cavity, a third canal should be suspected, either in the same root or in the other independent root²⁰. Also whenever the mesio distal width of the mid root image is equal to or greater than the mesio distal width of the crown, the tooth most likely has three roots⁷, and multiple canals are common when a radiograph shows an intra canal instrument as eccentric in the roots²³. It may be helpful to radiographically examine the contra lateral teeth when suspecting a complex root canal configuration⁷.

Root canal orifices are the number one guide in determining the outline form of the access cavity. In the maxillary first premolar an ovoid outline form is recommended¹. This figure 8-shaped access suggested as outline form restricts the expectation of the clinician to one or two root canal orifices. A third canal orifice should be considered, making a cut at the bucco proximal angle, from the entrance of the buccal canals to the cavo surface angle, as suggested by Balleri *et al*(1997)²⁴. Authors also described that this T-shaped access may be useful when porcelain fused to metal crowns are considered as final restoration². No technological advances or innovations can fully compensate for a lack of understanding of the anatomical features of the pulp chamber, which along with the root canal space are always located in the cross sectional centre of the crown and root respectively²⁵. In the case presented, the crucial step in finding the additional buccal canal was careful tactile examination of the buccal wall with appropriate file size¹⁵. Following the location of these canals, special consideration was also given to the biomechanical preparation of the canals and subsequent obturation to obtain a substantive hermetic seal. The location of canal orifices is best achieved with good illumination and a dry pulp floor. Magnification with either loupes or a microscope is usually considered beneficial; however the dental operating microscope (DOM) is usually better for detecting orifices^{2,6}

CONCLUSION

A thorough analysis of angled radiographs, conscientious exploration of the floor of the pulp chamber, a good knowledge of the anatomical description with possible variation of the canal system and sufficient time for treatment are necessary to achieve a successful outcome in root canal therapy.

REFERENCES

1. **Pitt Ford TR.** Harty's Endodontics in clinical practice. Elsevier limited. 5th edn 2004 pg 17
2. Bander A, Majed A, Shatha A, *et al.* Maxillary first premolar with three canals. *Smile Dent. J.* 2010; 5(3): 34-36
3. **Dax A,** Pravin K. Radiculous premolar. *Endodontology* 2011;23(2): 95-97
4. Ash and Nelson: Dental anatomy 8th ed. Philadelphia: Saunders; 2003.
5. Stephen C, Richard CB. Pathways of the pulp 6th edn 7: 142-143
6. **Trope M,** Elfenbein L, Trondstad L. Mandibular premolars with more than one root canal in different race groups. *J. Endod* 1986; 12: 343-345
7. **Sieraski SM,** Taylor GT, Kohn RA. Identification and endodontic management of three canal maxillary premolars. *J. Endod* 1985; 15: 29-32
8. **Miabaum WW.** Endodontic treatment of a radiculous maxillary first premolar: a case report. *Gen. Dentistry.* 1989; 37: 340-341
9. **Carns EJ,** Skidmore AE. Configuration and derivatives of root canals of maxillary first premolars. *Oral surg.* 1973; 36:880-886
10. **Kartal N,** Ozelik B, Climili H. Root canal morphology of the maxillary premolars. *J. Endod* 1985; 11:339-402
11. **Loh HS.** Root morphology of the maxillary first premolar in Singaporeans. *Aust. Dent. J.* 1973; 43:339-402
12. **Bellizi R,** Hartwell G. Radiographic evaluation of root canal anatomy of in-vivo endodontically treated maxillary premolars *J. Endodontics* 1985;11:37-41
13. **Vertucci FJ,** Gegaulf A. Root canal morphology of the maxillary first premolar *J. Am Dent. Assoc.* 1979; 99: 194-198
14. **Green D.** Double canals in single roots. *Oral surg.* 1973;35:690-691
15. **Pineda F,** Kuttler Y. Mesio distal and bucco-lingual roentgenographic investigation of 7,275 root canals. *Oral Surg.* 1972;33:101-110
16. **Mariusz L,** Krysof W, Ryta L, Mangorzata T. Root canal morphology of the first human maxillary premolar, *Durh. Anthro. J.* 2005; 12:2-3
17. **Bahareh D,** Zohreh K, Solaleh S. Endodontic Treatment of maxillary first premolar with type

- IV buccal root canal: A case report. IEJ 2009; 3(1):35-36
18. **Jesus DP**, Paulo CS, Manoel DS, Julian BW. Root form and canal anatomy of maxillary first premolars. Braz Dent. J.1991;2:87-94
 19. **Grossman L**. Endodontic failures. Dent Clin North Am. 1972;16: 50-70
 20. **Soares JA**, Leornado RT. Root canal treatment of three rooted maxillary first and second premolars: A case report. Int. Endod. J. 2003;36:705-710
 21. **Hasan O**, Funda KC. Maxillary first premolar with three roots. A case report. Hacettepe Dishekingligi Fakultesi Dergisi 2005;29(4): 26-29
 22. **Ehsan S**, Hamid A, Hamid J, Mohammed M. Endodontic treatment of radiculous maxillary premolars: two reports. Ind J Dent Edu. 2009; 2(3):99-105
 23. **Caliskan MK**, Pehlivan Y, Sepeticioglu F, Turkan M, Tuncer SS. Root canal morphology of human permanent teeth in Turkish population. J. Endod. 1995;21(4) 200-204
 24. **Balleri P**, Gesi A, Ferarri M. Primer premolar superior comtres raices. Endodontic Practice.1997;3:13-15
 25. **Guttman JL**, Dumsha TC, Lovdahl PE, Hovland EJ. Problem solving in Endodontics. Prevention, identification and management. 3rd edn St. Louis M. O, USA: Mosby- Year Book pg. 47
 26. **Yoshioka T**, Kobayashi C, Suda H. Detection rate of root canal orifices with a microscope. J. Endod 2002; 28:452-453