

SIMPLE ALGORITHM IN THE MANAGEMENT OF FETAL SACROCCOCYGEAL TERATOMA IN DEVELOPING COUNTRIES

A. Eighemhenrio

Department of Surgery, Irrua Specialist Teaching Hospital, Irrua, Edo State, Nigeria.

Correspondence:

Dr. Eighemhenrio .A

Department of Surgery,
Irrua Specialist Teaching Hospital,
Irrua,
Edo State, Nigeria.
E-mail: eaiwanlehi@yahoo.com

ABSTRACT

Sacroccocygeal teratoma is the commonest tumour in neonates. It is more common in females in about 80% of cases. Associated congenital abnormalities may be seen coexisting with sacroccocygeal teratomas in 10-20% of cases. Early diagnosis can be made through fetal ultrasound scan (USS). The presence of this tumour can have serious complications for both the fetus and mother. Apart from USS other specialized tests can be done, these may not be available in developing and low resource countries. A simple algorithm of management using USS and clinical findings can be adapted for use in these locations.

Keywords: Sacroccocygeal Teratoma, Algorithm, Ultrasound Scan

INTRODUCTION

Teratomas are embryonal tumours which originate from primordial germ cell. They are derived from at least two of the three germ cell layers. Teratomas involve the gonads as well as extragonadal parts of the body. The sacroccocygeum represents the commonest extragonadal location of teratomas. Sacroccocygeal teratoma (SCT) is the commonest neoplasm of the fetus and newborn.

The incidence of SCT is 1 in 20,000 to 1 in 40,000¹ Male to female ratio is 1:4.² In most studies about 80% of SCT are benign (mature). The malignant (immature) tumors are slightly more common in males and in neonates (68%) and older children (73%).³

Patients with SCT may have some associated abnormalities like anorectal malformations, spinal defects and oesophageal fistula in about 10% -20% of cases². Early prenatal diagnosis is crucial in the management and outcome of pregnancy and well-being of both mother and child.

The presence of this tumour in a fetus can have significant effect on the health of the pregnant mother as it may be associated with severe anaemia, cardiac failure, maternal mirror syndrome and even death. The developing fetus with SCT is prone to high output cardiac failure, hydrops, placentomegaly and complications of delivery.

Understanding a simple way of managing this condition is important in developing countries to prevent morbidities and mortalities. A simplified algorithm of

management will help in following the progress of pregnancy in such women and also aid in determining when and how to intervene. Some algorithms are present in literature, none however is designed for the developing countries where most centers are not sufficiently equipped.

This article describes a simple algorithm that can be adapted for developing countries in the management of fetal SCT.

PRENATAL DIAGNOSIS

Prenatal diagnosis is achieved by a maternal-fetal ultrasound scan (USS). This shows the tumour protruding from the sacral region with or without intrapelvic extension. Antenatal diagnosis is usually made after 22 weeks of gestation.⁴ Some reported cases of earlier prenatal diagnosis have been documented.⁴ Routine USS can diagnose many cases of asymptomatic SCT. However the most common indication for antenatal USS in fetal SCT has been a uterus that is large for gestational age either due to polyhydramnios or rapid growth of the tumour.⁴

Screening methods such as amniotic fluid alpha-fetoprotein or maternal serum screening have not proven to be effective but can be used postnatally to differentiate between benign and malignant SCT.^{5,6} Postnatal persistence in the level of alpha-fetoprotein may indicate a residual tumour, recurrence or malignant transformation.⁷

Other forms of prenatal diagnostic modalities include fetal magnetic resonance imaging (MRI), fetal echocardiography and doppler echocardiography. Fetal MRI is observed to give a clearer configuration of the tumour than USS.

In the developing countries these modalities are not readily available in most hospitals. In the few hospital where these investigations are available, they not affordable. This makes USS the most readily available investigative tool for evaluation and monitoring.

Prenatal problems and interventions

The fetus with SCT is at high risk of prenatal and perinatal complications. The natural history and pathophysiology of fetal SCT is different from that of postnatally diagnosed SCT. Survival of the fetuses with SCT is dependent on anticipation and recognition of the pathophysiologic events and optimal obstetric and surgical management⁹.

Postulated causes of perinatal deaths include hydrops, dystocia, tumour rupture, preterm labour secondary to polyhydramnios and anaemia due either to haemorrhage or haemolysis within the tumour⁸.

Most SCT diagnosed before birth can be managed by planned delivery and postnatal surgery. However, large tumours early in pregnancy may result in placentomegaly, hydrops, fetal death and a preeclampsia-like syndrome in the mother. This chain of events may result from high output cardiac failure

in the fetus caused by arteriovenous shunting through the tumour.¹⁰

The possible prenatal interventions include amnioncentesis, debulking, open fetal surgery and delivery. In the developing countries many hospitals do not have facilities and manpower for most of these specialized interventions. The only feasible option in most cases is to deliver the fetus. When and how to deliver is explained by this simple algorithm.

DISCUSSION

A routine fetal USS can be used to make a diagnosis of fetal SCT. USS is readily available in many hospitals in the developing countries. It can be used to also monitor the size of the tumor as pregnancy progresses. In the absence of any complications the pregnancy is closely monitored with regular scanning until when the pregnancy is term. At term a decision is taken to deliver the fetus. The choice of mode of delivery will be dependent on the size of the tumor. If it is less than 5cm vaginal delivery can be allowed. If greater than 5cm or in the presence of polyhydramnios elective caesarean section can be carried out.

However if during the course of pregnancy complications arise either in the fetus or mother the line of decision changes. If the fetus is preterm a choice of termination of pregnancy can be taken. If however the complications arise at a time when the fetus is term

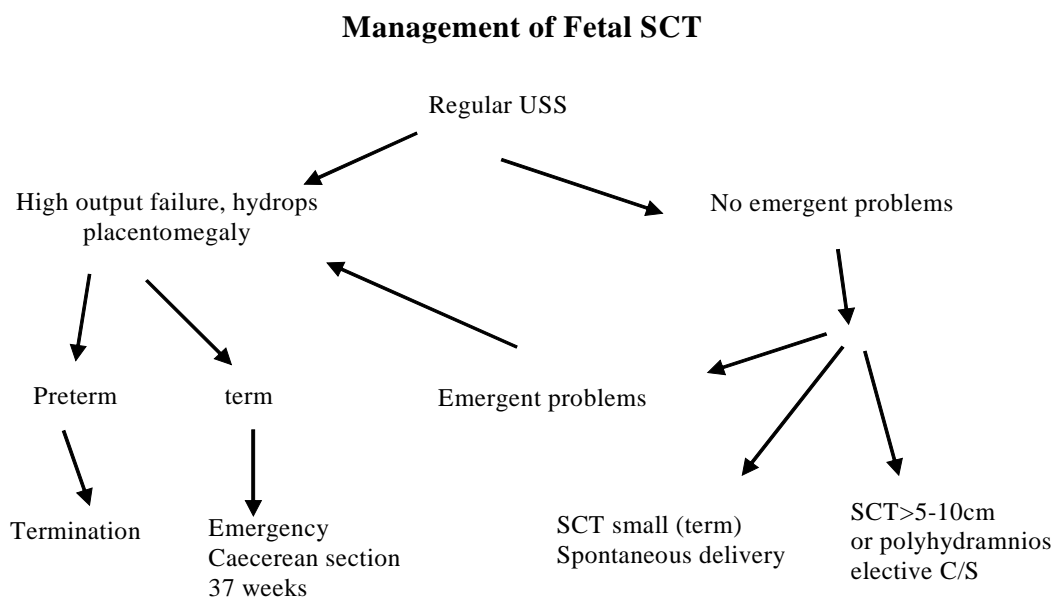


Fig. 1: Simple algorithm in the management of fetal SCT

or can withstand extrauterine life an emergency caesarean section is done.

This algorithm is cheap to use and can easily be adapted to locations where specialized facilities are absent.

CONCLUSION

Management of sacroccocygeal teratoma can be simplified and individualized to achieve good outcome in communities where specialized facilities are absent. Appropriate use of USS along with good clinical judgement can help save the lives of many fetuses and their mothers with this condition.

REFERENCES,

1. Mackinlay GA. Sacroccocygeal teratoma, Forfar and Arneil textbook of Paediatric 4th edn, Churchill Livingstone, London UK, 1861-1862
2. **Kamal Abd Elelah Aly**, Shoier M, Badrawy T. Sacroccocygeal teratoma, A Neonatal Surgical Problem. Annals of Paediatric Surgery, April 2006;2(2): 101-111
3. **Keslar PJ**, Buck JL, Suarez ES; Germ cell tumours of the sacroccocygeal region; radiologic-pathologic correlations. Radiographics 14;607-622,1994
4. **Bhat PA**, Kushtagi P, Bhat A. Fetal Sacroccocygeal teratoma .The internat Journal of Gynaecology and Obstetrics, 1528-8439
5. **Shinjiro H**, Diana LF. Fetal Surgery for Sacroccocygeal teratoma. Clin Perinatol 2003;30:493-506
6. **Fiona NC**, Nicole W, Lachian de C. Prenatal diagnosis and management of Sacroccocygeal teratoma. Aust NZ J Obstet Gynaecology 1999;39(4) 497-501
7. **Kuhajda FP**, Taxy JB. Oncofetal antigens in Sacroccocygeal teratoma Arch Pathol Lab Med,1993; 107:239-242,
8. **Der-Ji Sun**, Jau-Nan Lee, Cheng-Yu Long, Eing-Mei Tsai. The Kaohsiung Journal of Medical Sciences,Vol 19,Issue 6,June 2003: 313-316
9. **Flake AW**. Fetal Scarocccocygeal teratoma; Seminars in Paediatric Surgery 1993,2(2): 113-120
10. **Langer JC**, Harrison MR, Schmidt KG *et al*.Fetal hydrops and death for Sacroccocygeal teratoma, rationale for fetal surgery. American Journal of Obstetrics and Gynaecology 1998; 160(5 pt 1): 1145-1150