

Presence of lupus anticoagulant in an asymptomatic Nigerian

* Edeghonghon E. Olayemi, ** Godwin N. Bazuaye

*Department of Haematology and Blood Transfusion, OACHS, Olabisi Onabanjo, University, P.M.B. 2022, Sagamu, Ogun State. Nigeria, ** Department of Haematology and Blood Transfusion, University of Benin Teaching Hospital, P.M.B. 1111, Benin City, Edo State. Nigeria

Abstract

Background: The lupus anticoagulant (LA) is one of the antiphospholipid antibodies (aPL), which prolong phospholipid-dependent coagulation tests by interfering with coagulation reactions that depend on protein-phospholipid complexes in vitro.

Method: A 25 year old 'healthy' male Nigerian was screened for the presence of any coagulation abnormality using the KCT, PT and platelet count; after volunteering for his plasma to be used in the preparation of normal pooled plasma in a study.

Results: He was discovered to have a prolonged KCT, PT and normal platelet count. Based on the prolonged KCT his plasma was subjected to mixing studies with various concentration of normal pooled plasma; the KCT index was calculated and a curve was plotted. His KCT index was 1.6 and the curve convex in the left axis suggesting the presence of LA. His past medical history and physical examination were not remarkable. Three months after the initial study, a repeat KCT index was 1.4 and the subject asymptomatic.

Conclusion: From literature review this is the first report of LA in an asymptomatic adult Nigerian; the importance of this finding is discussed.

African Health Sciences 2007; 7(3): 182-184

Introduction

The lupus anticoagulant (LA) is one of the antiphospholipid antibodies (aPL), which prolong phospholipid-dependent coagulation tests by interfering with coagulation reactions which depend on protein-phospholipid complexes in vitro¹; isotypes include immunoglobulin G (IgG), immunoglobulin M (IgM), immunoglobulin A (IgA) or combinations of these².

The presence of the lupus anticoagulant has been associated with certain clinical manifestations such as recurrent abortions, arterial and venous thrombosis, and thrombocytopenia³. Cutaneous symptoms of this syndrome include leg ulcers and livedo reticularis⁴. Neurological disorders such as dementia, epilepsy, chorea and migraine⁵ can also occur. The first antiphospholipid antibody was detected in patients with syphilis in 1906⁶ while the lupus anticoagulant (LA) was first described in 1952⁷.

The most commonly detected antiphospholipid antibodies are lupus anticoagulant, anticardiolipin and anti-beta 2 glycoprotein 1 (â-2GP-1) antibodies¹. LA antibodies are identified by coagulation

assays, in which they prolong clotting times while anticardiolipin and anti-â-2GP-1 antibodies are detected by immunoassays that measure immunologic reactivity to a phospholipid or a phospholipid-binding protein. Current criteria for detection of LA antibodies include prolongation of at least one phospholipid-dependent coagulation assay¹. KCT has been shown to have a specificity of up to 93% for LA⁸ and it is able to detect LA at a much greater dilution in normal plasma than the tissue thromboplastin inhibition test (TTI) or the dilute Russell's viper venom time (DRVVT)⁹. KCT is also more sensitive to the presence of LA than TTI¹⁰.

Case Report

O.U. a 25 year old male Nigerian who was a final year student in one of the universities in the south-south geopolitical zone of Nigeria; volunteered to have his plasma used to prepare normal pooled plasma in a study approved by the University of Benin Teaching Hospital ethics committee.

As a pre-condition to having his plasma pooled along with those of other volunteers we had to carry out tests to ensure that he did not have any clotting abnormalities, this included platelet count, prothrombin time (PT) and kaolin clotting time (KCT). It was during this that he was detected to have a prolonged KCT and slightly prolonged PT.

On further investigation O.U. has lived a relatively healthy life, there was neither any past history of thrombosis nor family history of thrombosis, both

Correspondence author:

Olayemi,

Department of Haematology and Blood Transfusion, OACHS,

Olabisi Onabanjo University, P.M.B. 2022,

Sagamu, Ogun State. Nigeria.

Email: yemiede@yahoo.com

parents and all his siblings are alive and well. The patient had not been previously transfused; he is not a known epileptic neither has he ever suffered from migraine headaches. He has never taken any drug such as phenytoin or chlorpromazine which have been associated with LA.

On general examination he was a healthy young man, he was not pale, was afebrile and anicteric, he had no lymphadenopathy, did not have any petechiae or echymotic spots. His chest was clinically clear, pulse rate was 78/minute, regular and of good volume. Only the first and second heart sounds were present and his blood pressure was 110/70 mmHg. No abdominal organs were palpable. He had no neurological deficits.

Method and Results

Kaolin clotting time (KCT) was performed as described previously^{11,12}. The procedure was carried out in duplicates and the average was taken as the clotting time.

Due to the prolonged KCT, we decided to carry out mixing tests on his plasma using the KCT; in the

following proportions of normal plasma (NP) and subject's plasma (SP). NP/SP: 100/0, 90/10, 80/20, 50/50, 20/80, 10/90 and 0/100 as earlier described¹². The KCT index, which is the ratio of KCT at 20% subject plasma to KCT at 100% normal plasma was then calculated as shown below.

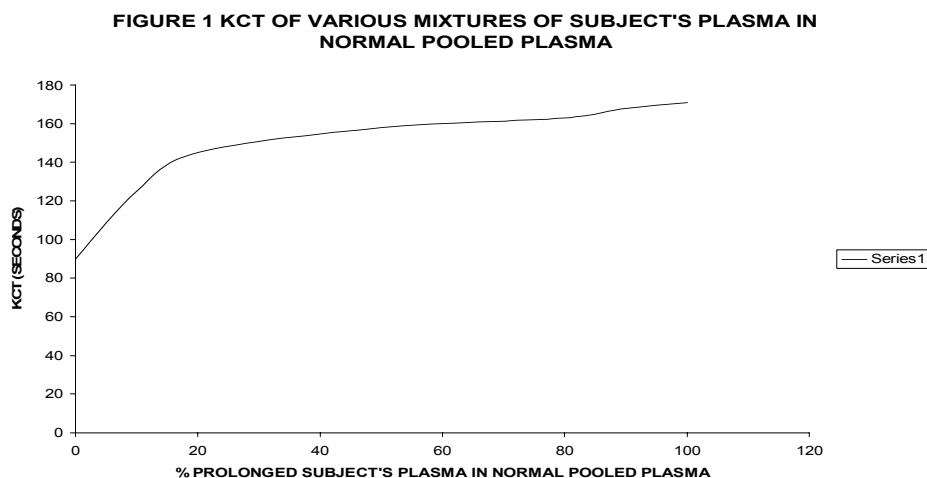
$$\frac{\text{KCT (80\% Normal Plasma: 20\% Subject's Plasma)}}{\text{KCT 100\% Normal Plasma}} = />1.2$$

A ratio of greater than or equal to 1.2 was taken to signify the presence of LA¹². Normal KCT and PT in our laboratory is 60-110 seconds and 10 -14 seconds respectively. Results of laboratory investigations carried out are shown in table 1. A graph of KCT of various mixtures of SP in normal pooled plasma was also plotted, this curve was convex in the left axis, and in keeping with earlier studies by Exner et al¹¹, such a shape is suggestive of the presence of LA (Figure 1).

Table 1: Results of Laboratory Investigations

Investigation	Result
KCT	188 seconds (163 seconds)
KCT Index	1.6 (1.4)
PT	17 seconds (16.5 seconds)
Packed cell volume	0.41 (0.43)
Platelet count	300,000/mm ³ (273,000/ mm ³)
White blood cell count	5,300/mm ³ (6,200/mm ³)
ESR	12 mm/hour (Westergren)
Direct antiglobulin test	Negative
Indirect antiglobulin test	Negative
HIV screen	Negative

Figure in brackets is the repeat laboratory investigations after 3 months



Discussion

LA is commonly associated with patients who have systemic lupus erythematosus (SLE) and other autoimmune disorders, though recently, it has been shown that LA may be responsible or at least play a significant role in recurrent foetal loss.

LA and other aPL have been previously described in asymptomatic subjects from other parts of the world. In fact, it has been said that up to 2% of the normal population may be positive for aPL and it is not known what percentage of this would go on to develop thrombosis or other signs and symptoms of antiphospholipid syndrome (APS); though only about 0.2% have high titres¹³. Like other autoantibodies, prevalence increases with age¹⁴. LA has been described in children¹⁵. In patients with SLE, the prevalence of aPL is much higher, ranging from 12-30 % for anticardiolipin antibodies¹⁶ and 15-34 % for LA^{16,17}. In our environment, LA has been described in women with pre-eclampsia¹⁸; multiparous women¹⁹, as well as in sickle cell disease patients²⁰; we believe that this is the first time LA is being reported in an asymptomatic male Nigerian.

Patients may have laboratory evidence of aPL without clinical consequences¹. The presence of LA in a healthy subject may lead to confusing results of the clotting profile as the presence of LA is known to be capable of prolonging the PT, APTT, KCT and other measures of haemostasis. Also it may lead to endless and often expensive investigations in an attempt to uncover the presence of APS, SLE or other cause. It is for these reasons that we are reporting this case to create awareness of this possibility in our environment and save otherwise healthy patients from unnecessary laboratory investigations and anxiety.

Three months after the subject was detected as having LA, his KCT was still prolonged with an index of 1.4 (Table 1). However he has remained healthy and has since completed his tertiary education and is currently in paid employment.

In conclusion, LA has been described in healthy subjects from other parts of the world we have here reported its presence in a healthy male Nigerian.

References

1. Levine JS, Branch W, Rauch J. The antiphospholipid syndrome. *N Engl J Med*. 2002; 346:752-763.
2. Westerman MP, Green D, Gilman-Sachs A. et al. Antiphospholipid antibodies, protein C and S, and coagulation changes in sickle cell disease. *J Lab Clin Med* 1999; 134: 352-362.
3. Cuadrado MJ, Mujic F, Munoz E, Khamashta MA, Hughes GR. Thrombocytopaenia in the antiphospholipid antibody

4. syndrome. *Ann Rheum Dis* 1997; 56:194-196.
4. Miori L, Bellosta M, Miori E, Rabbiosi G. Clinical manifestations associated with the presence of lupus anticoagulant. *J Ital Dermatol Venereol*. 1989; 124:107-110.
5. Chapman J, Shoenfeld Y. Neurological and neuroendocrine-cytokine interrelationship in the antiphospholipid syndrome. *Ann NY Acad Sci*. 2002; 966:415-424.
6. Wassermann A, Neisser A, Bruck C. Eine serodiagnostische Reaktion bei Syphilis. *Deutsche Med Wochenschr* 1906; 32:745-746.
7. Conley CL, Hartmann RI. A haemorrhagic disorder caused by circulating anticoagulant in patients with disseminated lupus erythematosus. *J Clin Invest*. 1952; 31:62-62.
8. Ferro D, Saliola M, Quintarelli C. et al. Methods for detecting lupus anticoagulant and their relation to thrombosis and miscarriage in patients with systemic lupus erythematosus. *J Clin Pathol*. 1992; 45: 332-338.
9. Exner T. Comparison of two simple tests for the lupus anticoagulant. *Am J Clin Pathol*. 1985; 83: 215-218.
10. Lesperance B, David M, Rauch J, Infante-Rivard C, Rivard GE. Relative sensitivity of different tests in the detection of low titre lupus anticoagulant. *Thromb Haemost*. 1988; 60: 217-219.
11. Exner T, Rickard KA, Kronenberg H. A sensitive test demonstrating lupus anticoagulant and its behavioural patterns. *Br J Haematol* 1978; 40:143-151.
12. Laffan MA, Bradshaw A: Investigation of a thrombotic tendency. In: Dacie JV, Lewis SM. Eds. *Practical Haematology*, Ed. 8: Churchill Livingstone Edinburgh 1994: P. 351-354.
13. Lockshin MD. Answers to the antiphospholipid – antibody syndrome. *N Engl J Med*. 1995; 332:1025-1027.
14. Petri M. Epidemiology of the antiphospholipid antibody syndrome. *J Autoimmun* 2000; 15:145-151.
15. Quintero-Del-Rio AL. Antiphospholipid antibodies in paediatrics. *Curr Rheumatol Rep*. 2002 Oct; 4: 387-91.
16. Cervera R, Khamashta MA, Font J et al; Systemic lupus erythematosus: clinical and immunologic patterns of disease expression in a cohort of 1,000 patients. *Medicine (Baltimore)* 1993; 72:113-124.
17. Love PE, Santoro SA. Antiphospholipid antibodies: anticardiolipin and the lupus anticoagulant in systemic lupus erythematosus (SLE) and in non-SLE disorders: prevalence and clinical significance. *Ann Intern Med* 1990; 112: 682-698.
18. Awodu OA, Shokunbi WA, Ejele OA. Lupus anticoagulant in Nigerian women with preeclampsia. *West Afr J Med* 2003; 22:240-242.
19. Awodu OA, Ejele OA, Shokunbi WA, Enosolease ME. Prevalence of lupus anticoagulant in multiparous women in Benin City. *Niger Postgrad Med J* 2003; 15: 145-151.
20. Olayemi E, Halim NKD, Durosinmi MA, Awodu OA. Lupus anticoagulant in Nigerian children with homozygous sickle cell disease. *Annals of African Medicine* 2005; 3: 122-126.