

# Hepatitis B virus and HIV infection among patients with primary hepatocellular carcinoma in Kampala, Uganda

\*Ocama P<sup>1</sup>, Opio KC<sup>1</sup>, Kagimu M<sup>1</sup>, Seremba E<sup>2</sup>, Wabinga H<sup>1</sup>, Colebunders R<sup>3</sup>

1. Makerere University College of Health Sciences, Kampala, Uganda
2. Mulago Hospital, Kampala, Uganda
3. University of Antwerp, Institute of Tropical Medicine, Belgium

## Abstract

**Background:** Hepatitis B virus (HBV) is the commonest cause of primary hepatocellular (PHC) carcinoma worldwide. Co-infection with the HIV leads to more rapid progression of liver disease.

**Objectives:** We described prevalence of HBV and HIV among patients with PHC admitted to Mulago Hospital, Kampala, Uganda.

**Methods:** We assessed all patients admitted to the gastrointestinal service of Mulago hospital with a diagnosis of PHC for HBV and HIV infection.

**Results:** From March to June 2008, we recruited 15 patients. Nine (60%) were male; the overall median age was 32 years (IQR 15 -67), with median ages for male and female 33 and 36 years respectively. Alanine aminotransferase, aspartate aminotransferase, alkaline phosphatase and AFP were all elevated with median values of 57.5 IU/L, 222 IU/L, 392 IU/L and 362 ng/ml respectively (IQR 14-145, 49-393, 165-1294 and 7-480). Eight (53%) patients were from North and Northeastern Uganda. The HBsAg was reactive in 13(87%) patients and HIV in 3(20%), all of whom were also co-infected with HBV.

**Conclusion:** There is high prevalence of HBV and HBV/HIV co-infection among patients with PHC in Uganda with high mortality. Reduction in incidence and mortality due to PHC in Uganda will require urgent large scale HBV vaccination.

**Key Words:** Hepatitis B, HIV, Primary Hepatocellular Carcinoma

*African Health Sciences* 2011; (S1): S20 - S23

## Introduction

Hepatitis B virus (HBV) is the commonest cause of primary hepatocarcinoma (PHC) all over the world and the distribution of PHC mirrors the prevalence of HBV, being very high in sub-Saharan Africa and Asia<sup>1</sup>.

So far reports of HBV and HIV co-infection and rapid liver disease progression have mainly come from the West<sup>2,3</sup>. In Uganda earlier studies on PHC before the HIV epidemic showed high prevalence rates of HBV (60-80%) among patients with PHC<sup>4-7</sup>.

Indeed analysis from Kampala cancer registry indicated an increase of PHC among women over the periods 1960- 1980 and 1991 to 2005. The reason for this increase needs further studies<sup>8</sup>.

In this study we describe the prevalence of HBV and HIV among patients with PHC admitted to Mulago Hospital, Kampala, Uganda as well as the histological types and 1 month outcome from time of diagnosis.

## Methods

During the study period we assessed consecutively all patients admitted to the gastrointestinal service of Mulago hospital with a diagnosis of PHC. Primary hepatocellular carcinoma was defined as definite (histopathologic evidence of PHC) or highly probable (elevated alpha fetoprotein (AFP) >100 IU/ml + liver mass compatible with PHC on ultrasound scan). A questionnaire collecting demographic characteristics was administered to all participants. Hepatitis B surface antigen (HBsAg) testing was performed using the rapid HBV testing (HBsAg dipstick, Cypress Diagnostics, Belgium) while HIV serology status was ascertained using rapid Abbott test kits (Abbott determine HIV-1/2, Abbott Park, IL). All patients had AFP levels determined; upper limit of normal was 8 IU/ml. Liver biopsies were performed under ultrasound guidance and the

### \*Correspondence author

Ponsiano Ocama  
Department of Medicine  
Makerere University College of Health Sciences  
P.O.Box 22418  
Kampala, Uganda  
Phone: 256 772 421190  
Email: [pocama@idi.co.ug](mailto:pocama@idi.co.ug),  
[ponsianoocama@yahoo.com](mailto:ponsianoocama@yahoo.com)

liver tissues processed at Pathology Department of Makerere University School of Medicine.

First the tissue is kept in 10% formal saline solution for 24 hours after which it is embedded in paraffin wax and sections cut for staining using Haematoxylin and Eosin (H&E). Examination of the sections was done by a senior pathologist (HW).

Patient attendant telephone contacts were taken and telephone calls made one month after PHC diagnosis (for those who were discharged) to define patient status.

The study was approved by the Institutional review Board of the Faculty of Medicine, Makerere University and all patients consented to participate in the study.

## Results

From March to June 2008, we recruited 15 patients diagnosed with PHC. Nine (60%) were male; the

overall median age was 32 years (IQR 15 -67 ), with median ages for male and female 33 and 36 years respectively (Table 1). Alanine aminotransferase, aspartate aminotransferase, alkaline phosphatase and AFP were all elevated with median values of 57.5 IU/L, 222 IU/L, 392 IU/L and 362 ng/ml respectively (IQR 14-145, 49-393, 165-1294 and 7-480). Eight (53%) patients originated from North and Northeastern Uganda.

A liver biopsy was performed in 11 (73 %) patients. In 4 (27 %), because of coagulopathy a biopsy was not performed and the PHC diagnosis was made on the basis of liver mass (es) on ultrasound scan and these patients had AFP of 350 IU/ml or more.

**Table 1: Characteristics of 15 patients with Primary Hepatocellular carcinoma admitted to the Gastroenterology service of Mulago Hospital, Kampala, Uganda**

<b>Serial No</b>	<b>Age</b>	<b>Sex</b>	<b>HBsAg</b>	<b>HIV serology</b>	<b>ALT(Normal &lt;/=40 IU/ml)</b>	<b>AST(Normal &lt;/=32 IU/ml)</b>	<b>ALP(Normal &lt;/=129 IU/ml)</b>	<b>GGT(Normal &lt;/=65 IU/ml)</b>
1	38	F	P	N	43	549	165	457
2	18	F	P	N	46	46	356	248
3	28	M	P	N	54	119	1294	365
4	19	M	P	N	87	321	346	535
5	15	M	P	N	130	100	392	250
6	26	M	P	N	105	307	601	315
7	43	F	P	N	74	332	449	633
8	33	F	P	P	79	222	1043	312
9	30	F	N	N	14	96	680	413
10	38	M	P	N	51	270	294	122
11	36	M	P	P	145	393	930	484
12	38	M	N	N	55	136	*	268
13	45	F	P	P	60	40	120	60
14	33	M	P	N	60	275	*	192
15	67	M	P	N	18	88	349	226

Continuation of table

<b>Serial No</b>	<b>AFP (Normal &lt;/=8 IU/ml)</b>	<b>Histopathology type</b>	<b>Status at 1 month</b>
1	400	Trabecular	A
2	326	Trabecular	D
3	400	X	A
4	400	Trabecular	D
5	362	Trabecular	D

Continuation of table 1

<b>Serial No</b>	<b>AFP (Normal &lt;/=8 IU/ml)</b>	<b>Histopathology type</b>	<b>Status at 1 month</b>
6	400	Trabecular	A
7	326	Trabecular	D
8	400	X	A
9	400	Trabecular	D
10	362	Trabecular	D
11	7	Trabecular	D
12	338	Fibrolamellar	D
13	480	X	D
14	400	Adenoid	D
15	350	X	D

M-Male, F- Female, P- positive, N- negative, X- Biopsy not done, D-Dead, A-Alive, ALT- Alanine aminotransferase, ALP- Alkaline phosphatase, AST Aspartate aminotransferase, GGT- Gamma glutamyltraspeptidase, AFP- Alpha-fetoprotein, HBsAg- Hepatitis B surface antigen, HIV- Human immune deficiency virus

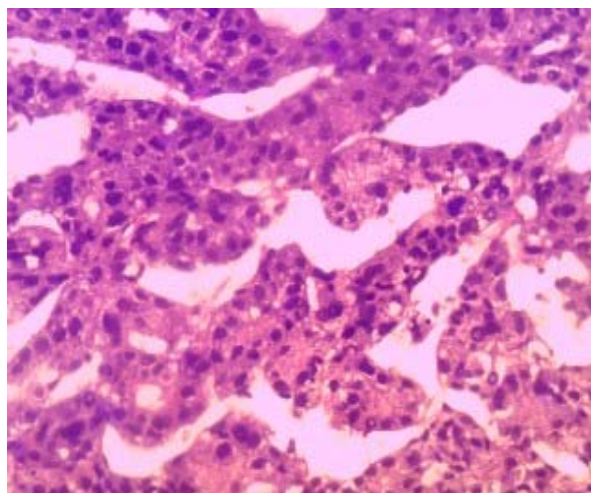
\* Patients in whom ALP measurements were missing

In 9 (82%) of the 11 patients in whom a liver biopsy was obtained, the liver cancer was of the trabecular type (Figure 1a) In the remaining 2 patients the PHC was either of fibrolamellar (1) (Figure 1b) or adenoid (1) types.

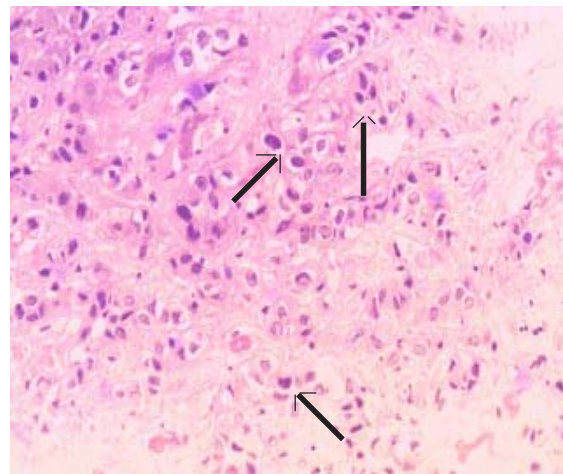
Hepatitis B surface antigen was positive in 13(87%) patients while HIV serology was reactive in 3(20%), all of whom were also co-infected with HBV.

Eleven (73%) patients died in the first month of the diagnosis of liver cancer two of whom died while still on admission.

**Figure 1a: H and E stain of liver tissue showing hyperchromatic cells forming trabeculae. (Magnification X200)**



**Figure 1b: H and E stain of liver tissue showing hyperchromatic pleomorphic cells of fibrolamellar type hepatocellular carcinoma (arrows). (Magnifications x200)**



## Discussion

The results of this study underscore the critical role of HBV in the pathogenesis of PHC. The HBV surface antigen was positive in 86% of the PHC patients. Worldwide, the prevalence of HBV among patients with PHC varies considerably with lower rates seen in Western studies compared to Asia and some sub-Saharan African countries<sup>1, 9,10</sup>.

There are strong reasons to suspect that HIV might increase the prevalence of PHC, since it clearly accelerates HBV-related liver disease<sup>3</sup>. However, in

our study the HIV/HBV co-infection prevalence mirrors the 14% to 18% co-infection reported in previous Ugandan studies<sup>11,12</sup>.

It may be that high HIV-related mortality has masked expression of the effects of HIV on liver disease progression. With the rapid roll out of antiretroviral therapy, as patients live longer, we may begin to see higher rates of chronic liver disease including cirrhosis and PHC in HIV infected persons.

Primary hepatocellular carcinoma in Uganda occurs in young patients<sup>5,6</sup>. In our study the youngest patient was 15 years old. This is probably a result of either perinatal or early childhood pattern of HBV transmission that progresses on to cirrhosis, and in some, to PHC during 20-30 years of life. Unfortunately in Uganda, there is no regular screening for HBV, and even in patients with cirrhosis, monitoring for PHC is not routinely done. Almost all patients therefore present late for treatment leading to the high one month mortality rate of up to 73% in our study. Indeed all patients had multiple liver masses that could not be resected. However even in those cases where resection would be possible in Africa, this extensive surgery is performed in only a few hospitals. Moreover with that late presentation mortality in the very experienced centers is still very high<sup>10</sup>. The most important preventive measure is vaccination against HBV. It is important to note that there was only modest elevation of ALT in these patients, most likely due to the chronic nature of the liver disease, also evidenced by a higher elevation in the AST.

This study only assessed few patients with PHC who presented to the gastroenterology service during this period of observation. The role of other factors such as hepatitis C, aflatoxins, alcohol, schistosomiasis, obesity and HIV needs to be considered in a larger well designed study.

## Conclusion

Our study confirms the high prevalence of HBV and HBV/HIV co-infection among patients with PHC in Uganda with high mortality. Since there is an effective vaccine against HBV, reduction in incidence and mortality due to PHC in Uganda will require urgent large scale HBV vaccination but the effects will take long to be seen since even infant vaccination against HBV only started recently in Uganda

## Acknowledgments

We thank Lawrence Osuwat who performed histological processing of all the liver tissues and Godfrey Gemageine for providing the photomicrographs. The study was supported by the SIDA SAREC small grants project from the faculty of Medicine, Makerere University

## References

1. Raza SA, Clifford GM, Franceschi S. World wide variation in the relative importance of hepatitis B and hepatitis C in hepatocellular carcinoma: a systematic review. *Br J Cancer* 2007; 96: 1127-34.
2. Hoffmann CJ, Thio CL. Clinical implications of HIV and hepatitis B co-infection in Asia and Africa. *Lancet Infect Dis.* 2007;7:402-9.
3. Thio CL, Seaberg EC, Skolasky R et al. HIV-1 hepatitis B virus and risk of liver related mortality in the multicenter cohort study (MACS). *Lancet* 2002;360:1921-26.
4. Wogan GN. Dietary factors and special epidemiological situations of liver cancer in Thailand and Africa. *Cancer research.* 1975;35:3499-502.
5. Olweny CLM, Toya T, Katongole-Mbidde E et al. Treatment of Hepatocellular carcinoma with adriamycin- preliminary communication. *Cancer research.* 1975; 36:1250-7.
6. Olweny CLM, Katongole-Mbidde E, Bahendeka S et al. Further experience in treating patients with hepatocellular carcinoma in Uganda. *Cancer* 1980; 46:2717-22.
7. Tabor E, Gerety RJ, Vogel CL et al. Hepatitis B virus infection and primary hepatocellular carcinoma *J Natl Cancer Inst* 1977; 58:1197-2000.
8. Ocama P, Namboozee S, Opio CK, Shiels MS, Wabinga HR, Kirk GD. Trends in the incidence of primary liver cancer in Central Uganda, 1960-1980 and 1991-2005. *Br J Cancer.* 2009; 100(5):799-802.
9. Parkin DM, Bray F, Ferlay J, Pisani P. Global cancer statistics 2002. *CA Cancer J Clin* 2005; 55:74-108.
10. But DYK, Lai CL, Yuen MF. Natural history of hepatitis-related hepatocellular carcinoma. *World J Gastroenterol* 2008; 14:1652-56.
11. Ocama P, Katwete M, Piloya T. et al. The spectrum of liver disease in HIV infected patients at an HIV treatment clinic in Kampala, Uganda. *African Health Sciences* 2008;8:8-12.
12. Nakwagala N, Kagimu M. Hepatitis B virus and HIV infections among patients in Mulago hospital. *East Afr Med J* 2002;29:68-72.