

Non infective bullous lesions: a diagnostic challenge in a minimally equipped centre- based solely on microscopic findings

Rashi Garg^{1,2}, Kaushal Bhojani¹

1. Pandit Deendayal Upadhyay Medical College.
2. Maharishi Markandeshwar University Solan.

Abstract

Vesicobullous lesions of skin may occur in different forms of dermatosis, which include various inflammatory, infective, autoimmune, drug induced as well as genetic conditions. Autoimmune bullous lesions, may be fatal if not treated with appropriate agents. Bearing in mind, the morbidity of these diseases, it is important to establish a firm diagnosis. A diagnostic skin biopsy with immunofluorescence is frequently used to confirm a clinical diagnosis, especially where it is not apparent clinically. There are many centres in India where immunofluorescence is not available and the diagnosis in these lesions is based on clinical and histopathological features only. Here in this study, we studied 53 skin punch biopsies with clinical suspicion of vesicobullous lesions followed by histopathological examination was carried out over a period of 2 years in a Medical College in Gujarat. Lesions were categorised based on the location of the blister. 1) Suprabasal 2) subcorneal 3) and subepidermal. Further subtyping was done based on additional histopathological features and clinical correlation. All the patients responded appropriately to the treatment and the results correlated well with the immunofluorescence done in a few cases. This study lays emphasis upon the histopathology and clinical features keeping in consideration of the lack of ancillary techniques in many centres especially in the developing world.

Keywords: Non infective bullous lesions, microscopic examination.

DOI: <https://doi.org/10.4314/ahs.v20i2.42>

Cite as: Garg R, Bhojani K. *Non infective bullous lesions: a diagnostic challenge in a minimally equipped centre- based solely on microscopic findings.* *Afri Health Sci.* 2020; 20(2): 885-890. <https://doi.org/10.4314/ahs.v20i2.42>

Introduction

Vesicles and bullae are fluid filled cavities formed within or beneath the epidermis. Vesicles are less than 0.5cm in diameter and bullae are blisters greater than 0.5 cm in diameter. They may occur in many different forms of dermatosis, which include various inflammatory, infective, autoimmune, drug induced as well as genetic conditions.^{1,2} Autoimmune bullous lesions, may be fatal if not treated with appropriate agents. Bearing in mind, the morbidity of these diseases, it is important to establish a firm diagnosis.³

A diagnostic skin biopsy is frequently used to confirm a clinical diagnosis, especially where it is not apparent clinically. There are many centres in India where immunofluorescence is not available and the diagnosis in these lesions is based on clinical and histopathological

features only. We studied 53 such cases and in regard to the meagreness of further resources in most of the developing world, we used histopathology and clinical features only to diagnose these cases.

Materials and methods

Skin punch biopsies with clinical suspicion of vesicobullous lesions were studied over a period of 2 years in a Medical College in Gujarat. Specimen were sent in 10% formalin. It was kept for 24 hours in 10% formalin for proper fixation. The specimens were fixed in 10% formal saline, subsequently dehydration, clearing, embedding in paraffin wax were carried out. Blocks were made, sections of 3µm thickness were cut and stained with Harris Haematoxylin and eosin stain.

Results

Total number of biopsies received during the study were 425, of these 12.5 % (53 cases) constituted non infective vesiculobullous lesions of skin. Maximum patients were between 4th and 6th decade of life with male female ratio being close to one.

Corresponding author:

Rashi Garg,
Pandit Deendayal Upadhyay Medical College;
Maharishi Markandeshwar University Solan
Email: rashiigarg@gmail.com

Of 53 cases, pemphigus vulgaris was the commonest (35.8%). Among autoimmune vesiculobullous lesions, pemphigus vulgaris (51.35%) was the commonest, followed by bullous pemphigoid, pemphigus foliaceus,

dermatitis herpetiformis and chronic bullous dermatosis of childhood. Among subepidermal autoimmune bullous lesions, bullous pemphigoid was the commonest. Table 1 lists the frequency of various bullous lesions with sex distribution.

Table 1: Frequency of various bullous lesions with sex distribution

DISEASE	MALE	FEMALE	TOTAL	%
1 Pemphigus vulgaris	09	10	19	35.8
2 Pemphigus foliaceus	05	00	05	9.4
3 Bullous pemphigoid	03	05	08	15.1
4 Dermatitis herpetiformis	03	01	04	7.5
5 Subcorneal pustular dermatosis	02	02	04	7.5
6 Darier's disease	01	03	04	7.5
7 Chronic bullous disorder of childhood	01	00	01	1.9
8 Erythema Multiforme	00	03	03	5.7
9 Irritant contact dermatitis	01	01	02	3.8
10 Hailey-Hailey disease	00	01	01	1.9
11 Epidermolysis bullosa simplex	00	01	01	1.9
12 Lichen planus pemphigoid	01	00	01	1.9
Total	26	27	53	

Oral mucosa was involved in approximately 79% of cases of pemphigus vulgaris.

Histopathological examination was carried out blind foldedly. Lesions were categorised based on the location of the blister. 1) Suprabasal 2) subcorneal 3) and subepidermal. Amongst lesions with suprabasal blister, those with acantholysis were classified as Pemphigus vulgaris (Fig 1B,C,D) and those showing hyperkeratosis and papillomatosis of epidermis, corps ronds, grains and chronic inflammatory infiltrate in dermis were diagnosed as Darier's disease (Fig 2A,B). Lesions showing

subcorneal blister were Pemphigus foliaceus (Fig 1A) and Subcorneal pustular dermatosis with additional features of neutrophils in the pustule and occasional eosinophils along with acantholytic cells (Fig 1F). Subepidermal blister with mixed superficial inflammation were categorised as Bullous pemphigoid (Fig 1E) and those with neutrophilic abscesses in dermal papillae, dermal infiltrate of neutrophils and eosinophils along with subepidermal vesicles were diagnosed as Dermatitis herpetiformis.

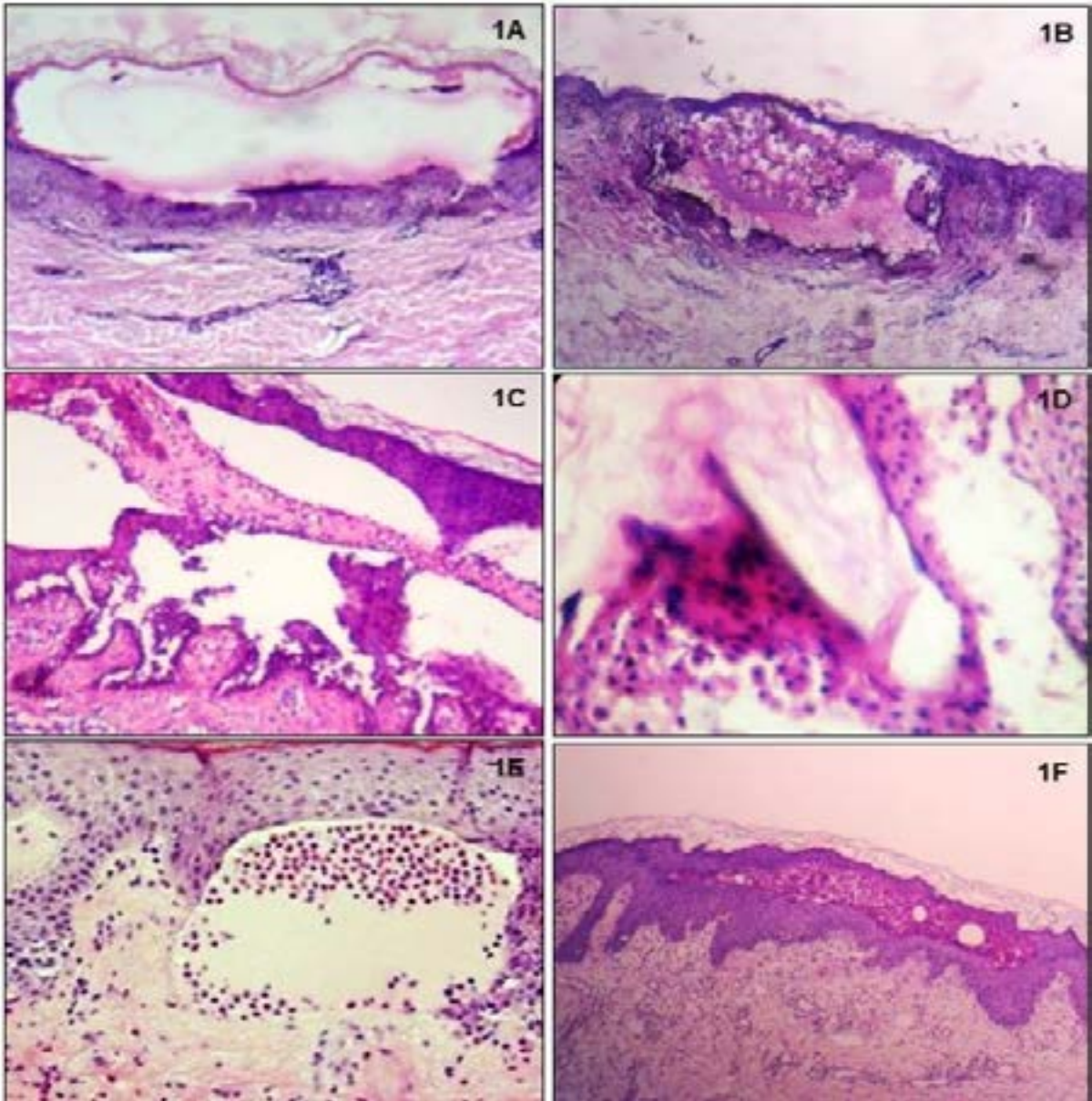


Fig1:A) Pemphigus foliaceus; Subcorneal cleft (40X). B) Pemphigus Vulgaris; Supra basal cleft with inflammatory infiltrate and acantholytic cells (40X) C) Pemphigus Vulgaris; Supra basal cleft with acantholytic cells. (100X) D) Pemphigus Vulgaris; Acantholytic cells. (400X) E) Bullous Pemphigoid; Subepidermal cleft with eosinophils. (100X) F)Subcorneal pustular dermatosis; Sub corneal cleft with neutrophilic infiltrate. (40X)

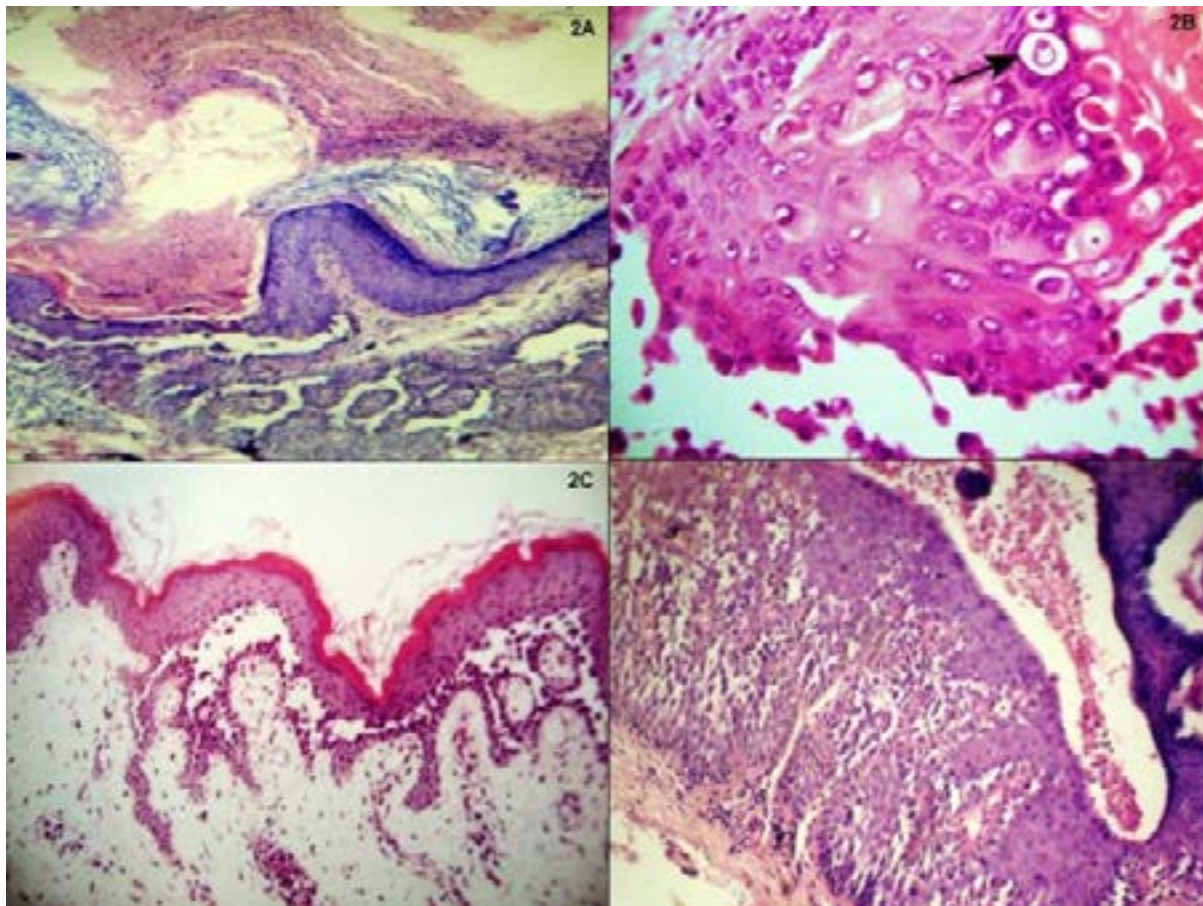


Fig2: A) Darier's Disease; Supra basal cleft with hyperkeratosis and papillomatosis.(40X) B) Darier's Disease; corps and ronds (400X) C) Hailey –Hailey Disease; supra basal cleft. (40X) D) Hailey –Hailey Disease; Dilapidated brick wall appearance (100X)

Other rare lesions seen were Erythema multiforme-subepidermal blister, keratinocyte necrosis, lymphocytic and eosinophilic infiltrate; Epidermolysis bullosa simplex- subepidermal blister with disintegration of basal cell layer; Lichen planus pemphigoid- hyperkeratosis, degeneration of basal cell layer and dermal infiltrate; Chronic bullous dermatosis of childhood- subepidermal separation with neutrophilic infiltration; Irritant contact dermatitis- hyperkeratosis, acanthosis, intraepidermal split with moderate inflammatory infiltrate, predominantly lymphocytes; and Hailey-Hailey disease- suprabasal separation, acantholysis with dilapidated brick wall of detached epidermis (Fig 2C,D).

Of these 53 cases immunofluorescence was obtained in 4 cases from an outside centre and the results were matching with the histopathological findings.

Discussion

Blisters may occur in many forms of dermatosis. At first glance, it seems that blistering is too general or

nonspecific for use in clinical gross evaluation. However the character of blisters in a given disorder tends to be uniform and have reproducible characteristics.¹

Among pemphigus group of diseases, pemphigus vulgaris is the commonest. In present study, pemphigus vulgaris (35.8%) has the highest incidence. Pemphigus vegetans was not observed in this study and is a rare variant of pemphigus group of lesions.¹ Age range of pemphigus vulgaris was 21-60yr. Males and females are equally affected in pemphigus.^{1,3,4} and in this study M:F (male/female) ratio is 1:1.1 Oral mucosa was involved in 78.94% of cases, which is comparable with study of other workers. Cutaneous involvement in pemphigus foliaceus was quite extensive and the clinical picture resembled exfoliative dermatitis. Similar findings were observed by Kanwar et al.⁵ Clinical features varied from multiple vesiculobullous skin lesions containing clear fluid,⁵ symmetrical multiple vesicles on erythematous base with marked pruritus,³ tense bullae arising on inflamed or normal appearing skin, annular pustules in

axillary or inguinal folds, painful erosions and vesico-pustules and scaly erythematous plaques present at sites of friction such as the sides of the neck, the axillae, the groins and the perineum.⁶

Histopathological findings based on the plane of separation along with other observations when correlated with clinical findings/possibilities usually lead to a correct diagnosis. Variable findings in different lesions are described below:

Pemphigus vulgaris: suprabasal blister was observed in all cases. Acantholytic cells seen in the blister are rounded with condensed cytoplasm around an enlarged nucleus.^{7,8,9}

Pemphigus foliaceus: subcorneal blister, acantholysis in upper layers of epidermis and eosinophilic exocytosis in upper epidermis.⁹

Bullous pemphigoid: subepidermal blister with mixed superficial inflammation and edematous changes in the upper epidermis.³

Epidermolysis bullosa simplex: there was only one case of epidermolysis bullosa simplex, in which subepidermal blister with disintegration of basal cell layer was seen. Similar findings were reported by N.I Kiniczak.¹⁰

Dermatitis herpetiformis: subepidermal blister, papillary microabscesses containing neutrophils and eosinophils.¹¹

Erythema multiforme: subepidermal blister with wide spread keratinocyte necrosis and mild lymphocytic and eosinophilic infiltration around necrosed keratinocytes was seen.¹²

Lichen planus: orthokeratosis, wedge shaped hypergranulosis, irregular acanthosis, damage to the basal cell layer and band like lymphocytic infiltrate in the upper dermis was seen. Similar findings have been reported in Lever.¹

Subcorneal pustular dermatosis: subcorneal pustule with neutrophils, occasional eosinophils and acantholytic/pancytolytic cells.^{1,5}

Darier's disease: hyperkeratosis, acanthosis, papillomatosis of epidermis, suprabasal lacunae with few corps ronds and grains.¹³

Chronic bullous dermatosis of childhood: subepidermal bulla containing neutrophils and few eosinophils.¹⁴

Irritant contact dermatitis: intraepidermal blister with hyperkeratosis. Areas of parakeratosis, hypergranulosis and acanthosis were also observed.^{15,16}

Hailey-Hailey Disease: suprabasal blister, acantholysis and detached epidermis at places showing dilapidated brick wall appearance.⁶

Karattuthazhathu A Retal also concluded in there study that morphological diagnosis by histopathology is equally good as immunoflourescence in the diagnosis of vesiculobullous lesions of skin.¹⁷

Conclusion

Most of the results in this study are comparable to other studies. Due to absence of ancillary techniques in many centres and low affordability of many patients (especially in developing countries like India), histopathology is still the only tool for the diagnosis of these lesions. Clinical findings along with good histopathological correlation helps in attaining right diagnosis in most of the cases.

References

1. Elder D, Elenitsas R, Jaworsky C, Johnson B (eds). Lever's Histopathology of the Skin. 10th ed. Philadelphia, Lippincott-Raven. 2009
2. Goldblum JR, Lamps LW, McKenney JK, Myers JL. Rosai and Ackerman's Surgical Pathology. 11th ed. Philadelphia. Elsevier Inc. 2018
3. Bickle K, Roark TR, Hsu S. Autoimmune Bullous Dermatitis: A Review. *Am Fam Physician*. 2002 ;65:1861-1870. PMID:12018809
4. Shafi M, Khatri ML, MashinaM, Ben-Ghazel M. Pemphigus: A clinical study of 109 cases from Tripoli, Libya . *Indian J Dermatol Venereol Leprol*. 1994;60: 140-143.
5. Kanwar AT, Singh M, Ei-Mangoush IM, Bharija SC, Belhaj MS. Clinical pattern of bullous disorders in Eastern Libya. *Ind.J. DermatolVenereol Leprol*.1987; 53:337-339. PMID:28145348
6. Yordanova I, Gospodinov D, Chavdarova V. Familial benign chronic pemphigus (Hailey-Hailey disease). *J of IMAB*. 2007;13:60-62.
7. Shamim T, Varghese VI, Shameena PM, Sudha S. Oral pemphigus vulgaris :clinicopathologic study of 20 cases. *Indian J Pathol and Microbiol*, 2007; 50:498-501. PMID:17883117
8. Leena, Vijaya B, Manjunath G V, Sunila.A. Clinicopathological Study Of 22 Cases Of Pemphigus. *JCDR*, 2010; 4:2446-2451.
9. Arya SR, Valand AG, Krishna K A. Clinicopathological study of 70 cases of pemphigus. *Indian J Dermatol Venereol Leprol* 1999;65: 168-71. PMID: 20921646
10. Kihiczak NI, Papadopoulos AJ, Schwartz RA and Janniger CK. Epidermolysis bullosa hereditaria simplex. Case report. *Actadermatoven APA*. 2001;10:24-29.
11. Caproni M, Feliciani C, Fuligni A, Salvatore E, Atani L, Bianchi B,etal. Th2-like cytokine activity in dermatitis herpetiformis. *Br J Dermatol*.1998;138: 242-247. DOI: 10.1046/j.1365-2133.1998.02068.x

12. Michele R, Lamoreux, Marna.R, Sternbach, W, Tessa.Hsu. Erythema Multiforme. *Am Fam Physician*.2006; 74:1883-88. PMID:17168345
13. Peck GL, Kraemer KH, Wetzell B, Klingler WG, Cohen K. Cornifying Darier Disease— A Unique Variant. Report of a case. *Arch Dermatol*, 1976;112:495-503. PMID:1267453
14. Fisler RE, Saeb M, Liang MG, Howard RM, McKee PH. Childhood bullous pemphigoid: a clinicopathologic study and review of the literature. *Am J Dermatopathol*.2003; 25: 183-9. PMID:12775979
15. Hicks SP, Swindells KJ, Middelkamp-Hup MA, Sifakis MA, González E, González S. Confocal histopathology of irritant contact dermatitis in vivo and the impact of skin color (black vs white). *J Am Acad Dermatol*, 2003;48:727-34. DOI:10.1067/mjd.2003.220
16. Jovanovi DL, Petrovi A, Paravina M, Stanojevi M, Bini I. Chronic contact allergic and irritant dermatitis of palms and soles: routine histopathology not suitable for differentiation. *Acta Dermatoven APA*,2003; 12:127-130.
17. Karattuthazhathu AR, VilaSiniamma L, Poothiode U. A Study of Vesiculobullous Lesions of Skin. *NJLM* ,2018;7:1-6 DOI: 10.7860/NJLM/2018/29611:2266