

Generalized lymphadenopathy: an unusual presentation of burkitt lymphoma in a Nigerian child: a case report

Osita U Ezenwosu¹, Barth F Chukwu¹, Okechukwu C Okafor², Anthony N Ikefuna¹, Ifeoma J Emodi¹

1. Department of Paediatrics, University of Nigeria, Enugu Campus, Enugu, Nigeria
2. Department of Pathology, University of Nigeria, Enugu Campus, Enugu, Nigeria

Emails:

Barth Chukwu: chizzy_bath@yahoo.com, Okechukwu Okafor: okechukwu.okafor@gmail.com, Anthony Ikefuna: nnaaikefuna@yahoo.com, Ifeoma Emodi: ifeoma_emodi@yahoo.com

Abstract

Introduction: Burkitt Lymphoma is the fastest growing tumor in human and the commonest of the childhood malignancies. Generalized lymphadenopathy is a common feature of immunodeficiency associated Burkitt lymphoma but an uncommon presentation of the endemic type in Human Immunodeficiency Virus (HIV) negative children.

Case presentation: The authors report a 6 year old HIV negative boy who presented with generalized lymphadenopathy, cough, weight loss, fever and drenching night sweat and had received native medication as well as treatment in private hospitals. His examination revealed hepatosplenomegaly, bull neck with generalized significant massive lymphadenopathy. Diagnosis was missed initially until a lymphnode biopsy for histology confirmed Burkitt lymphoma. He was managed on combination chemotherapy with complete resolution and now on follow up.

Conclusion: To the best of our knowledge, this is the first documented report of its kind of endemic Burkitt lymphoma involving lymphnodes generally as the primary site. High index of suspicion and early biopsy are the key in this uncommon presentation.

Keywords: Burkitt lymphoma, generalized lymphadenopathy, Nigerian child.

DOI: <https://dx.doi.org/10.4314/ahs.v19i4.49>

Cite as: Ezenwosu OU, Chukwu BF, Okafor OC, Ikefuna AN, Emodi IJ. Generalized lymphadenopathy: an unusual presentation of Burkitt lymphoma in a Nigerian child: a case report. *Afri Health Sci.*2019;19(4):3249-3252. <https://dx.doi.org/10.4314/ahs.v19i4.49>

Introduction

Childhood malignancies constitute a major cause of mortality in developed countries of the world.^{1,2} In the developing countries, though ranking lower than infections and malnutrition, it contributes to childhood morbidity and mortality.²

Burkitt Lymphoma (BL) is the fastest growing tumor in human with peak duration of about 4 weeks.³ In sub-Saharan Africa, BL is still the commonest of the childhood malignancies,^{4,5} and comprised of 3 types – endemic,

sporadic and immunodeficiency associated types.⁶ The endemic BL involves the facial bones viz mandible, maxilla, and orbital bones while the sporadic tends to affect the lymphoid tissues of the gut and presenting with abdominal involvement.⁶ Aside these, involvement of other sites have been noted which includes the breast, ovaries, thyroid, testis, skin as well as presentation as leukemia.⁷ The immunodeficiency-associated variant of BL occurs as a result of immunosuppression and is expectedly associated with generalized lymphadenopathy.⁶ However, BL presenting with generalized lymphadenopathy in the absence of immunodeficiency is usually seen in adults.⁶ We report an unusual case of a 6 year old Human Immunodeficiency Virus (HIV) negative boy who presented with generalized lymphadenopathy which was histologically diagnosed as BL with good response to appropriate chemotherapy. The need for early histologic diagnosis especially in developing countries is highlighted.

Corresponding author:

Osita Ezenwosu,
Department of Paediatrics, College of Medicine,
University of Nigeria, Enugu Campus, Nigeria.
Phone number: +234-803-6679-730
E-mail: osita.ezenwosu@unn.edu.ng

Case report

A.G. is a 6 year old male who presented with neck, axillary and groin swellings of 1 month; cough of 1 month; weight loss, fever and drenching night sweat of 2 weeks duration. Swellings have been progressively increasing in size over 1 month. He received native medications and treatment in two different private hospitals before being referred to our centre due to worsening symptoms. There was no past history of similar illness, admission or transfusion.

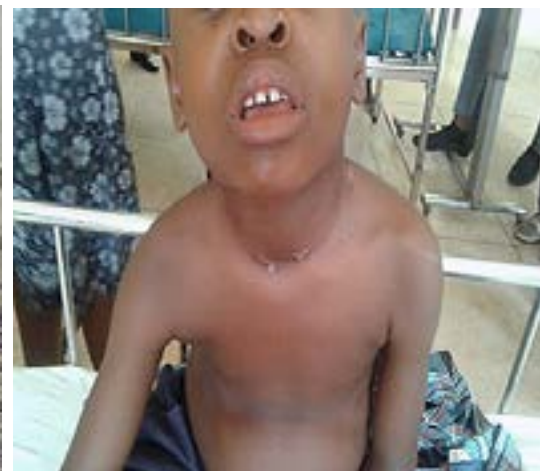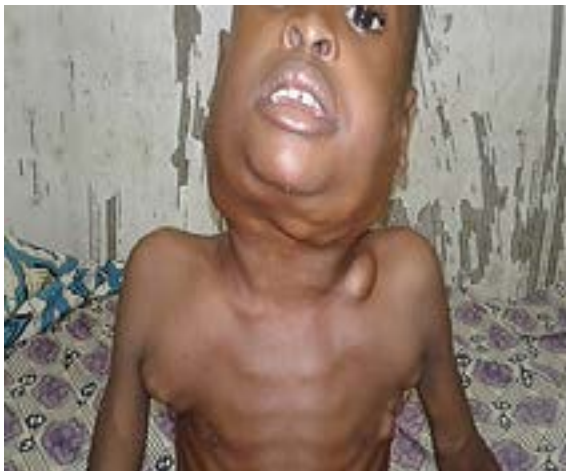Physical examination showed an acute on chronically ill-looking child in respiratory distress, mildly pale with significant generalized lymphadenopathy (cervical, submandibular, submental, axillary, inguinal), febrile (Temperature 38°C) and no peripheral oedema. Positive findings on systemic examination were hepatomegaly 5cm, splenomegaly 4cm, bull neck with mixed matted and solitary firm, tender lymphadenopathy of varying sizes. A provisional diagnosis of Tuberculous Adenitis was made with lymphoproliferative disorder and Hodgkins Lymphoma as possible differentials.

Investigations done included Full Blood Count (FBC) showing mild anaemia (Hb 10.1g/dl), WBC with lym-

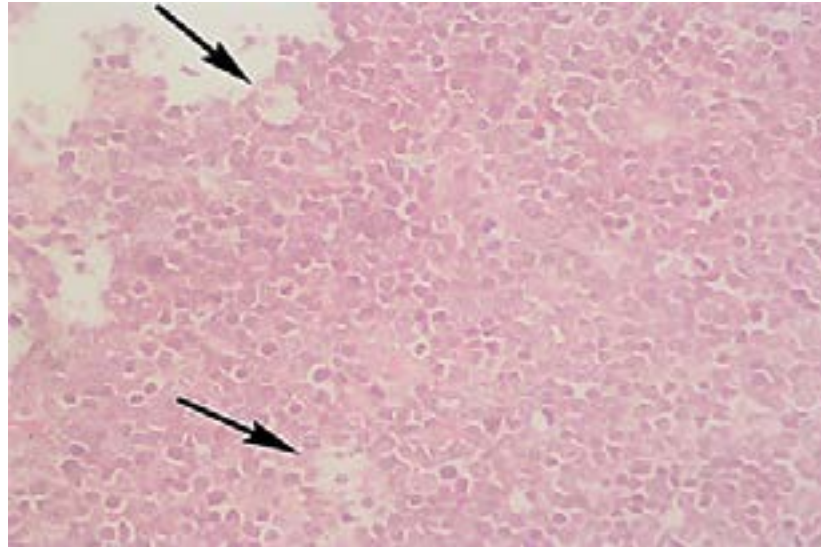
phocytosis. Retroviral screening and mantoux test were negative. Chest X-ray showed mediastinal, perihilar and hilar lymphadenopathy as abdomino-pelvic ultrasound revealed multiple abdomino-pelvic lymphnodes.

About 10 days on admission, he started mouth-breathing with bulging soft palate and reduced airflow via nasal cavity. Additional diagnosis of upper airway obstruction secondary to airway compression was made and he had tracheostomy. Lymphnode histology report obtained on the 16th day of admission revealed the characteristic starry sky appearance of Burkitt Lymphoma.

Chemotherapy was commenced on the 19th day of admission (after work up) using the National Guideline Protocol8 consisting of 2 weekly COMP regimen (iv Cyclophosphamide, Oncovin, Methotrexate and oral Prednisolone) at adequate doses as well as weekly prophylactic intrathecal methotrexate. After the first course of chemotherapy, there was marked reduction of swellings. Following second course, tracheostomy tube was de-cannulated and he was discharged home. He subsequently completed 6 courses of the regimen and 6 doses of weekly intrathecal methotrexate following which symptoms completely resolved. He is currently on 3monthly follow up visit.



A.G. before and after chemotherapy



Micrograph of the Histology of A.G. H&E, X400. There is a diffuse proliferation of small-sized cells with scanty cytoplasm giving a "starry-sky" appearance; the "stars" corresponding to large tingible-body macrophages with abundant pale cytoplasm (black arrows) which engulf necrotic tumour debris.

Discussion

BL remains the commonest childhood malignancy in the tropics,^{4,5} where the endemic variety is mostly seen due to its link with malaria and Epstein Barr Virus (EBV) infections.⁷ It occurs commonly in children between the ages of 5 and 15 years with peak age incidence of 5-7 years^{7,8} to which our patient belongs. Typical painless swelling of endemic BL involves the mandible, maxilla and orbital bones with/without intra-oral extension as well as possible looseness or mal-alignment of the teeth.^{6,7} Abdominal organs and nodes are the known organs of involvement in sporadic BL.⁶ Recently, immunodeficiency-associated BL was introduced to classify those with BL arising as a result of immunosuppression especially HIV.^{6,9} The features in this variety of BL are those of BL and HIV combined.

Unlike the characteristic features of BL noted by several authors,^{3,5-7} our patient presented with atypical features (including cough, weight loss, generalized lymphadenopathy, pallor, fever, hepatosplenomegaly) which varied distinctly from other atypical presentations noted by workers from different parts of the world.¹⁰⁻¹² Atypical features undoubtedly result in mis-diagnosis and in cases where diagnosis were made, it will rather give rise to delayed diagnosis. Mis-diagnosis and delayed diagnosis will result in health system delay and ultimately prolong the lag time. These all have association with prognosis and economic cost of cancer management.¹³ Our patient's unusual pre-

sentation resulted in initial mis-diagnosis, though, biopsy for histologic confirmation was requested then.

Following tissue biopsy, histologic examination using Hematoxylin and Eosin (H&E) is employed in the diagnosis of BL. Lukande and colleagues¹⁴ had documented a high reliability of H&E in the diagnosis of BL while immunohistochemistry is advised for cases with equivocal morphologic findings. However, as the latter is not readily available in resource-limited settings, histology still remains the gold standard.¹⁴ Our patient had diagnosis made on the basis of H&E histologic examination. Early histology leads to early diagnosis which remains a key factor in paediatric oncology as it allows for early detection and timely treatment.¹³

Different malignancies have different characteristic histologic finding. For BL, finding of the typical starry sky appearance on histology supports the diagnosis. This was the finding in our patient as well as that of previous workers.¹⁵⁻¹⁷ After histologic result, it is the consensus that chemotherapy be commenced promptly and in combination. Diverse combination chemotherapy have been used in the past while new ones evolve.¹⁸⁻²⁰ Considering availability and affordability, COMP regimen (consisting of iv Cyclophosphamide, Oncovin, Methotrexate and oral Prednisolone), is still recommended for use in resource-limited centres and remains a viable and effective strategy in such settings as was the experience of Da-

vidson et al²¹ in South Africa. This was corroborated in our patient who showed complete resolution following COMP regimen and is doing well on follow up.

Conclusion

Atypical presentation of BL is associated with delayed diagnosis leading to prolonged lag time and health system delay. These have potential negative effects on the prognosis as well as worsen the economic burden of the malignancy. Therefore, a high index of suspicion and early biopsy for histology will reduce these potential impacts especially in resource-limited settings.

Declaration of interest

The authors declare absence of conflict of interest in the manuscript.

References

1. Bunch KJ, Stiller CA. Childhood cancer mortality. In: Stiller CA, ed. *Childhood cancer in Britain: incidence, survival, mortality*. 1st ed. New York: Oxford University Press; 2017: 205-238.
2. White Y, Castle VP, Haig AH. Pediatric oncology in developing countries: challenges and solutions. *J Pediatr* 2013; 162: 1090-1091 PubMed .e1
3. Mwanda OW. Clinical characteristics of Burkitt Lymphoma seen in Kenyan patients. *East Afr M J* 2004; 8Suppl: S78-89.
4. Chukwu BF, Ezenwosu OU, Ikefuna AN, Emodi IJ. A prospective study of childhood malignancy in Enugu, Eastern Nigeria (2011-2013). *Niger J Paed* 2015; 42: 116-120. PubMed
5. El-Mallawany NK, Mercy Mutai CO, Idah Mtete CO, Gopal S, Stanley CC, Wasswa P et al. Beyond endemic Burkitt Lymphoma: navigating challenges of differentiating childhood lymphoma diagnoses amid limitations in pathology resources in Lilongwe, Malawi. *Global Pediatr Health* 2017; 4: 1-12.
6. Chatterjee T, Gupta D, Bharadraj R, Madan R. Burkitt's Lymphoma revisited: series of three cases with varied clinical presentation. *Indian J Hematol Blood Transf* 2014; 30: 215-218.
7. Adimora GN, Ikefuna AN, Ejekam GC. Childhood tumours. In: Azubike JC and Nkanginieme KEO, eds. *Paediatric and child health in a tropical region*. 2nd ed. Owerri: *African Educational Series*; 2007: 657-665.
8. FMOH. National Guideline on Cancer Chemotherapy 2009. Pg. 18.
9. Ferreira JM, Klumb CE, de Souza Reis R, de Oliveira Santos M, Oliveira JF, de Camargo B et al. Lymphoma subtype incidence rates in children and adolescents: first report from Brazil. *Cancer Epid* 2012; 36: e221-e226.
10. Ziade F, von der Weid N, Beck-Popovic M, Nydegger A. Burkitt lymphoma – an atypical presentation. *BMC Pediatrics* 2012; 12: 13.
11. Bokka SH, Mohammed F, Shama S, Mohanty MK. An unknown presentation of Burkitt's lymphoma as a primary gastrointestinal tumor causing intussusception: a case report with review of literature. *Clin Cancer Investig J* 2015; 7: 467-469. PubMed.
12. Ryczer T, Zawadzka-Glos L. A rare case of Burkitt's lymphoma in paranasal sinuses in a child. *New Medicine* 2014; 4: 122-125. PubMed.
13. Chukwu BF, Ezenwosu OU, Ikefuna AN, Emodi IJ. Diagnostic delay in pediatric cancer in Enugu, Nigeria: a prospective study. *Pediatr Hematol Oncol* 2015; 32: 164-171.
14. Lukande R, Wabinga HR, Tumwine LK. Burkitt's lymphoma in Uganda: the role of immunohistochemistry in diagnosis. *East Afr Med J* 2008; 85: 207-212. PubMed.
15. Bakari A, Ahmad BM, Mohammed GM, Abubakar TS. Life threatening retropharyngeal Burkitt's lymphoma mimicking adenoid obstruction disease. *Ann Nig Med* 2013; 7: 35-37. PubMed.
16. Lu Sc, Shen WL, Cheng YM, Chon CY, Kuo PL. Burkitt's lymphoma mimicking a primary gynecologic tumor. *Taiwanese J Obstet Gynecol* 2006; 45: 162-166.
17. Maka V, Harish K. Multiple chest wall swellings in adult Burkitt's lymphoma 2014; 384; 2224.
18. Stanley CC, Westmoreland KD, Heimlich BJ, El-Mallawany NK, Wasswa P, Mtete I et al. Outcomes for paediatric Burkitt lymphoma treated with anthracycline-based therapy in Malawi. *Br J Haematol* 2016; 173: 705-712. PubMed.
19. Bonnet C, Janssens A, Wu KL, Schroyens W, Hende VV, Heimann P et al. BHS guidelines for the treatment of Burkitt's lymphoma. *Belg J Hematol* 2015; 6: 61-69. PubMed.
20. Hoelzer D. Dose-adjusted EPOCH-R for Burkitt lymphoma. *Clin advances in Haematol Oncol* 2014; 12: 777-779.
21. Davidson A, Desai F, Hendricks M, Hartley P, Millar A, Numanoglu A, Rode H. The evolving management of Burkitt's lymphoma at Red Cross Children's Hospital. *SAMJ* 2006; 96: 950-954. PubMed.