

Stigma and increase of leprosy cases in SouthEast Sulawesi Province, Indonesia

Ramadhan Tosepu¹, Joko Gunawan², Devi Savitri Effendy¹, Fitri Rachmillah Fadmi³

1. Faculty of Public Health, University of Halu Oleo Kendari, Indonesia.
2. Akademi Keperawatan Pemerintah Kabupaten Belitung, Indonesia
3. Sekolah Tinggi Ilmu Kesehatan Mandala Waluya Kendari, Indonesia

DOI: <https://dx.doi.org/10.4314/ahs.v18i1.5>

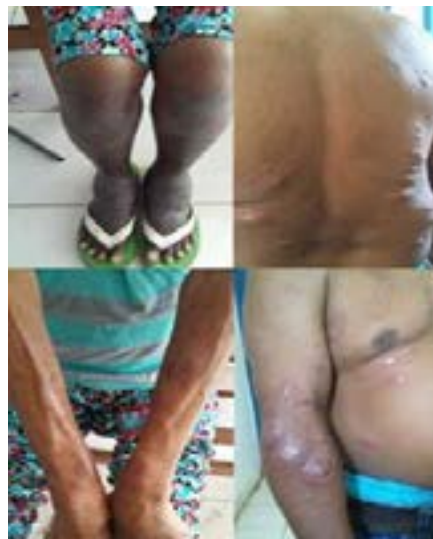Cite as: Tosepu R, Gunawan J, Effendy DS, Fadmi FR. Stigma and increase of leprosy cases in Southeast Sulawesi Province, Indonesia. *Afri Health Sci* 2018;18(1):29-31. <https://dx.doi.org/10.4314/ahs.v18i1.5>

Dear Editor,

Leprosy remains an important health issue. The disease is characterised by a chronic granulomatous infection of the skin and peripheral nerves caused by *Mycobacterium leprae*. The disease is classified into two, namely paucibacillary (PB) or multibacillary (MB) leprosy. PB leprosy is a milder form of disease, characterized by several (ie, up to five) hypopigmented, pale and reddish lesions, and hypo- or anesthetic lesions. MB leprosy is associated with

several skin lesions that manifest as nodules, plaques, or diffuse skin infiltration¹⁻³.

Globally, India, Brazil, and Indonesia are the three countries with scattered populations reporting over 10,000 (81%) of new patients each year, which indicated that the world is demanded to make a great progress towards the goal of eliminating leprosy⁴. In this short article, the authors report the leprosy cases in SouthEast Sulawesi province as the highest case of leprosy in Indonesia.



Correspondence author:

Ramadhan Tosepu,
Faculty of Public Health, University of Halu Oleo
Kendari, Indonesia.
Email: adhan_lpmi@yahoo.co.id

In 2015, the prevalence of leprosy in the province was 1.25 / 10.000 population, with new 275 cases of MB leprosy and 28 new cases of PB leprosy (see Figure 1)⁵. The spread of the disease is present in all districts in the province of SouthEast Sulawesi (see Figure 2). This condition however resulted in great stress on the community due to the stigma in the province.

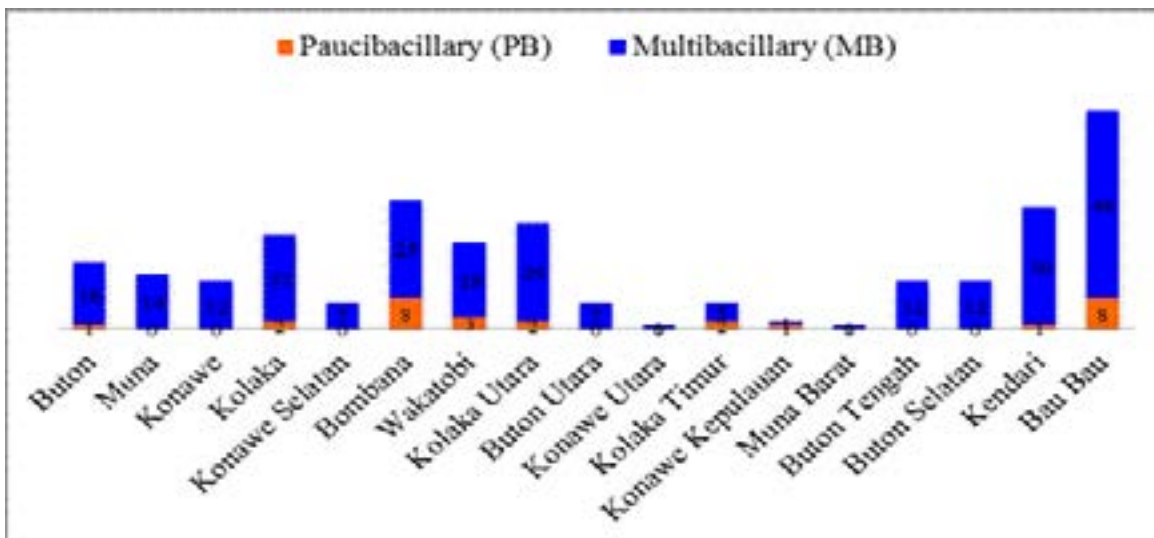


Figure 1: The new cases based on the leprosy type Southeast Sulawesi province (2015) (5)

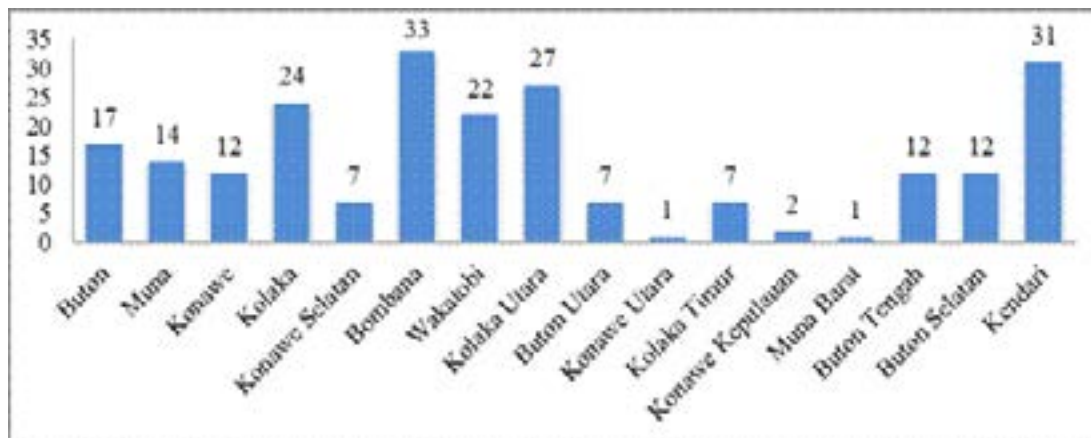


Figure 2: Distribution of leprosy by District in Southeast Sulawesi Province, Indonesia in 2015 (5)

Although leprosy is the oldest disease known to man⁶, leprosy-related stigma is still very strong in the society in the SouthEast Sulawesi Indonesia. It is believed to be inherited and associated with ideas of unclean blood, which is shameful and not accepted normally in society. However, that stigma affects the lives of the people affected by leprosy and inhibits the treatment process, and might lead to progressive leprosy, resulting in permanent damage to the skin, nerves, limbs and eyes³. Some studies have concluded that stigma affects many aspects of the lives of people affected by leprosy including mobility, interpersonal relationships, marriage, employment, leisure activities, and attendance at social and religious functions⁷. If

the stigma about leprosy is not changed, then it will be difficult to eliminate leprosy as a public health problem and the incidence might be increased.

Thus, this condition calls for the role of public health to set up the strategy in Indonesia, particularly in the province of SouthEast Sulawesi to eliminate the increase of leprosy and to fight stigma. These focused on 1) Increasing early case detection in the community; 2) Improving the quality of leprosy services, including rehabilitation services that are integrated with basic health care and referrals; 3) Changing the image of the disease that leprosy is curable by disseminating information or media campaigns; 4) The elimination of stigma by increasing the

knowledge of the disease; 5) Empowering those who have experienced leprosy in various aspects of life, and strengthening their participation in controlling leprosy; 6) Restoring self-esteem; and 7) Developing program that prevents disabilities or permanent damage⁸.

Conflict of interest

We declare that we have no conflict of interest.

References

1. Barham K, Jorizzo J, Grattan B, Cox N. Vasculitis and neutrophilic vascular reactions. *Rook's Textbook of Dermatology*, Seventh Edition. 2004:2395-440.

2. Walker S, Lockwood D. The clinical and immunological

features of leprosy. *British Medical Bulletin*. 2006;77(1):103-21.

3. Ali K, Sittampalam G, Malik MA. Facial tuberculoid leprosy: case report. *British Journal of Oral and Maxillofacial Surgery*. 2011;49(1):70-2.

4. Organization WH. Global Leprosy Strategy 2016-2020: Accelerating towards a leprosy-free world. 2016.

5. Tenggara DPS. Health Profile of SouthEast Sulawesi Year 2014-2015. Kendari; 2015.

6. Luka EE. Understanding the stigma of leprosy. *South Sudan Medical Journal*. 2010;3(3):45-8.

7. van Brakel WH. Measuring leprosy stigma-a preliminary review of the leprosy literature1. *International Journal of Leprosy and Other Mycobacterial Diseases*. 2003;71(3):190.

8. Indonesia KK. Profile of Health Indonesia, 2015. 2016.