

# Intestinal ameliorative effects of traditional *Ogi-tutu*, *Vernonia amygdalina* and *Psidium guajava* in mice infected with *Vibrio cholera*.

Olufunke B Shittu<sup>1</sup>, Olusola L Ajayi<sup>2</sup>, Samuel O Bankole<sup>3</sup>, Temitope OS Popoola<sup>1</sup>

1. Department of Microbiology, College of Biosciences, Federal University of Agriculture, Abeokuta, Nigeria.
2. Department of Veterinary Pathology, College of Veterinary Medicine, Federal University of Agriculture, Abeokuta, Nigeria.
3. Department of Pure and Applied Zoology, College of Biosciences, Federal University of Agriculture, Abeokuta, Nigeria.

## Abstract

**Background:** Cholera, a severe acute watery diarrhea caused by *Vibrio cholerae* is endemic in Nigeria with most cases occurring in the rural areas. In South West Nigeria, some individuals resort to alternative treatments such as *Ogi-tutu*, *Psidium guajava* and *Vernonia amygdalina* during infections. The effectiveness of these alternatives in the prevention and treatment of *V. cholerae* infection requires experimental investigation.

**Objective:** This study was designed to investigate the ameliorative effects of *Ogi-tutu*, *Vernonia amygdalina* and *Psidium guajava* on intestinal histopathology of experimental mice infected with *V. cholerae*.

**Methods:** Preliminary investigation of *in vitro* vibriocidal activities of these alternatives were carried out using agar cup diffusion assay. For ameliorative effects, adult mice were inoculated with 100  $\mu$ l (106 cells) of *Vibrio cholerae* and dosed at 0 h (immediate prevention) and 4 h (treatment of infection) and their intestines were histopathologically evaluated.

**Results:** The histopathological changes were the same irrespective of the treated groups, but the lesions varied in extent and severity. The ameliorative effects in decreasing order were *V. amygdalina* > *P. guajava* > *Ogi-tutu*.

**Conclusion:** *V. amygdalina* gave the best ameliorative effects in the prevention and treatment of *V. cholerae* infection.

**Keywords:** *Vibrio cholerae*, *Ogi-tutu*, *Psidium guajava*, *Vernonia amygdalina*.

**DOI:** <http://dx.doi.org/10.4314/ahs.v16i2.33>

**Cite as:** Shittu OB, Ajayi OL, Bankole SO, Popoola TOS. Intestinal ameliorative effects of traditional *Ogi-tutu*, *Vernonia amygdalina* and *psidium guajava* in mice infected with *Vibrio cholera*. *Afri Health Sci* 2016;16(2): 620-628. <http://dx.doi.org/10.4314/ahs.v16i2.33>

## Introduction

*Vibrio cholerae* is a human pathogen that causes a severe acute watery diarrhea called cholera, a waterborne disease characterized by severe dehydration<sup>1,2</sup>. *Vibrio cholerae* is a major public health problem because of its epidemic potential<sup>3</sup>. Though, there are approximately 200 serotypes, only *V. cholerae* O1 and O139 have been found in epidemic and pandemic cholera<sup>4</sup>. Without treatment, the case fatality rate for severe cholera can be as high as 50%<sup>5</sup>.

Nigeria is in one of the three major cholera foci in the world, with frequent outbreaks and epidemics from different parts of the country<sup>6</sup>. In South West Nigeria, majority of the people living in rural areas use traditional medicines to treat all types of diarrhea<sup>7</sup>. This is in line with the World Health Organization (WHO) estimates of approximately 80% of the world's inhabitants that rely on traditional or herbal medicines for their primary health care<sup>8</sup>.

Regarded as traditional remedy for diarrhea and specifically for the treatment of cholera, is the use of "*ogi-tutu*" and this is acclaimed to stop the characteristic cholera symptoms. *Ogi-tutu* is the wet cake mixed with *omidun* (sour-water)<sup>9-10</sup>. *Ogi* is a porridge prepared from fermented maize, sorghum or millet in West Africa<sup>11</sup>. *Ogi* may have potentials for treatment of diarrhea, due to its high level of lactic acid bacteria (LAB)<sup>10</sup>.

Also, several plants are used locally in the treatment of diarrhoea<sup>11-14</sup>. *Psidium guajava* L. and *Vernonia amygdalina*<sup>15-16</sup>

### Corresponding author,

Olufunke B Shittu,  
Department of Microbiology,  
College of Biosciences,  
Federal University of Agriculture,  
Abeokuta, Nigeria  
Tel: +234-803-353-2640  
Email: olufunke\_b@yahoo.com

are two of such plants that are used in SouthWest Nigeria. *Vernonia amygdalina* is a dark green vegetable known as bitter leaf in English, and ewuro in Yoruba land<sup>17</sup>. The roots and leaves are used in phytomedicine to treat fever, hiccups, kidney disease and stomach discomfort, and as antihelminthic and antimalarial<sup>13</sup>. *Psidium guajava* L. commonly known as guava of the family Myrtaceae is a plant used in the indigenous system of medicine for the treatment of various human ailments such as wounds, ulcers, bowels and cholera<sup>18</sup>. The plant is also known for its antidiabetics, antispasmodic, antidiarrheal and antidysentery properties<sup>19-20</sup>. Empirical proof of these traditional treatments in ameliorating histopathological effects of *Vibrio cholerae* in the intestinal mucosa need to be investigated.

## Methods

### Study design

A randomized controlled experimental design was used in this study. Ethical approval for the study was obtained from the Research and Ethical Committee, Department of Microbiology, College of Biosciences, Federal University of Agriculture, Abeokuta, Nigeria through Research Proposal Presentation and Approval (Approval number: 2005/06/01/01).

### Vibrio cholerae strains

Toxigenic strain of *V. cholerae* isolated from an epidemic case in Nigeria was used for the study. A loopful of the working stock was transferred into 3 ml Tryptone Soy Broth (TSB, Oxoid) containing NaCl at final concentration of 3% (Na-TSB broth) and incubated at 37°C for 18 h. Before inoculation, *V. cholerae* was grown in Luria Bertani (LB) broth containing ampicillin (50µg) and Streptomycin (50µg) at 37°C on a roller shaker for 16 to 18 hrs.

### Preparation of Ogi-tutu

Corn-Ogi, was prepared by spontaneous traditional fermentation. Ogi slurry was prepared by adding 100 ml of sour water (*omidun*) to 50 g of *ogi* cake and then, mixed thoroughly. A hundred milliliters (100 ml) slurry of *ogi* was measured into sterile 250 ml Erlenmeyer flask. Before inoculation, the *ogi* slurry samples were maintained at experimental temperature (37°C) for 1 to 2 hrs to allow for equilibration<sup>21</sup>.

### Source of Vernonia amygdalina extract and Psidium guajava decoction

Fresh leaves of each plant were purchased from herb sellers at Itoku market in Abeokuta, Ogun State, Nigeria. Voucher specimens were taken to the Herbarium Unit of the Department of Forestry and Wildlife Management, Federal University of Agriculture, Abeokuta. *Vernonia amygdalina* was classified as Asteraceae Grp 1 and *Psidium guajava* L. as Myrtaceae Grp 1. Herbarium sample specimens were deposited with voucher numbers FUNAAB/FWM/HU/Asteraceae 1/005 and FUNAAB/FWM/HU/Myrtaceae 1/030.

### Traditional Preparation of Vernonia amygdalina extract and Psidium guajava decoction

Raw extract of *Vernonia amygdalina* was obtained by crushing 100 g using sterile mortar and pestle. Decoction of *Psidium guajava* was prepared by boiling 100 g of the shade dried leaves in 100 ml distilled water till the volume was reduced to 25ml. The resulted extracts were centrifuged and filtered through a membrane of 0.22 µm pore size before use for investigation.

### Procedure for ethanolic extraction of Vernonia amygdalina and Psidium guajava

The leaves were dried at 40°C in the hot-air oven, powdered and stored in an airtight container for use. The powders were then soaked in 50% redistilled (aqueous) ethanol in a glass container for 48 h. This was followed by filtration. The filtrate was concentrated to dryness using water bath at 40°C and finally in a dessicator unit.

### Preliminary vibriocidal activity by agar diffusion cup plate assay

Agar diffusion method was used to evaluate the vibriocidal activity of the extracts using 100 µl of extracts. Diameters of zones of inhibition were measured to the nearest millimeter.

### Oral inoculation of mice

Adult mice (7 to 10 weeks old) were purchased from the Department of Veterinary Physiology, University of Ibadan, Nigeria and transported to the experimental unit of the Department of Pure and Applied Zoology, College of Biosciences, Federal University of Agriculture,

Abeokuta, Nigeria where they were left to acclimatize for 72 hrs. During the period of acclimatization, animals were treated by following strictly, the principles of laboratory animal care” (NIH Publication No. 85-23) and mice were fed with pelleted feed and water *ad libitum*.

Prior to *V. cholerae* inoculation, the animals were fasted for 24 hrs prior to the experiment and were randomly divided into ten groups, with three animals per group. Eight groups were inoculated orally with 100µl (106 cells) of toxigenic *V. cholerae* via syringe while the ninth and tenth group served as uninoculated control group. Out of the eight inoculated groups, only six were dosed with *ogi-tutu* (500 mg/ml), ethanolic extracts of *P. guajava* (250 mg/kg) and *V. amygdalina* (250 mg/kg), three groups at 0 hrs (immediate prevention) and three groups at 4 hours (treatment of infection). The remaining two untreated groups were given only distilled water and they served as infected but not treated positive control. Each treated group of animal was monitored for 24 h after which they were sacrificed. However, the uninfected control group (negative control) was sacrificed at 0 hrs and 4 hrs for histopathological comparison. Also, the infected but untreated group (positive control) at 0 hrs was also sacrificed immediately while the delayed group was sacrificed after 24 hrs.

#### **The summary of the experimental treatment groups:**

**Group 1:** Inoculated orally with *V. cholerae*; dosed with *Ogi-tutu* at 0 hrs; sacrificed at 24 hrs

**Group 2:** Infected with *V. cholerae*; dosed with *Ogi-tutu* at 4 hrs; sacrificed at 24 hrs

**Group 3:** Infected with *V. cholerae*; dosed with *V. amygdalina* at 0 hrs; sacrificed at 24 hrs

**Group 4:** Infected with *V. cholerae*; dosed with *V. amygdalina* at 4 hrs; sacrificed at 24 hrs

**Group 5:** Infected with *V. cholerae*; dosed with *P. guajava* at 0 hrs; sacrificed at 24 hrs

**Group 6:** Infected with *V. cholerae*; dosed with *P. guajava* at 4 hrs; sacrificed at 24 hrs

**Group 7:** Infected with *V. cholerae*; untreated (positive control); sacrificed at 0 hrs

**Group 8:** Infected with *V. cholerae*; untreated (positive control); sacrificed at 24 hrs

**Group 9:** Not infected (Normal negative control); sacrificed at 0 hrs

**Group 10:** Not infected (Normal negative control); sacrificed at 4 hrs representing 4 hrs

#### **Routine histopathology**

Mice intestinal samples were eviscerated and harvested after 24 hour. These were immediately washed briefly in phosphate buffered saline (PBS) and then fixed in buffered 10% formalin. After 48 h, the intestinal tissues were trimmed and dehydrated in graded levels of alcohol (50%, 70%, 80% and 100%) and cleared in two changes of xylene. Tissues were embedded in paraffin wax, sectioned at 5 µm and stained with haematoxylin and eosin stains. The stained specimens were further dehydrated in graded levels of ethanol and cleared in xylene. The photomicrographs of the tissues were viewed and taken under light microscope (Leica, UK).

The degree of intestinal histopathological changes were semi-quantified depending on the severity and distribution of the intestinal lesions. Histopathological changes such as degeneration and necrosis of enterocytes, inflammatory cellular infiltration in the lamina propria, regeneration of enterocytes, stumpy and club-shaped villi and goblet cell hyperplasia were scored or assigned as follows: (–) = absent, (+) = 1 to 4 foci/section examined, (++) = 5 to 8 foci/section examined, (+++) = > 9 foci/section examined.

#### **Results**

##### **Preliminary investigation of vibriocidal activities**

The three traditional treatment proved effective at preliminary investigation as displayed in clear halos of growth inhibition of *Vibrio cholerae*. Also, both the traditional and 50% ethanolic extracts of *V. amygdalina* and *P. guajava* exhibited similar inhibitory activities.

##### **Histopathology of Ogi-tutu, Psidium guajava and V. amygdalina**

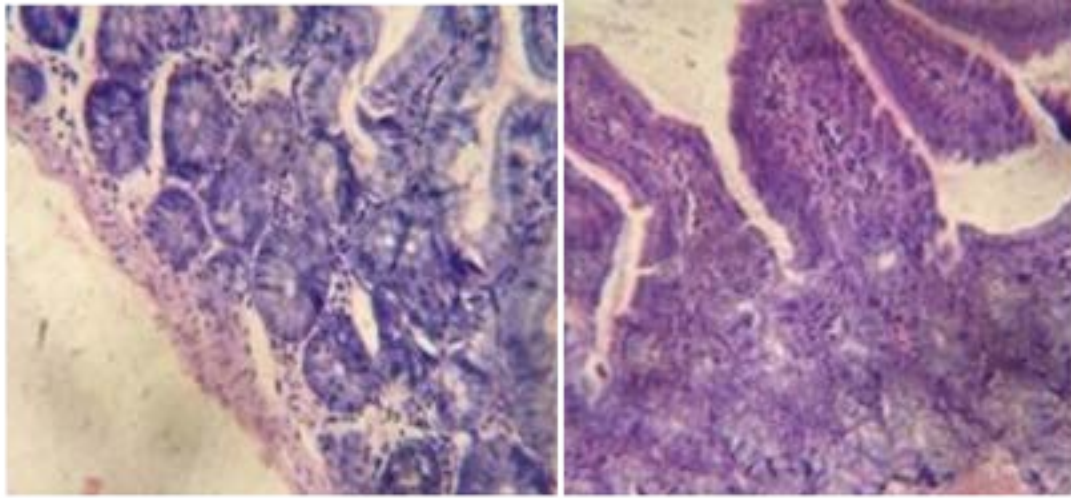
The histopathological changes were the same irrespective of the treated groups, but the lesions varied in extent and severity. Table 1 shows that at zero and fourth hour p.i., animals treated with *ogi tutu* showed moderate diffuse degenerative and inflammatory changes with most of the exudate made up of neutrophils and few lymphocytes.

**Table 1: Semi-quantification of the intestinal histopathological changes of *Vibrio cholerae* infection treated with local herbs at zero and 4<sup>th</sup> hours in mice after 24 hour post infection**

Lesions	<i>Ogi-tutu</i>		<i>P. guajava</i>		<i>Vernonia amygdalina</i>		Infected but untreated (Positive control)		Not infected (Negative control)	
	IM <sub>0</sub> h	DE <sub>4</sub> h	IM <sub>0</sub> h	DE <sub>4</sub> h	IM <sub>0</sub> h	DE <sub>4</sub> h	IM <sub>0</sub> h	DE <sub>4</sub> h	IM <sub>0</sub> h	DE <sub>4</sub> h
Degeneration and necrosis of enterocytes	++	++	-	+	-	+	+++	+++	-	-
Inflammatory exudates in the lamina propria	++	++	-	+	+	-	+++	+++	-	-
Regeneration of enterocytes	-	-	++	++	+	+	+	+	-	-
Stumpy and club-shaped villi	++	++	+	++	+	+	+++	+++	-	-
Goblet cells hyperplasia	-	-	+	+	+	++	++	++	+	+

IM<sub>0</sub>h= Immediate treatment at zero hour(prevention), DE<sub>4</sub>h= Delayed treatment at 4 hours(treatment of infection); - = absent; + = mild; ++= Moderate; +++= Marked

The villi were stumpy and club-shaped in appearance with mild goblet cells hyperplasia (Plate 1).

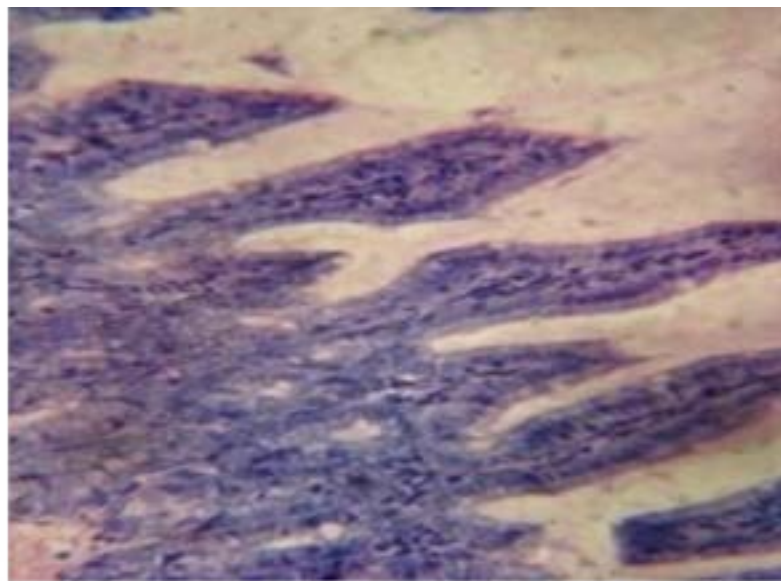


**Plate 1A**= Photomicrograph of intestine at 0 hr of *Ogi tutu* showing degeneration and necrosis of intestinal epithelial cells and mild mononuclear cellular infiltration in the lamina propria. Haematoxylin & Eosin. Bar =150 $\mu$ m.

**Plate 1B**= Photomicrograph of intestine at 4 hr of *Ogi tutu* showing marked diffuse necrosis and degeneration of epithelial cells and the crypt of Lieberkuhn with cellular infiltration in the lamina propria. Haematoxylin & Eosin. Bar =150 $\mu$ m

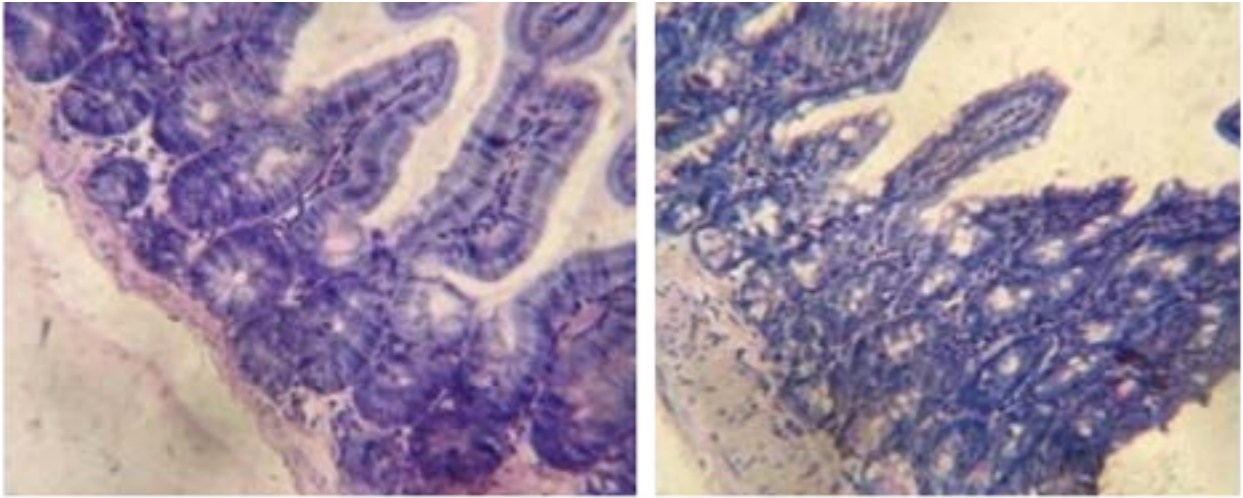
Tissues treated with *Psidium guajava* (Plate 2) and *V. amygdalina* (Plate 3) demonstrated marked anti-inflammatory and anti secretory properties at both zero and 4<sup>th</sup> hour p.i, evidenced by the very mild degenerative and inflam-

matory changes with mild goblet cells proliferation in the intestinal mucosa of the groups treated with these plants. The anti-inflammatory and anti-secretory activities were more prominent in *V. amygdalina* and *P. guajava* compared with *Ogi-tutu*.



**Plate 2.** Photomicrograph of intestine of *Psidium guajava* at 4 h showing mild diffuse degeneration and necrosis with light cellular infiltration in the lamina propria. Haematoxylin & Eosin, Bar =150 $\mu$ m

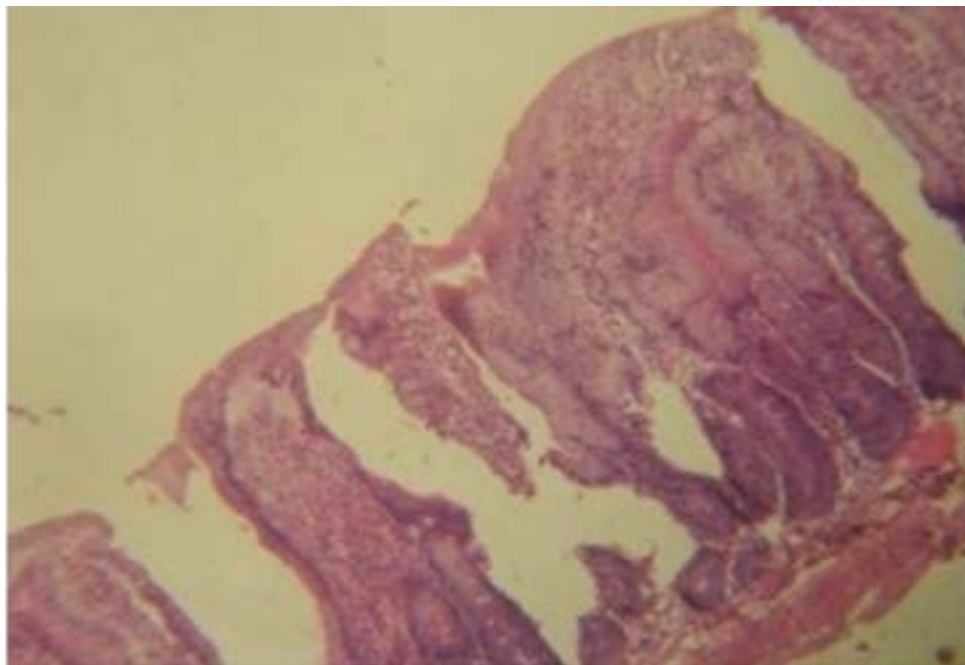




**Plate. 3A=** Photomicrograph of intestine of *Vernonia amygdalina* at 0 h showing slight cellular infiltration in the lamina propria but with normal epithelial cells. Haematoxylin & Eosin. Bar =100µm.

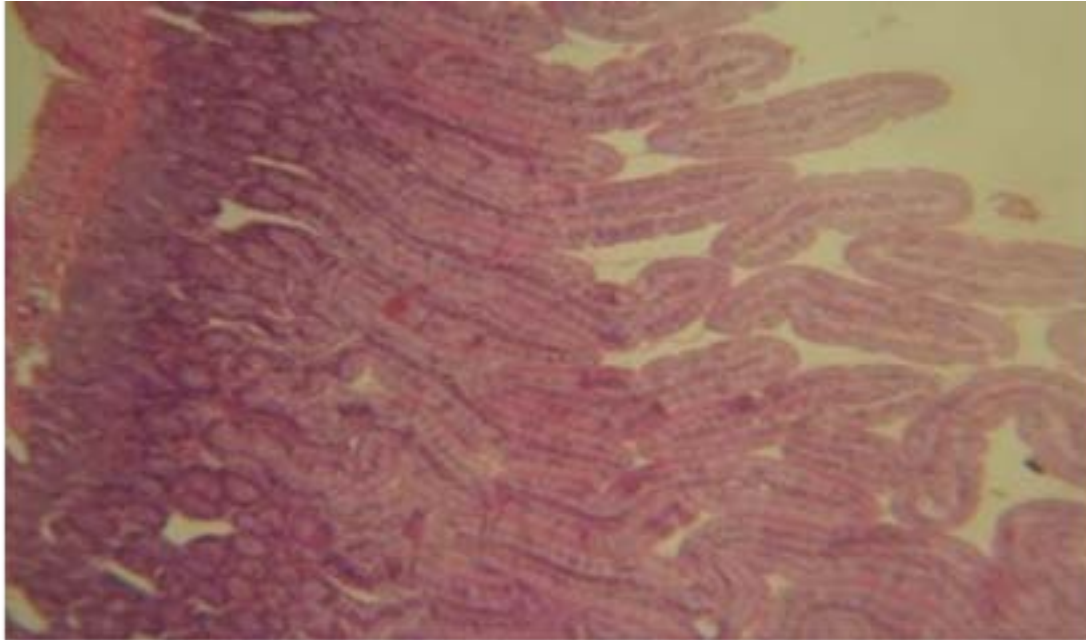
**3B=** Photomicrograph of intestine of *Vernonia amygdalina* at 4 h showing moderate goblet cells hyperplasia and stumpy villi with mild cellular infiltration in the lamina propria. Haematoxylin & Eosin. Bar =150µm.

The infected but untreated group (Plate 4) showed severe infiltration of the lamina propria with neutrophils and lymphocytes, proliferation and regeneration of enterocytes with stumpy and club-shaped villi in this study.



**Plate 4.** Photomicrograph of untreated but infected cell showing severe diffuse necrosis of the villi with marked cellular infiltration in the lamina propria. Haematoxylin & Eosin. Bar =150µm

Moderate goblet cells proliferation was also observed, but there was no significant change in the negative control group (Plate 5).



**Plate 5.** Photomicrograph of normal uninfected intestine (control). Haematoxylin & Eosin. Bar = 150µm.

### Discussion

Several traditional treatments of diarrhea and specifically, cholera are in practice in SouthWestern Nigeria. These traditional claims require experimental investigation to ascertain their effectiveness. Preliminary investigation of vibriocidal activities of *Ogi tutu*, *V. amygdalina* and *P. guajava* showed in vitro vibriocidal activities. These agreed with findings on antibacterial activities documented in the literature<sup>16,19,22-24</sup>.

However, investigation on histopathological effects gave varied ameliorative effects. *Ogi-tutu* (500 mg/ml) was less effective in treating *V. cholerae* infection as evidenced by the moderate diffuse degenerative and inflammatory changes observed at histopathology. *Ogi-tutu* contain lactic acid bacteria (LAB) which have been shown to possess or have antimicrobial potentials and it is significant in the management of human clinical infections<sup>22-23</sup>.

*Vernonia amygdalina* showed very high preventive and effective treatment measures in both the immediate and delayed groups of mice demonstrating excellent ameliorative effect and very mild degenerative changes *in vivo*.

Similar antidiarrheal activity was demonstrated in castor oil induced diarrhea<sup>24</sup>. The varied biological activity of *V. amygdalina* is said to be likely due to the combination of its active compounds such as saponins and alkaloids, terpenes, steroids, coumarines, flavonoids, phenolic acids, lignans, xanthenes and anthraquinones edotides, tannins and sesquiterpene lactone<sup>25</sup>.

*Psidium guajava* displayed very high activity as both prevention and treatment of *V. cholerae* infections when compared with positive and negative control groups. The ameliorative effects of this plant were attested to by the very mild degenerative and inflammatory changes observed in this study. Antidiarrheal activity of the leaves has been proven<sup>26</sup> and also, of the fruit in castor oil induced diarrhea<sup>27</sup>. The decoction of the leaves is capable of neutralizing *Vibrio cholerae*<sup>28</sup>. Pharmacological investigation indicated that its bark, fruit and leaves possess antibacterial, hypoglycemic, anti-inflammatory, analgesic, antipyretic, spasmolytic and CNS depressant properties<sup>19</sup>.

### Conclusion

*Ogi-tutu* displayed less ameliorative effects in the prevention and treatment of *V. cholerae* infection. However, *V.*

*amygdalina* showed better ameliorative effects than *P. guajava* in infected mice. The ameliorative effects in decreasing order were *V. amygdalina* > *P. guajava* > *Ogi-tutu*. *Vernonia amygdalina* could be used for preventive and treatment of *Vibrio cholerae* infection. Further investigations on the active principles of *V. amygdalina* with its mechanism of action are warranted. This might channel a new pathway and better alternative therapeutic agents in the management of diarrhea associated with *V. cholerae*.

### Acknowledgements

The authors would like to appreciate the Department of Veterinary Pathology, College of Veterinary Medicine and the Department of Pure and Applied zoology, College of Biosciences, Federal University of Agriculture, Abeokuta, Nigeria, where the study was conducted.

### Source of funding

Nil.

### Conflict of interest

The authors declare no conflict of interest.

### References

1. Talkington D, Bopp C, Tarr C, Parsons MB, Dahourou G, Freeman M, et al. Characterization of toxigenic *Vibrio cholerae* from Haiti, 2010–2011. *Emerg Infect Dis* 2011; [serial on the Internet]. [19th August 2013]. <http://dx.doi.org/10.3201/eid1711.110805>.
2. Marin MA, Thompson CC, Freitas FS, Fonseca EL, Aboderin AO, et al. Cholera Outbreaks in Nigeria Are Associated with Multidrug Resistant Atypical El Tor and Non-O1/Non-O139 *Vibrio cholerae*. *PLoS Negl Trop Dis* 2013; 7(2): e2049. doi:10.1371/journal.pntd.0002049.
3. Piarroux R, Faucher B. Cholera epidemics in 2010: respective roles of environment, strain changes, and human-driven dissemination. *Clinical Microbiology and Infection* 2012; 18: 231–238. doi: 10.1111/j.1469-0691.2012.03763.x
4. Salim S, Lan R, Reeves PR. *Vibrio cholerae*: Pathogenic Clones. *Emerging Infectious Diseases* 2005; 11 (11). [www.cdc.gov/eid/http://www.ncbi.nlm.nih.gov/pmc/articles/PMC3367346/](http://www.cdc.gov/eid/http://www.ncbi.nlm.nih.gov/pmc/articles/PMC3367346/)
5. Sack DA, Sack RB, Nair GB, Siddique AK. Cholera. *Lancet* 2004; 363: 223-233. <http://www.ncbi.nlm.nih.gov/pubmed/14738797>.
6. Adagbada AO, Adesida SA, Nwaokorie FO, Niemogha M-T, Coker AO. Cholera Epidemiology in Ni-

- geria: an overview. *The Pan African Medical Journal* 2012; 12: 59. <http://www.ncbi.nlm.nih.gov/pubmed/22937199>.
7. Shittu OB. Social and environmental risk factors of cholera and alternative approach to its prevention and treatment. Ph.D. Thesis. Federal University of Agriculture, Abeokuta, Nigeria 2009; 250pp.
8. World Health Organization. Traditional medicine. Media centre: 2008. <http://www.who.int/mediacentre/factsheet/fs/34/en>.
9. Olukoya DK. Lactobacillus in human health with reference to locally fermented foods. *Nig Med J* 1993; 24 (1): 28-30.
10. Lei V, Friis H, Michaelson KF. Spontaneously fermented millet product as a natural probiotic treatment for diarrhea in young children: An intervention study in Northern Ghana. *Int J Fd Microbiol* 2006; 110: 245-253. doi:10.1016/j.ijfoodmicro.2006.04.022
11. Odunfa SA. African fermented foods. In: Microbiology of fermented foods, Vol 2, Wood BJ (ed), London & New York: Elsevier Applied Science Publishers, 1985.
12. Sofowora A. Medicinal Plants and Traditional Medicines in Africa. New York: John Wiley & Sons, 1993.
13. Gill LS. Ethnomedical uses of plants in Nigeria. Benin City: University of Benin Press, 1992; 276pp.
14. Olapade EO. The Herbs for Good Health. Ibadan, Nigeria: NarL Specialist Clinic, 2003; 146pp.
15. Oluwalana SA, Ezeri GNO, Bankole MO, Bamire EO. Uses of forest plants in traditional water management in Ogun State Nigeria. *The Bioprospector* 1999; 1 (1): 43-54.
16. Iwalokun BA, Bamiro SB, Durojaiye OO. An antimicrobial evaluation of *Vernonia amygdalina* (Compositae) against gram-positive and gram-negative bacteria from Lagos Nigeria. *W Afri J Pharmacol Drug Res* 2003; 19 (1 & 2): 9-15.
17. Bosch CH, Borus DJ, Siemonsma JS. Vegetables of Tropical Africa. Conclusions and Recommendations Based on PROTA 2: 'Vegetables'. PROTA Foundation, Wageningen, Netherlands, 2005; 68pp.
18. Olajide OA, Awe SO, Makinde JM. Pharmacological studies on the leaf of *Psidium guajava*. *Fitoterapia* 1999; 70: 25-31.
19. Begum S, Hassan SI, Siddiqui BS, Shaheen F, Ghayur, MN, Gillani AH. Triterpenoids from the leaves of *Psidium guajava*. *Phytochem* 2002; 61: 399-403. <http://www.ncbi.nlm.nih.gov/pubmed/12377233>
20. Gutierrez RMP, Mitchell S, Solis RV. *Psidium guajava*: A review of its traditional uses, phytochemistry and phar-



- macology. *Journal of Ethnopharmacology* 2008; 117(1): 1-27. doi: 10.1016/j.jep.2008.01.025.
21. Dalsgaard A, Reichert P, Mortensen HF, Sandstrom A, Kofoed P-E, Larsen JL, Molbak K. Application of lime (*Citrus aurantifolia*) juice to drinking water and food as a cholera-preventive measure. *J Fd Protec* 1997; 60(11):1329-1333.
  22. Odugbemi T, Odujinrin OMT, Akitoye CO, Oyerinde, JPO, Esumeh FI. Study on the pH of ogi, Nigerian fermented weaning food, and its effect on enteropathogenic *Escherichia coli*, *Salmonella typhi* and *Salmonella paratyphi*. *J Trop Med Hyg* 1991; 94: 219-223.
  23. Kingamkono R, Shogren E, Svanberg U, Kaijser B. Inhibition of different strains of enteropathogens in lactic acid-fermenting cereal gruel. *W J Microbiol Biotechnol* 1995; 11: 299-303.
  24. Okere OS, Sangodele JO, Tade OG, Obafemi OT, Falode JA. Anti-diarrhea potential and acute toxicity studies of methanolic extract of *Vernonia amygdalina* and *Cymbopogon citratus* against castor oil induced diarrhea model in rats. *International Journal of Biochemistry Research & Review* 2015; 6(2): 46-52.
  25. Erasto P, Grierson DS, Afoloyan AJ. Bioactive sesquiterpine lactones from leaves of *Vernonia amygdalina*. *J Ethnopharmacol* 2006; 106(11):117-120. <http://www.ncbi.nlm.nih.gov/pubmed/16458461>
  26. Ezekwesili JO, Nkemdilim UU, Okeke CU. Mechanism of anti-diarrhoeal effect of ethanolic extract of *Psidium guajava* leaves. *Biokemistri* 2010; 22 (2):85-90.
  27. Ndukui JG, Murithi BM, Muwonge H, Sembajwe LF, Kateregga J. Antidiarrheal activity of ethanolic fruit extract of *Psidium guajava* (guava) in castor oil induced diarrhea in albino rats. *Natl J Physiol Pharm Pharmacol* 2013; 3:191-197. doi: 10.5455/njppp.2013.3.100620131
  28. Birdi T, Daswani P, Brijesh S, Tetali P, Natu A, Antia N. Newer insights into the mechanism of action of *Psidium guajava* L. leaves in infectious diarrhea. *BMC Complementary and Alternative Medicine* 2010; 10:33. doi: 10.1186/1472-6882-10-33