

## CASE REPORTS

### Coarctation of aorta presenting as acute haemorrhagic stroke in a 14-year old. A case report.

James Opio, E Kiguli-Malwadde, RK Byanyima

Department of Radiology, Faculty of Medicine Makerere University.

*African Health Sciences* 2008; 8(4): 256-258

#### Introduction

Coarctation of the aorta is a relatively common defect. It may occur as an isolated defect or in association with a variety of other lesions, most commonly bicuspid aortic valve. The diagnosis of coarctation of the aorta may be missed unless a high index of suspicion is maintained, and diagnosis often is delayed until the patient develops congestive heart failure, which is frequent in infants, or hypertension, which is frequent in older children. This adolescent presented for the very first time with acute haemorrhagic stroke due to severe hypertension secondary to Coarctation of the aorta. A chest x-ray showed features of left ventricular enlargement and coarctation of aorta.

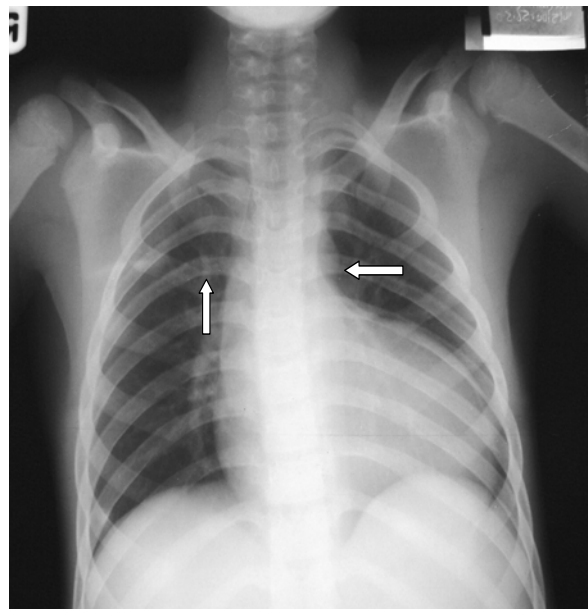
#### Case presentation

A 14 year-old male without any ailments since birth developed sudden onset of loss of consciousness associated with right hemiplegia and facial palsy. Significant clinical findings were: bradycardia (56bpm), absent femoral, popliteal and dorsalis pedis pulses, severe hypertension (225/120mmHg) and aortic stenosis murmur.

A PA chest x-ray showed gross cardiomegally with a rounded and laterally displaced apex. The ascending aorta was dilated and there was a notch in the proximal descending aorta demonstrating a 'figure-of-3' sign. No features of pulmonary congestion were observed. Subtle rib notching was noted on the inferior borders of the right 5<sup>th</sup> and 7<sup>th</sup> ribs (Fig.1). An impression of left ventricular hypertrophy secondary to severe hypertension, complicating coarctation of the aorta was made.

Cardiac echo revealed left ventricular hypertrophy, aortic stenosis and a small degree of aortic incompetence. Non-enhanced brain CT scans done at 10mm slice thickness showed a well-defined homogeneously hyperdense mass lesion of 77 HU (compared to 37 HU of corresponding normal brain) in the left fronto-temporal peri-ventricular region. It measured 54x21x50mm and was surrounded by a hypodense rim due to oedema. The anterior horn of the left ventricle was deformed and a midline shift of 4mm was noted. The ambiens cistern was preserved (Fig.2). A diagnosis of acute intra-cerebral haemorrhage was made.

**Fig.1: Chest x-ray showing cardiomegally, lateral apical displacement, a "figure-of-3" sign (left arrow) and early rib notching (upward arrow).**



#### Correspondence:

E. Kiguli-Malwadde

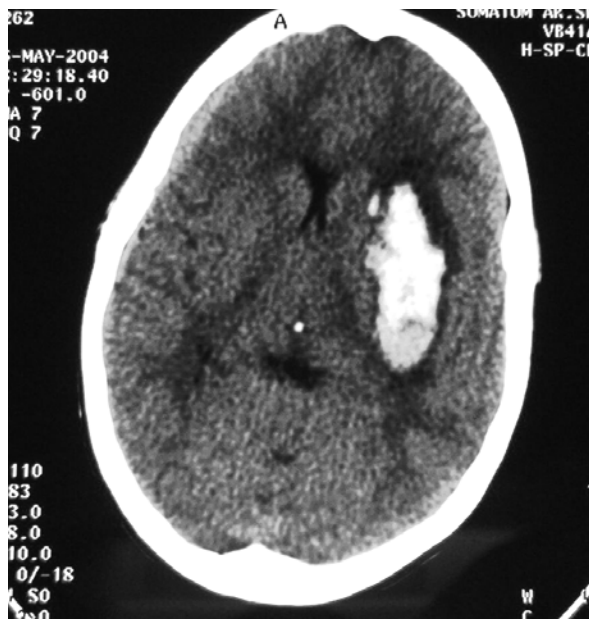Makerere University, Faculty of Medicine,

Department of Radiology and Mulago Hospital

P.O.Box 7051, Kampala, Uganda

Email [malwadde@med.mak.ac.ug](mailto:malwadde@med.mak.ac.ug)

**Fig.2: Brain CT scan showing acute intra-cerebral haematoma**



## Discussion

Coarctation of the aorta is a relatively common defect accounting for 5-8% of all congenital heart defects. It may occur as an isolated defect or in association with a variety of other lesions, most commonly bicuspid aortic valve (in 50% of cases) and ventricular septal defect<sup>(1,2)</sup>. The diagnosis of coarctation of the aorta may be missed unless an index of suspicion is maintained, and diagnosis often is delayed until the patient develops congestive heart failure, which is frequent in infants, or hypertension<sup>(2,3)</sup>.

Coarctation of the aorta imposes significant after-load on the left ventricle, which results in increased wall stress and compensatory ventricular hypertrophy. The after-load may be imposed acutely, as occurs following closure of the ductus arteriosus in neonates with severe coarctation. These infants may rapidly develop congestive cardiac failure and shock<sup>(1)</sup>.

Left ventricular after-load may also increase gradually, allowing children with less severe coarctation to develop arterial collateral vessels that bypass the aortic obstruction. These children may be asymptomatic until hypertension is detected or another complication like life-threatening intracranial haemorrhage develops<sup>(4)</sup>. Chronic hypertension causes lipohyalinosis, fibrinoid necrosis and development of Charcot-Bouchard aneurysms which rupture to cause intracranial haemorrhage<sup>(5)</sup>. No such case has been reported in Uganda or East Africa. The incidence of coarctation of the aorta in East Africa is not known. This case is reported

so as to increase the index of suspicion for it and also because the presentation was unusual in that the hypertension was never detected until the patient presented with a stroke. The natural history of untreated coarctation is that of premature death from stroke and coronary heart disease or sudden death. However this commonly occurs early on in childhood for patients that are not treated<sup>(6)</sup>.

This was a typical case of an asymptomatic hypertensive patient who only presented with intra-cerebral haemorrhage. Haemorrhagic strokes account for 10 -20% of strokes in general, with a one month fatality of about 42%. Hypertension is the leading cause of non traumatic intracerebral haemorrhage<sup>(7)</sup>.

Radiographs of patients with early onset of coarctation of the aorta may reveal cardiomegaly, pulmonary oedema, and other signs of congestive cardiac failure. In patients with late onset of coarctation of the aorta, cardiomegaly, arch indentation in the area of the coarctation, and rib notching may be seen<sup>(6,8)</sup>.

This patient presented with late onset features including cardiomegaly, aortic indentation and early rib notching.

Rib notching is the single most reliable sign. It is unusual below 10 years and the older the person, the more likely to have rib notching. Although rib notching was observed in this patient it was not a prominent feature probably because it is still early on account of his young age. Most patients with coarctation beyond 20 years of age display this sign<sup>(6,9)</sup>.

The indentation in the area of the coarctation gives a 'figure-of-3' sign. This appearance is caused by the tuck of the coarctation itself and may be accentuated by dilated left subclavian artery or aortic knob, or post-stenotic aortic dilatation<sup>(8,9)</sup>.

Cardiomegaly is due to left ventricular hypertrophy, which is seen as rounding of the cardiac apex, and dilatation which manifests as infero-lateral apical displacement<sup>(3,4)</sup>. This was a prominent feature in this patient

Echocardiography delineates intra-cardiac anatomy and allows assessment of associated significant intra-cardiac anomalies. The para-sternal long and short axis views enable evaluation of the aortic root, inter-ventricular septum and left ventricular wall. The suprasternal notch view allows evaluation of the aortic arch to assess the transverse aortic arch, isthmus, and severity of coarctation. Doppler echocardiography measures the gradient at the area of coarctation and identifies the pattern of diastolic runoff typically seen in patients with severe obstruction<sup>(8,9)</sup>. In this case the

cardiac echo was able to detect left ventricular hypertrophy and associated aortic stenosis.

Hypertensive strokes commonly occur in basal ganglia, thalamus, pons cerebellum and other brain stem sites. Bleeding into brain parenchyma causes direct brain injury and in addition, surrounding brain is damaged by pressure from the haematoma <sup>(5)</sup>. Prognosis of haemorrhagic stroke depends on stroke severity, neurological score, extent of haemorrhage at imaging and greater patients age <sup>(7)</sup>. Epileptic seizures are commoner following haemorrhagic as compared to ischaemic stroke and they are commoner in lobe as compared to basal ganglia haemorrhages. Few children may recover with no physical impairment but hemiparesis of variable severity, cerebellar ataxia, tetraparesis, paraparesis and cognitive defects are some of impairments that can occur if patients survive. Rebleeding is also one of the feared events <sup>(7, 10)</sup>.

### References

1. Harlan JL, Doty DB, Brandt B 3rd: Coarctation of the aorta in infants. *Journal of Thoracic Cardiovascular Surgery* 1984 Dec; 88(6): 1012-9
2. Greenwood RD, Rosenthal A, Parisi L. Extracardiac abnormalities in infants with congenital heart disease. *Paediatrics* 1975; 55:485-492.
3. Ing FF, Starc TJ, Griffiths SP, Gersony Wm. Early diagnosis of coarctation of the Aorta in children: a continuing dilemma. *Paediatrics* 1996; 98: 378-382.
4. Campbell M. Natural history of coarctation of the aorta. *British Heart Journal* 1970; 32: 633-640.
5. K A L Carroll, J Chataway. Understanding stroke: Pathophysiology, prevention, and investigations. *Student British Medical Journal* 2006; 14:309-352.
6. Mullen M J. Coarctation of the aorta in adults: do we need surgeons? *Heart* 2003; 89: 3-5
7. Martin Dennis. Advances in stroke prevention. *Cerebrovascular Diseases* 2003; 16(Suppl 1): pg 9-13
8. Kreel L. Congenital heart disease and associated conditions. *Outline of Medical Imaging*; 28: 196-198
9. von Schulthess GK, Higashino SM, Higgins SS. Coarctation of the aorta: Imaging. *Radiology* 1986; 158:469-474.
10. Ingrid Blom, Els, L L M De Schryver, L Jaap Kappelle, et al Prognosis of haemorrhagic stroke in childhood: a long-term follow-up study. *Developmental Medicine & Child Neurology* 2003; 45(4): 233-239