



ISSN: 2476-8642 (Print)

ISSN: 2536-6149 (Online)

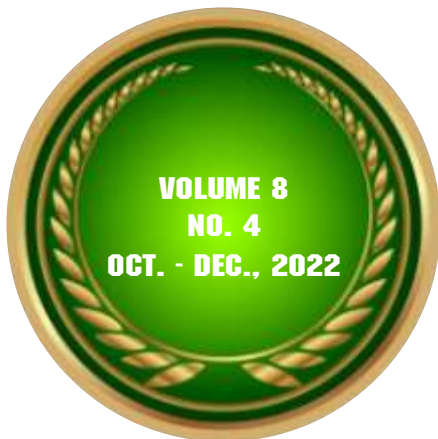www.annalsofhealthresearch.com

African Index Medicus, Crossref, African Journals
Online & Google Scholar

C.O.P.E & Directory of Open Access Journals

Annals of Health Research

IN THIS ISSUE



- Climate Change Project
- Telemedicine and COVID-19 Pandemic
- Gamete Donation for Artificial Insemination
- Paediatric Gastrointestinal Endoscopy
- Monkeypox Surveillance
- Abdominal Massage in Pregnancy
- Deprescribing Polypharmacy
- Survival in Childhood Cancer
- Secondary Hypothyroidism

**PUBLISHED BY THE MEDICAL
AND DENTAL CONSULTANTS ASSOCIATION
OF NIGERIA, OOUTH, SAGAMU, NIGERIA.**

www.mdcan.outh.org.ng

CASE REPORT

Secondary hypothyroidism following the Resolution of Graves' Disease: A Case Report

Lawal Y*¹, Kaoje SY², Bansi IK¹

¹Department of Internal Medicine, University of Abuja, FCT Nigeria.

²CBN Medical Centre, Abuja, FCT Nigeria

*Correspondence: Dr Y Lawal, Department of Internal Medicine, Faculty of Clinical Sciences, University of Abuja, Abuja. E-mail: lawalyaqub2006@yahoo.com; ORCID - <https://orcid.org/0000-0002-2210-2601>.

Summary

This is the case report of a 39-year-old lady who presented with clinical and laboratory features of secondary hypothyroidism two years after achieving clinical and biochemical resolution of Graves' disease and cessation of anti-thyroid medications. The thyroid function tests at presentation revealed: Serum T₃ 1.33ng/ml (normal range 0.8-1.7ng/ml), Serum T₄ 2.92 (normal range 4.5-12.0µg/dl), and TSH 0.2mIU/l (normal range 0.5-5.0mIU/l). Thyroid-related autoantibodies could not be assayed in the patient due to financial constraints. However, pointers to the possible autoimmune nature of secondary hypothyroidism include the recurrence of exophthalmos, dating of symptoms back to puerperium, relative lymphocytosis, and moderately elevated erythrocyte sedimentation rate (ESR). The patient was subsequently placed on levothyroxine and low-dose steroids, and the patient achieved clinical and biochemical euthyroidism in the sixth, ninth, and twelfth months of follow-up. This report is to demonstrate the development of secondary hypothyroidism following Graves' disease, and it also serves to highlight the judicious use of clinical acumen in the face of limited laboratory support to diagnose and treat endocrine disorders in resource-poor settings.

Keywords: Autoimmune disease, Graves' disease, Primary hyperthyroidism, Secondary hypothyroidism, Thyroid disease.

Introduction

Graves' disease is an autoimmune disorder characterized by hyperthyroidism, diffuse goitre, ophthalmopathy, and rarely dermopathy. [1] In Graves' disease, thyroid stimulating hormone receptor (TSHR) antibody binds to and stimulates the TSH receptor leading to excessive production of excessive thyroid hormones from the thyroid gland. [2,3] These TSH receptor

antibodies can either have stimulatory or blocking effects. [2] Several studies have shown that thyrotropin receptor (TSHR) stimulating antibodies cause Graves' hyperthyroidism, and TSHR-blocking antibodies can block thyrotropin action causing hypothyroidism. [2-4] Switching from stimulating to blocking antibodies and *vice versa* has severally been reported. [4-6] A switch from blocking to stimulating antibodies occurs in persons treated with levothyroxine while the reverse switch tends to occur after anti-thyroid

medication therapy. [5,6] Some of these authors hypothesized that the drugs used for the treatment of either hyperthyroidism or hypothyroidism may be the initiating factor in the immunological conversion from stimulating to blocking TSH receptor autoantibodies. The mechanisms involved in antibody switch may include a decrease or increase in the secretion of autoantibodies, impaired development of regulatory T-cells, immune suppression, haemodilution, and TSH receptor affinities. [7]

Several other reports have shown the occurrence of primary hypothyroidism several years following recovery and cessation of treatment for Graves' disease. [4-7] Some of these studies demonstrated the development of blocking thyrotropin (TSH) receptor antibodies as the cause of primary hypothyroidism. [5-7] On the other hand, some studies have also shown the development of Graves' disease several years following recovery and cessation of treatment for primary hypothyroidism. [8-10] In a different vein, some authors have hypothesized that Graves' disease and Hashimoto's thyroiditis are two ends of a continuum of autoimmune thyroid disease. They added that any of the two could precede the other. [11-18]

However, we have not encountered a report of secondary hypothyroidism following recovery from Graves' disease. Therefore, it becomes crucial to alert clinicians of this possibility. This report further highlights the judicious use of clinical acumen and limited laboratory facilities to diagnose and treat endocrine disorders in resource-poor settings.

Case Description

A 39-year-old woman Para 5⁺⁰ (5 alive with no previous miscarriage or spontaneous abortion), presented with diffuse goitre, clinical features of hyperthyroidism, and exophthalmos. She was diagnosed with Graves' disease nine years before

presentation. She was treated with carbimazole, an anti-thyroid medication, for seven years until she became euthyroid and no longer had exophthalmos. Two (2) years later, she presented with excessive weight gain, cold intolerance, dry, coarse skin, constipation, irregular menses, menorrhagia and recurrence of exophthalmos. These symptoms dated back to puerperium following her fifth childbirth. There was no postpartum haemorrhage. There was no history of radioiodine therapy, thyroidectomy or therapy with amiodarone, lithium, or any chronic medication that can affect thyroid functions. There was also no history of trauma or cranial surgery. There was no symptom suggestive of a deficiency of any other anterior pituitary hormone, though such symptoms could be absent or vague. A working diagnosis of a hypothyroid phase of Graves' disease was made.

On physical examination, bilateral exophthalmos was observed (exophthalmometre reading: right eye = 25 mm, left eye = 24 mm; normal range = 14-21 mm). There was no anterior neck swelling. Cardiovascular examination findings included a pulse rate of 52 beats per minute and systemic blood pressure of 140/90mmHg; the apex beat was located at the fifth left intercostal space, midclavicular line, and only the first and second heart sounds were heard. No gross sign suggested a deficiency of any other anterior pituitary hormone.

Thyroid function tests (TFT) done using chemiluminescence enzyme immunoassay revealed: tri-iodothyronine (T₃) 1.33 ng/ml (normal range 0.8-1.7 ng/ml), thyroxine (T₄) 2.92 ug/dl (normal range 4.5-12.0 ug/dl), thyroid stimulating hormone (TSH) 0.2 mIU/1 (normal range 0.5-5.0 mIU/L). These parameters were in keeping with secondary hypothyroidism. The pelvic ultrasound scan was normal. Computed Tomography (CT) scan of the brain revealed no abnormality in the hypothalamus-pituitary axis (Figure 1), but Magnetic Resonance Imaging

(MRI) was not done due to financial constraints. Complete blood count showed a normal white cell count of $5.9 \times 10^9/L$ with relative lymphocytosis of 56%. The Erythrocyte sedimentation rate (ESR) was 64 mm/hour. Serum electrolytes, urea, uric acid, calcium, phosphorus, total protein and albumin were within normal limits.

The patient was commenced on oral levothyroxine 50 micrograms daily and prednisolone 20 mg daily. The prednisolone was

tapered down over one month to 5mg daily and was so maintained. On the sixth month of follow-up care, she was clinically and biochemically euthyroid (T_3 - 1.57 ng/ml (normal range 0.8-1.7 ng/ml), T_4 - 8.52 ug/dl (normal range 4.5-12.0 ug/dl), TSH - 2.7 mIU/l (normal range 0.5-5.0 mIU/L). Complete blood count showed a decrease in lymphocytes differential count to 27% and a reduction in ESR to 19 mm/hour. The medications were stopped, and she remained euthyroid during the ninth and twelfth months of follow-up care.




Figure 1: Sagittal, axial, and coronal views of the pituitary gland CT scan showing no abnormality

Discussion

This is a case of a middle-aged adult woman previously treated for Graves' disease with carbimazole for seven years before achieving euthyroidism and complete regression of exophthalmos. Two years later, she developed

clinical features of hypothyroidism plus exophthalmos. These features are in keeping with reports of some persons with Graves' disease who later developed hypothyroidism several years after anti-thyroid medications were stopped. [4-7] Other possibilities include subacute thyroiditis, Hashimoto's thyroiditis, and even

Sheehan's syndrome, although there was no history of postpartum haemorrhage.

However, an investigation of the index patient revealed a biochemical profile suggestive of secondary hypothyroidism based on decreased serum TSH levels alongside decreased serum T₄ levels. This is not in concordance with previous reports of primary hypothyroidism following recovery from Graves' disease. This observation may be explained by the possible autoimmune affection of the hypothalamus-pituitary axis coexisting with or following the resolution of Graves' disease. The possibility of a mass lesion involving the hypothalamus-pituitary axis was ruled out to some extent, though not completely, by the absence of corresponding clinical features and a negative CT scan imaging.

The pointers to the possible autoimmune nature of secondary hypothyroidism include the recurrence of exophthalmos, the dating back of symptoms to puerperium, [19] relative lymphocytosis in complete blood count, and moderate elevation of ESR. The recession of exophthalmos, normalization of lymphocytosis, and remarkable reduction in ESR following treatment with low-dose steroids further supported this. In a different vein, the hypothyroidism may have been caused by immunopathology in both the thyroid and hypothalamus-pituitary axis. This means the blocking of TSH receptor autoantibodies could contribute to hypothyroidism caused by hypothalamus-pituitary disease. However, serum TSH levels would fail to rise due to the loss of feedback stimulation of a diseased hypothalamus-pituitary axis.

The recurrence of exophthalmos confirmed by ophthalmologic review supported the possibility of a relapse of the previous disease but in a different form. This is in keeping with reports by some authors who described the presence of

ophthalmopathy in hypothyroid persons initially treated for Graves' disease. [20, 21].

Limitations of this report include the non-assay of TSH receptor stimulating or blocking autoantibodies, anti-thyroid peroxidase/ anti-thyroglobulin antibodies, and the lack of MRI imaging to enable a better view of the hypothalamus-pituitary axis, even though CT scan imaging showed no abnormality. Also, other pituitary hormones and their target hormones were not assayed.

Conclusion

This case report should alert clinicians to the possibility of secondary hypothyroidism coexisting with or following the resolution of Graves' disease. The report also highlighted the role of judicious use of clinical acumen in the face of limited laboratory resources in diagnosing and treating endocrine disorders in resource-poor settings.

Acknowledgement: The authors acknowledge the staff of the Department of Health Information Management of Federal Medical Centre, Azare, for the retrieval of the patient's records.

Authors' Contributions: LY, KSY, and BIK conceived and designed the study. They analyzed and interpreted the data. LY drafted the manuscript. All the authors revised the draft for sound intellectual content. All the authors approved the final draft of the manuscript.

Conflicts of Interest: None declared.

Funding: Self-funded.

Data availability Statement: The data used for this report are available with the corresponding author.

Patient's Consent Statement: The patient's consent was obtained to publish this case report.

Publication History: Submitted 16 September 2022; Accepted 12 November 2022.

References

1. Ginsberg J. Diagnosis and management of Graves' disease. *CMAJ* 2003;168:575-585.
2. McLachlan SM, Rapoport B. Thyrotropin-blocking autoantibodies and thyroid-stimulating autoantibodies: potential mechanisms involved in the pendulum swinging from hypothyroidism to hyperthyroidism or vice versa. *Thyroid* 2013;23:14-24.
<https://doi.org/10.1089/thy.2012.0374>
3. Takasu N, Matsushita M. Changes of TSH-Stimulation Blocking Antibody (TSBAB) and Thyroid Stimulating Antibody (TSAb) Over 10 Years in 34 TSBAB-Positive Patients with Hypothyroidism and in 98 TSAb-Positive Graves' Patients with Hyperthyroidism: Reevaluation of TSBAB and TSAb in TSH-Receptor-Antibody (TRAb)-Positive Patients. *J Thyroid Res* 2012;2012:182176.
<https://doi.org/10.1155/2012/182176>
4. Wood LC, Ingbar SH. Hypothyroidism as a late sequela in a patient with Graves' disease treated with anti-thyroid agents. *J Clin Invest* 1979;64:1429-36.
<https://doi.org/10.1172/JCI109601>
5. Kasagi K, Hidaka A, Endo K, Miyamoto S, Takeuchi R, Misaki T, *et al.* Fluctuating thyroid function depending on the balance between stimulating and locking types of TSH receptor antibodies: a case report. *Thyroid* 1993;3:315-318.
<https://doi.org/10.1089/thy.1993.3.315>
6. Evans M, Sanders J, Tagami T, Sanders P, Young S, Roberts E, *et al.* Monoclonal autoantibodies to the TSH receptor, one with stimulatory activity and one with blocking activity obtained from the same blood sample. *Clin Endocrinol* 2010;73:404-412.
<https://doi.org/10.1111/j.1365-2265.2010.03831.x>
7. Frohlich E, Wahl R. Thyroid Autoimmunity: Role of Anti-thyroid Antibodies in Thyroid and Extra-Thyroidal Diseases. *Front Immunol* 2017; 8:521.
<https://doi.org/10.3389/fimmu.2017.00521>
8. Furqan S, Haque NU, Islam N. Conversion of autoimmune hypothyroidism to hyperthyroidism. *BMC Res Notes* 2014;7:489.
<https://doi.org/10.1186/1756-0500-7-489>
9. Wuqiang F, Prabhat T, Mahesh K. Oscillating hypothyroidism and hyperthyroidism - a case-based review. *J Community Hosp Intern Med Perspect* 2014;4:25734.
<https://doi.org/10.3402/jchimp.v4.25734> Fr
10. Yamasaki H, Takeda K, Nakauchi Y, Suehiro T, Hashimoto K. Hypothyroidism preceding hyperthyroidism in a patient with continuously positive thyroid-stimulating antibody. *Intern Med* 1995;34:247-250.
<https://doi.org/10.15605/jafes.033.02.12>
11. Gupta Y, Singh S, Ammini AC. Development of Graves' disease after long-standing hypothyroidism on treatment, with acute toxicity to thionamides and lithium. *BMJ Case Rep.* 2012;2012:bcr2012006433.
<https://doi.org/10.1136/bcr-2012-006433>
12. Ekpebegh C, Elmezughi K, Mtingi L. Graves' disease following hypothyroidism due to Hashimoto's thyroiditis in a black South African lady: A case report. *Pan Afr Med J.* 2019;32:186.
<https://doi.org/10.11604/pamj.2019.32.186.18713>
13. Kamath C, Young S, Kabelis K, Sanders J, Adlan MA, Furmaniak J, *et al.* Thyrotropin receptor antibody characteristics in a woman with long-standing Hashimoto's who developed Graves' disease and pretibial myxedema. *Clin Endocrinol* 2012;77:465-470.
<https://doi.org/10.1111/j.1365-2265.2012.04397.x>
14. Pak S, Valencia D, Fershko A. Transformation of Hashimoto's thyroiditis to Graves' disease. *Res Rev Insights* 2017;1:1-2.
<https://doi.org/10.15761/RR.1000117>

15. Thomsen H, Li X, Sundquist K, Sundquist J, Försti A, Hemminki K. Familial risks between Graves disease and Hashimoto thyroiditis and other autoimmune diseases in the population of Sweden. *J Transl Autoimmun* 2020;3:100058.
<https://doi.org/10.1016/j.jtauto.2020.100058>
16. Champion B, Gopinath B, Ma G, El-Kaissi S, Wall JR. Conversion to Graves' hyperthyroidism in a patient with hypothyroidism due to Hashimoto's thyroiditis documented by real-time thyroid ultrasonography. *Thyroid* 2008;18:1135-1137.
<https://doi.org/10.1089/thy.2008.0142>
17. Dasari S, Naha K, Hande M, Vivek G. Hot and cold: coexistent Graves' disease and Hashimoto's thyroiditis in a patient with Schmidt's syndrome. *BMJ Case Rep* 2014;2014:bcr2013010432.
<https://doi.org/10.1136/bcr-2013-010432>
18. Ahmad E, Hafeez K, Arshad MF, Isuga J, Vrettos A. Hypothyroidism conversion to hyperthyroidism: it's never too late. *Endocrinol Diabetes Metab Case Rep* 2018;2018:18-0047.
<https://doi.org/10.1530/EDM-18-0047>
19. Amino N, Tada H, Hidaka Y. Postpartum autoimmune thyroid syndrome: a model of aggravation of the autoimmune disease. *Thyroid* 1999;9:705-713.
<https://doi.org/10.1089/thy.1999.9.705>
20. Kim WB, Chung HK, Park YJ, Park DJ, Lee HK, Cho BY. Clinical significance of classification of Graves' disease according to the characteristics of TSH receptor antibodies. *Korean J Intern Med* 2001;16:187-200.
<https://doi.org/10.3904/kjim.2001.16.3.187>
21. Hallengren B, Planck T, Åsman P, Lantz M. Presence of Thyroid-Stimulating Hormone Receptor Antibodies in a Patient with Subacute Thyroiditis followed by Hypothyroidism and Later Graves' Disease with Ophthalmopathy: A Case Report. *Eur Thyroid J* 2015;4:197-200.
<https://doi.org/10.1159/000435915>

