

Sphincter Saving Surgery in Low Rectal Carcinoma in a Resource Poor Environment: A Case Report.

Emegoakor CD, Eze BUN, Mbanefo JC, Okoye AO

ABSTRACT

Background: *Surgery is the principal modality of treatment of rectal carcinoma in order to achieve cure. Sphincter saving surgery improves the quality of life of patients with low rectal carcinoma.*

Aim: *To report a case of sphincter saving low anterior resection for low rectal cancer with hand sown colorectal anastomosis*

Conclusion: *Even in the absence of stapling gun, sphincter saving resections are possible in selected patients with low rectal carcinoma.*

Keywords: *Sphincter saving, low rectal cancer, stapling gun.*

INTRODUCTION

A correct surgical approach to rectal cancer today has to make due allowance for both improved overall survival with local control of disease and preservation of sphincter and urinary and genital functions¹. Stapler makes possible the lower colorectal anastomosis often avoiding abdominoperineal resection of the rectum². Anastomosis between 7 and 4 cm from the pectinate line are defined as low rectal anastomosis³.

The problem with attempting mechanical hand sown anastomosis deep within the pelvis is the attendant difficulty and increased risk of anastomotic leakage.

CASE REPORT

Mr E.O, a 61 year old trader, presented to the Surgical Out-Patient Department of Nnamdi Azikiwe University Teaching Hospital, Nnewi with two months history of passage of blood per rectum and a month history of change in bowel habit. Blood was fresh and occasionally dark in colour. He passes about 50 mls per episode and an average of two episodes per week. Blood comes initially before the passage of normal coloured stool. No history suggestive of haemodynamic instability. Change in bowel habit consisted of reduction in calibre of stool and alternating diarrhoea and constipation. There was positive history of tenesmus. No history of abdominal pain, abdominal distension or vomiting. There was

significant weight loss but no jaundice or bone pain. He was not a known hypertensive or diabetic patient; had no surgeries in the past. He takes an average of one bottle of beer a day and does not smoke cigarette.

Examination revealed an afebrile anicteric man without pallor or pitting oedema. His vital signs were temperature 36.2°C, respiratory rate of 18 cycles per minute, pulse rate of 83 beats per minute; full volume and regular, and blood pressure of 130/70 mm Hg. His abdomen was full, moved with respiration and hernia orifices were intact. There were no areas of tenderness and no palpable organ enlargement. The kidneys were not ballotable. There was no ascites and bowel sound was normoactive. Rectal examination revealed a good perianal hygiene and normal sphincter tone. There were no palpable rectal masses and a mildly enlarged prostate with benign features. Rectum was empty and examining finger was stained with brown faeces. Other systemic examinations were essentially normal.

A clinical diagnosis of left colonic tumour was made.

Haemoglobin concentration was 12.1 g/dl. Total white cell count, differential and platelet counts were normal. Urinalysis, serum electrolytes, creatinine, blood urea nitrogen, abdominopelvic ultrasound and chest x-ray were essentially normal. Barium enema showed significant narrowing at rectosigmoid junction and redundant descending colon (Fig I).

He had a three-day mechanical bowel preparation and subsequently exploratory laparotomy.

Intra-operative findings were a mobile tumour extending from the recto-sigmoid junction to the middle third of the rectum, 8 cm from the anal verge and enlarged mesorectal lymph nodes. He had a low anterior resection with 2 cm distal resection margin, total mesorectal excision and a single-layer hand sewn colorectal anastomosis with vicryl 2-0 suture. He also had a diverting transverse colostomy.

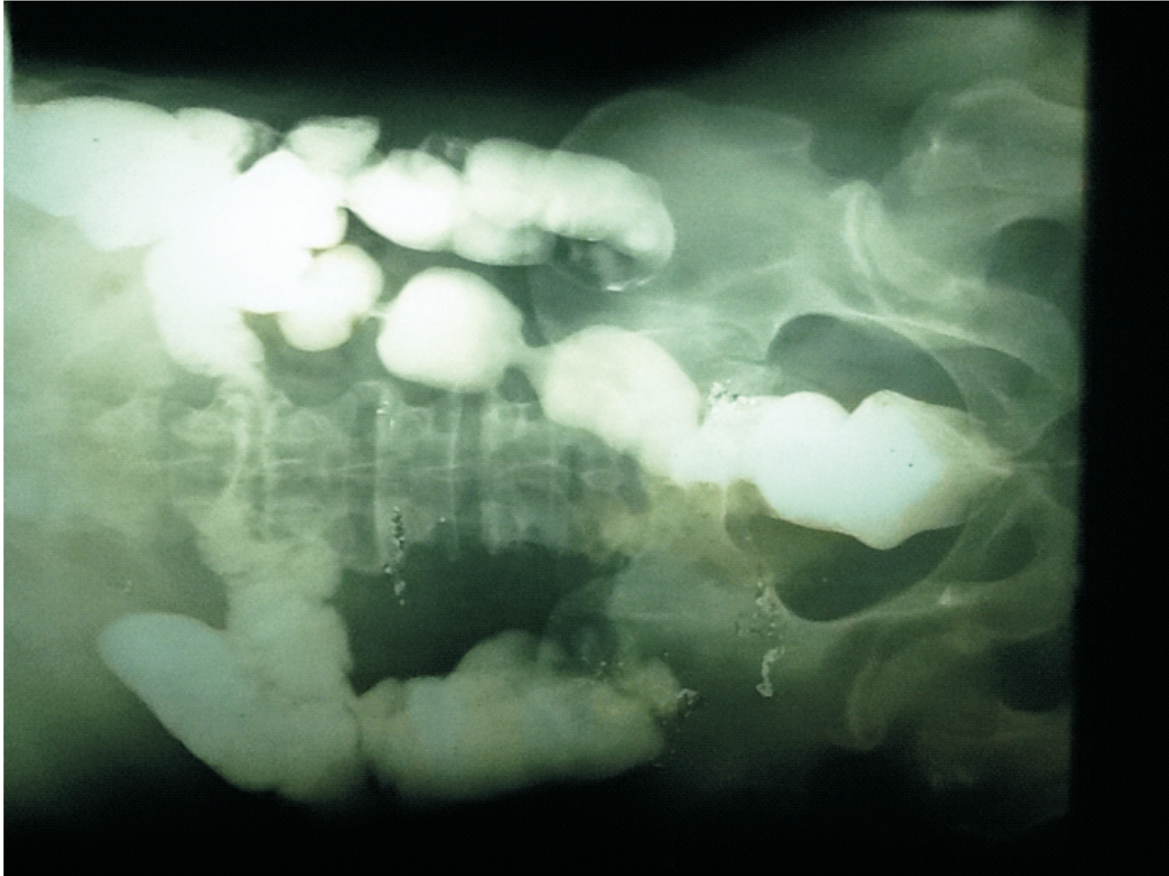
The post operative period was uncomplicated. Colostomy started functioning on 3rd day and graded oral intake was commenced. After removal of stitches, patient was discharged on the 9th day. Histology of the resected specimen showed moderately differentiated adenocarcinoma of the colon.

Two weeks after discharge from hospital, he was commenced on chemotherapy. He received six courses of oxaliplatin and capecitabine at three-weekly intervals. After the 3rd course and following a normal barium loopogram, he had reversal of transverse

colostomy. Subsequently, he had radiotherapy. He has been followed up regularly in the surgical outpatient clinic and has no repeat symptoms. He has had CEA, barium enema and abdominopelvic

ultrasound. Anastomosis site can be felt per rectum and is not stenosed. Sigmoidoscopy done at 20 months showed normal mucosa and no evidence of metachronous tumour.

Fig I - Patient's barium enema



DISCUSSION

Oncologic surgery was born in excessive radicalism but modern Oncologic surgery has become organ sparing and restorative . The introduction of new technique has enabled more patients with low rectal cancer to undergo sphincter saving resections^{3,5,6}. This could be achieved with good control of local disease and improved functional outcome and self image for the patient without sacrificing survival^{5,7,8,9}.

We reported a case of sphincter saving low anterior resection with the preservation of bladder and sexual functions. This was the first of such case in our centre (to the best of our knowledge) where availability of equipment and technical support, including stapling gun, is a problem.

The problem of colorectal anastomosis is anastomotic leakage and its attendant morbidity and mortality; and is more in anastomosis in low rectal carcinoma^{10,11}.

This is due to the difficulty in performing an anastomosis with a good integrity in the depth of the pelvis. This risk of anastomosis leakage is more in men. This is due to the pelvic cavity being more capacious in women generally. In the reported case, we were able to do a hand sewn anastomosis for a tumour 8cm from the anal verge in a man.

To protect against a possible anastomotic leakage, the patient had a diverting transverse colostomy. Studies have shown the ability of a diverting stoma to reduce the likelihood of anastomosis leakage after low anterior resection^{10,11,12}.

The major concern of those opposing sphincter preserving surgeries in low rectal carcinoma has been the problem of local recurrence of disease and sacrificing cure for sphincter preservation^{5,13}. The patient has been followed up for a 25 month period and there is yet no evidence of local recurrence or systemic disease progression.

CONCLUSION

In carefully selected patients and making use of adjuvant chemotherapy and radiotherapy, sphincter saving surgeries can be done for low rectal cancer, even in the absence of stapling gun.

REFERENCES

- 1 Guerriero O, Tufano G, Pennetti L, D'Amore E, Samella G, Sodano B. Sphincter saving surgery in low rectal cancer. *Chirurgia Italiana*. 2006; 58(1):83-92.
- 2 Scrumé C, Geraci G, Pisello F, Arnone E, Romeo M, Modica G. Mechanical versus manual anastomosis in colorectal surgery: Personal experience. *G. Chir*. 2008 Nov- Dec; 29(11-12):505-10.
- 3 Pappalardo G, Spoleitini D, Nunziale A, Manna E, De Lucia F, Frattaroli FM. The surgical treatment of the subperitoneal rectal cancer. *Ann. Ital Chir*. 2010 Jul- Aug; 81(4):255-63.
- 4 Di Beta E, D'Hoore A, Filez L, Pennickx F. Sphincter saving rectum resection is the standard procedure for low rectal cancer. *Int. J Colorectal Dis*. 2003; 18:463-469.
- 5 Williams NS, Durdey P, Johnston D. The outcome following sphincter-saving resection and abdomino-perineal resection for low rectal cancer. *Br. J. Surg*. 1985; 72:595-598.
- 6 Williams NS. The rationale for preservation of the anal sphincter in patients with low rectal cancer. *Br. J Surg*. 1984 Aug; 71:575-581.
- 7 Rullier E, Laurent C, Carles J, Michel P, Parneix M. Local recurrence of low rectal cancer after abdominoperineal and anterior resection. *Br. J Surg*. 1997 Apr; 84(4):525-528.
- 8 Dixon AR, Maxwell WA, Holmes TJ. Carcinoma of the rectum: A 10- year experience. *Br. J. Surg*. 1991 Mar; 78(3):308-311.
- 9 Camilleri-Brennan J, Steele RJC. Objective assessment of morbidity and quality of life after surgery for low colorectal disease. *Br. J Surg*. 2002 Jan; 4(1):61-66.
- 10 Rullier E, Laurent C, Garrelon JL, Michel P, Saric J, Parneix M. Risk factors for anastomotic leakage after resection of rectal cancer. *Br. J Surg*. 1998 Mar; 85(3):355-358.
- 11 Chude GG, Rayate NV, Patris V, Koshariya M, Jaqad R, Kawamoto J, Lyqidakis NJ. Defunctioning loop ileostomy with low anterior resection for distal rectal cancer: Should we make an ileostomy as a routine procedure? A prospective randomised study. *Hepatogastroenterology*. 2008 Sep- Oct; 55(86-87):1562-7.
- 12 Mathiessen P, Hallbook O, Rutegard J, Simmert G, Sjodahl R. Defunctioning stoma reduces symptomatic anastomotic leakage after low anterior resection of the rectum for cancer: a randomised multicentre trial. *Ann. Surg*. 2007 Aug; 246(2):207-14.
- 13 Kumar H. Rectal cancer recurrence: factors and mechanisms. *Colorectal Disease*. 2000 May; 2(3):126-136.