

## SYNCHRONOUS BILATERAL URETERAL LIGATION AND URINARY BLADDER INJURIES FOLLOWING EMERGENCY HYSTERECTOMIES: EARLY SURGICAL INTERVENTION IS A RESUSCITATORY MEASURE.

Obiesie E.A<sup>1</sup>, Orakwe D.E<sup>1</sup>, Nwadi U.V<sup>1</sup>, Nwofor A.M.E<sup>1</sup>, Oranusi C.K<sup>1</sup>, Mbaeri T.U<sup>1</sup>, Abiahu J.A<sup>1</sup>, Onu O.A<sup>1</sup>, Odo C<sup>2</sup>, Agbanu C.M<sup>3</sup>, Mbonu O.O<sup>1</sup>

### ABSTRACT

*Synchronous iatrogenic ureteral and bladder injuries following emergency pelvic surgeries, though uncommon, cause morbidities and mortalities. They are potential causes of severe and debilitating obstructive nephropathies as well as avoidable litigations in surgical practice. Delay at initiating surgical treatment worsens outcome. Management is extremely challenging with attendant complications.*

*We report two cases of iatrogenic bilateral ureteral ligation with synchronous posterior urinary bladder lacerations. Both patients developed anuria at the immediate post-operative period, with worsening bilateral flank pains, abdominal distension, leakage of urine per vaginam and poor performance status. Both patients were uremic. Emergency exploratory laparotomies were done, with release of ligatures, stenting of both ureters and repair of bladder wall. Accurate diagnosis with early surgical intervention is lifesaving.*

**Key words:** Ureteral ligation, uremia, bladder trigonal injury, hysterectomy

**Cite This Article As:** Obiesie E.A, Orakwe D.E, Nwadi U.V, Nwofor A.M.E, Oranusi C.K, Mbaeri T.U, Abiahu J.A, Onu O.A, Odo C, Agbanu C.M, Mbonu O.O. Synchronous Bilateral Ureteral Ligation And Urinary Bladder Injuries Following Emergency Hysterectomies: Early Surgical Intervention Is A Resuscitatory Measure. Afrimedical Journal 2022; 8(1): 42-46.

### INTRODUCTION

Iatrogenic urologic injuries can complicate pelvic surgeries. These can be unilateral ureteric injuries, bilateral ureteric injuries, vesico-vaginal fistulae and bladder injuries<sup>1</sup>. These result from the close proximity of these organs to other pelvic organs. Incidence has been reported to be about 0.2–1% of all pelvic surgeries, and it has been noted to be higher in emergency obstetric/gynecological pelvic surgeries<sup>1</sup>. The risk of ureteral injury is increased by

conditions causing altered ureteral anatomy like malignancies involving pelvic organs, adhesions from previous pelvic surgeries, or adverse intra-operative events that impair vision such as hemorrhage<sup>2</sup>. Mechanisms of injury include kinking, skeletonization, crushing, ligation, transection and/or resection. When it is bilateral, it may result in anuria, fluid overload, renal failure and even death<sup>3</sup>. Ureteral injuries can be identified intra-operatively by leakage of urine into operative field, proximal distension of the ureters, non-draining urethral catheter and/or reduced urinary output. This allows prompt repair with less morbidity. However, majority of cases are identified post-operatively following manifestation of symptoms from the injury<sup>4</sup>.

The urinary bladder is the most common urological organ damaged during gynecological procedures, with an incidence of 0.14 - 3.17% in literature<sup>5</sup>. Identified risk factors for iatrogenic bladder injury include anatomic variations, inefficient exploration, adhesions, scars secondary to previous surgeries, pelvic irradiation, pelvic malignancies, pelvic inflammatory diseases and operating with a full bladder<sup>6</sup>. The most frequent pattern of iatrogenic injuries is bladder laceration with or without vesicovaginal fistula<sup>7</sup>. Synchronous iatrogenic bilateral ureteral and urinary bladder injuries are extremely rare. In this report, we present two cases of synchronous bilateral ureteral ligation and extensive trigonal bladder injuries. Both patients had emergency exploratory laparotomies with release of ligatures, stenting of ureters and repair of bladder wall.

These early surgical interventions resulted in marked improvement in renal functions and performance status of these patients. This report highlights the importance of prompt diagnosis and early surgical intervention as adjuncts in the resuscitation, diagnosis and treatment of patients with synchronous iatrogenic bilateral ureteral and urinary bladder injuries.

### CASE 1

She was a 34 year old para<sup>4+1</sup>, alive 3 woman referred from a maternity on account of prolonged labor following failed induction of labor with very high dose misoprostol. On presentation, patient and baby were in distress. A clinical diagnosis of abruptio placenta was made at the referred tertiary hospital, and an emergency caesarian section was done by a specialist. Intra-operative findings revealed a

<sup>1</sup> Division of Urology, Department of Surgery, Nnamdi Azikiwe University Awka, Nnewi Campus, Anambra State.

<sup>2</sup> Department of Surgery, Alex-Ekwueme Federal University Teaching Hospital, Abakaliki, Ebonyi state.

<sup>3</sup> Department of Obstetrics and Gynaecology, Nnamdi Azikiwe University Teaching Hospital, Nnewi, Anambra State.

Corresponding author: ea.obiesie@unizik.edu.ng. +2348034012598

©2022 Afrimedical journal. This work is distributed under the terms of the Creative Commons Attribution License which permits unrestricted use, distribution and reproduction in any medium, provided the original work is properly cited.

ruptured uterus with an extruding baby via a posterior uterine rent. There was hematoma in the right broad ligament. Attempts at repair was said to be unsuccessful and an emergency subtotal hysterectomy with right salpingo-oophorectomy was done through the Pfannenstiel incision. Post-operatively, she made no urine, and complained of abdominal and flank pain. She also noted soaking of her vaginal pad with urine. Examination revealed severe abdominal tenderness. Her condition subsequently worsened with severe breathlessness, necessitating commencement of intranasal oxygen at 10L/min.

She was uremic with urea level of 12.3mmol/l and creatinine level of 385µmol/l. Performance status was ECOG-4. Abdominopelvic ultrasound done showed bilateral grade 1 renal parenchyma disease. An empty urinary bladder was seen with a floating bulb of the catheter. Attempt to distend the bladder with fluid through the catheter resulted in fluid leakage through the vagina. A diagnosis of iatrogenic bladder / bilateral ureteral injuries complicated by vesico-vaginal fistula was made.

At re-exploration by a combined team of urologists and obstetricians/ gynecologists, through a midline infra-umbilical incision extending to her previous Pfannenstiel wound (inverted T -incision), it was found that the two ureters were tied with polyglactin sutures at about 4cm proximal to the vesico-ureteric junctions (figure 1). There was a longitudinal and ragged laceration of the posterior wall of the urinary bladder extending and, bivalving the trigone, with the cervical stump sutured to the posterior bladder wall (figure 1).

The ureteral ligatures were released and the two ureters stented with size 6 feeding tubes. The posterior bladder wall was closed in two layers, and the trigone reconstructed, after releasing the vaginal vault. An omental patch was used to reinforce the repairs (figure 2). The vaginal vault was subsequently closed with absorbable sutures.

A pelvic drain was left in-situ and patient was maintained on continuous bladder drainage with emphasis to adopt a prone / semi-prone position in the immediate post-op periods. She developed a deep surgical site infection which was managed by daily wound dressing. Ureteric stents were removed on day 14 post-operative period. She subsequently developed urine leakage per vaginam on the 16<sup>th</sup> day post-op which was confirmed with a cystogram. She

remained on continuous bladder drainage for about 8 weeks. The urine leakage improved markedly as she was using 2 fully soaked pad /day, against 5 used at the earlier stages. She was subsequently referred to a specialist center for vesico-vaginal fistula repair. Post op urea at discharge was 3.3mmol/l while creatinine was 88µmol/l, with satisfactory performance status (ECOG-0).

#### CASE 2

A 31 year old para <sup>4+0</sup> alive 4 woman who developed anuria on the 2<sup>nd</sup> post operative day, following an emergency subtotal hysterectomy by a general practitioner in a private hospital. She had earlier had an emergency Caesarian section at the same private hospital, for an abruptio placenta. She subsequently developed severe post-partum hemorrhage necessitating re-exploration.

She was uremic on presentation at the teaching hospital, with a poor performance status (ECOG-4). Urea was 22.2mmol/l while creatinine was 968µmol/l. Abdominopelvic ultrasound scan showed bilateral moderate hydronephrosis. She had two (2) sessions of haemodialysis, and subsequently had emergency re-exploration by a combined team of urologists and obstetricians/ gynecologists. Intra-operative findings were bilateral ureteric ligation, posterior urinary bladder tear extending to the trigone. Ureteral ligatures were released and both ureters stented.

The bladder wall was repaired. She was catheterized and maintained on continuous bladder drainage. Post operatively, the renal function test normalized and performance status improved. She developed pelvic abscess postoperatively and this was managed with percutaneous drainage and intravenous antibiotics. She also had surgical site infection which was managed by daily wound dressing. She subsequently developed urine leakage per vagina on the 15<sup>th</sup> day post-op and this was confirmed with a cystogram. She remained on continuous bladder drainage for about 6 weeks.

However, the urine leakage persisted. She was subsequently referred to a specialist center for vesico-vaginal fistula repair. Post op urea and creatinine at discharge were 3.8mmol/l and 92µmol/l respectively, with a satisfactory performance status (ECOG-0).

#### DISCUSSION

Emergency abdomino-pelvic surgeries may be complicated by injuries to contiguous organs, and

occasionally inadvertent retention of surgical materials and instruments<sup>8,9</sup>. The pelvic ureters are at increased risk of injury in obstetric and gynecological surgeries due to their proximity to the female genital organs. Measures to prevent ureteral injuries include good operative techniques and sound knowledge of the pelvic anatomy. There is need for adequate exposure, prior identification of the ureters in the operating field and strict avoidance of clamping blindly and mass ligation, especially in the presence of haemorrhage<sup>1</sup>.

The index cases had emergency subtotal hysterectomies through Pfannenstiel incisions. Surgical access would not have been optimal for emergency obstetric hysterectomies. Both patients had intractable hemorrhage on table. This can compromise vision, leading to inadvertent clamping and ligation of the ureters with the uterine arteries. Prophylactic ureteral stenting has been shown to reduce the occurrence of ureteral injury as it allows palpation and easy identification of the ureters. Intra-operative identification of ureteric and / or bladder injuries is important, as this offers better chances of on-table repair and prevention of attendant complications. A high index of suspicion of ureteral injury and prompt diagnosis with treatment is paramount to early normalization of renal function. Dyes like methylene blue, indigo carmine or sodium fluorescein can aid intra-operative localization of urinary tract injuries. Urinary tract injury can also be suggested by blood in the urine bag as in the 1<sup>st</sup> case. On-table retrograde pyelography done via a bladder incision can be used for more definitive assessment of both ureters<sup>10</sup>.

When injury is not identified intra-operatively, symptoms may appear in the days following surgery. These include hematuria, oliguria, anuria, abdominal pain/ swelling, flank pain, intestinal ileus, leakage of urine from pelvic drain or from the vagina, secondary hypertension and azotemia<sup>11</sup>. Post-operatively, diagnosis can also be made with the use of dye/swab tests, ultrasound scan, intravenous pyelogram, contrast computed tomography scan / magnetic resonance imaging<sup>1</sup>. The index patients had hematuria intra-operatively, and remained anuric subsequently, with complaint of abdominal pain, flank pain and leakage of urine from the vagina. Follow up abdomino-pelvic ultrasound scan showed evidence of obstructive uropathies. Retrograde filling of the bladder with saline via the urethral catheter resulted in leakage from the vagina, with poor delineation of the urinary bladder. Radiologic

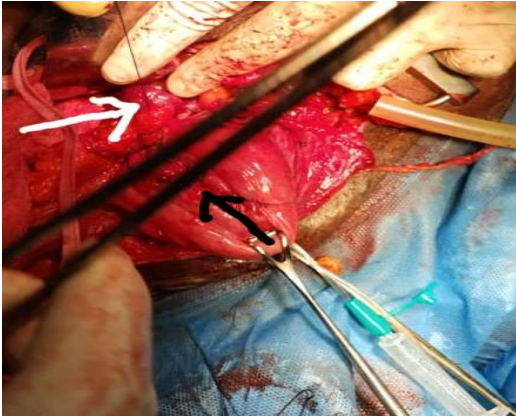
evidence of urinary obstruction such as hydro-uretero-nephrosis is usually not evident in the early post op hours, following onset of acute obstruction especially in the presence of severe dehydration.

This can account for the absence of back pressure changes on ultrasound<sup>12</sup>. Anuria suggests bilateral ureteral ligation. Early surgical re-exploration should be part of resuscitatory, diagnostic and treatment protocols as these patients become uremic with poor prognosis if intervention is delayed. Both index patients had relief of obstructive symptoms, improved performance statuses, as well as normalization of renal function following re-exploration and release of ureteric ligatures and repair of urinary bladder walls.

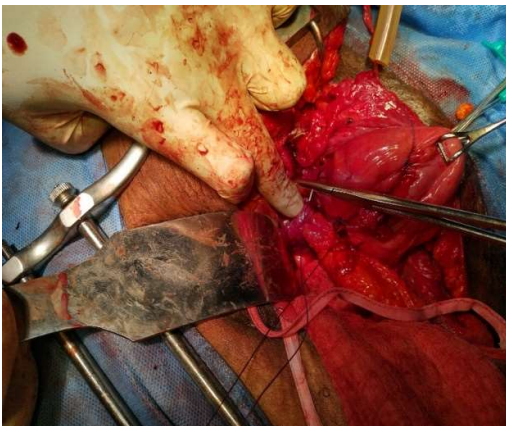
The most common mechanism of iatrogenic ureteric injuries is ligation approximately 4cm from the uretero-vesical junction<sup>13</sup>. This was identified in the index patients, and this usually follow attempts at ligating the uterine arteries. Risk factors include severe hemorrhage that obscures vision as well as limited exposure from Pfannenstiel incision as recorded in these two patients<sup>12</sup>.

The first case (case 1) had sustained urinary leak, and no hydronephrosis on ultrasound, while Case 2 had significant improvement in performance status, following courses of haemodialysis hence no surgical indication for percutaneous nephrostomies.

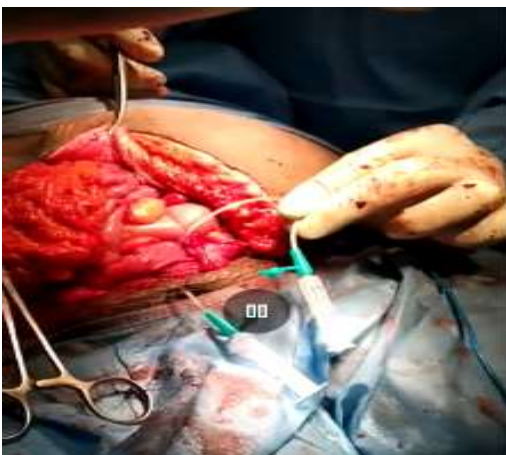
To ensure a good surgical outcome, urgent re-exploration using an adequate surgical access, identification of injuries, prompt release of ligatures with double layer repair of urinary bladder are necessary adjuncts. An omental patch can be used to reinforce the bladder wall repair as demonstrated in figure 2. The post-operative management protocol should be detailed and diligently observed. All drains should be patent and the patient should adopt a prone/ semi prone position to encourage healing of the posterior bladder wall.



**Fig1. White arrow shows tied and bunched left ureter, while black arrow shows lacerated posterior bladder wall.**



**Fig 2. Repair of posterior bladder wall with omental patch.**



**Fig 3. Active bilateral ureteric stents**

#### **CONCLUSION**

Synchronous iatrogenic ureteral ligation and bladder injuries still remain regrettable complications of emergency pelvic surgeries, with debilitating

sequellae. Prompt diagnosis and early surgical re-exploration is resuscitatory, diagnostic and therapeutic.

#### **ETHICAL CONSIDERATION**

Written informed consents were obtained from the patients, for the publication of these reports as well as the accompanying images.

Ethical approvals were gotten from the institutions.

#### **CONFLICTING INTERESTS**

The authors declare that they have no conflicting interests.

#### **REFERENCES**

1. Ade-ojo IP, Tijani O. A Review on the Etiology, Prevention , and Management of Ureteral Injuries During Obstetric and Gynecologic Surgeries. *Int. J Womens Health.* 2021;13:895–902.
2. Iduh OE, Onwukwe J, Hembah-Hilekaan S. Ureteric injuries associated with hysterectomy: A five-year experience in treating seventeen ureteric units in nine patients. *Ann Med Res Prac* 2020;1(3):1–4.
3. Mensah JE, Klufio GO, Ahiaku F, Osafo C, Gepi-Attee S. Delayed recognition of bilateral ureteral injury after gyneacological surgery. *Ghana Med J.* 2008;42(4):133-136.
4. Tijani KH, Onwuzurigbo KI, Ojewola RW, Afolabi BB, Akanmu NO. Iatrogenic Ureteric Injuries in a Nigerian Teaching Hospital- Experience in the last decade. *East Afr Med J.* 2011;88:15-20.
5. Armenakas NA, Pareek G, Fracchia JA. Iatrogenic bladder perforations: long term follow-up of 65 patients. *J Am Coll Surg.* 2004;198(1):78–82.
6. Phipps MG, Watabe B, Clemons JL, Weitzen S, Myers DL. Risk factors for bladder injury during Cesarean delivery. *Obstet Gynecol.* 2005;105:156-160.
7. Başaranoğlu S, Deregözü A, Köroğlu N, Kalkan M, Şahin C, Kadanalı S. Early and Late Diagnosis of Iatrogenic Urinary Tract Injuries During Obstetric and Gynecological Operations. *J Clin Exp Investig.* 2016;7(3):252–257.
8. Menkiti F E, Obiesie\_E A, Onyiaorah I V, Ochiabuto C, Okafor P I S. Gossypiboma

- 
- Mimicking Intra-abdominal Tumor. *Orient Journal of Medicine* 2021;33 (3-4):123-126
9. Obiesie E A, Nwadi U V, Oranusi C K, Nwofor A M E, Odo C, Mbaeri T U, Nwobi A N, Azubuike I R, Okoye O A, Mbonu O O. Retained surgical instruments in the pelvis complicated by colovesical fistula. *Orient Journal of Medicine* 2022; 34 (3-4):107-112
  10. Burks FN, Santucci RA. Management of Iatrogenic Ureteral Injury. *Ther Adv Urol.* 2014;6(3):115–124.
  11. Lawal O, Bello O, Morhason-Bello I, Abdus-salam R, Ojengbede O. Our Experience with Iatrogenic Ureteric Injuries among Women Presenting to University College Hospital, Ibadan: A Call to Action on Trigger Factors. *Obstet Gynecol Int.* 2019;2019:6456141.
  12. Adejumo OA, Ogundiniyi OS, Akinbodewa AA, Adesunloro LA, Olafisoye OJ. Acute Kidney Injury Secondary to Iatrogenic Bilateral Ureteric Ligation following Emergency Abdominal Hysterectomy. *Hig Med Res J.* 2016;16(1):42–44.
  13. Chinakwana GU, Okafor PI, Ikechebelu JI, Mbonu O. Urology Injuries Following Gynaecological Operation – our experience in a teaching hospital in Nigeria. *West Afr. J. Med.* 2006;25(2):153-156.