

RIGHT POSTERIOR DIAPHRAGMATIC HERNIA WITH OMPHALOCELE; MANAGEMENT CHALLENGES AND BENEFITS OF MULTIDISCIPLINARY AND MULTI-INSTITUTIONAL COLLABORATION IN A RESOURCE POOR SETTING

Ugwu J O¹, Etukokwu K C², Ufoegbunam M P³, Ugwunne C A¹, Ugwu N O⁴

ABSTRACT

Right posterior congenital diaphragmatic hernias (CDH) with liver herniations pose a huge management challenge to the paediatric surgeons world over. Its association with anterior abdominal wall defects portends a poorer prognosis.

We report a case of a day- old male referred to our centre with breathlessness, anterior abdominal wall defect and persistent poor oxygen saturation. Clinical and imaging evaluations aided the diagnosis of a right posterior congenital diaphragmatic hernia with omphalocele and divarication of recti. Due to dearth of resources, a multidisciplinary team of paediatric surgeons, cardiothoracic surgeon, paediatricians and an intensivist were assembled and care was undertaken in two centres to complement in manpower and facility deficiencies. This in so many ways mitigated against likely management difficulties, morbidities and even mortality

CONCLUSION; *Right congenital diaphragmatic hernias (CDH) in a resource constrained environment can be successfully managed with good clinical and multicentre collaborations.*

KEYWORDS: *Neonates, Congenital diaphragmatic hernias, omphaloceles, multidisciplinary care.*

Cite this article as: Ugwu J O, Etukokwu K C, Ufoegbunam M P, Ugwunne C A, Ugwu N O. Right Posterior Diaphragmatic Hernia with Omphalocele; Management Challenges and Benefits of Multidisciplinary and Multi-Institutional Collaboration in a Resource Poor Setting.

Afrimed Journal 2021; 7(1): 43-49.

INTRODUCTION

Congenital diaphragmatic hernias are quite common among Caucasians but are rare amongst Nigerians and African Children, this perhaps is due to paucity of diagnosis and underreporting.^{1,2} The posterior hernia of Bochdalek is more common than the anterior hernia of Morgagni, however the right posterior diaphragmatic hernia are less common than the left which occurs in 85% of the cases.³

Right congenital diaphragmatic hernias with liver herniation are quite rare, occurring in 8% of the cases and liver herniation worsens prognosis with high mortality.^{1,4,5} Prognosis is further worsened amongst children who present with symptoms during the neonatal period and those with associated anterior abdominal wall defects.^{1,6} Poor prognosis has been adduced to be as a result of

¹Paediatric Surgery Unit, Department of Surgery, Nnamdi Azikiwe University Teaching Hospital, PMB 5025, Nnewi, Anambra State, Nigeria

²Cardiothoracic Surgery Unit, Department of Surgery, Nnamdi Azikiwe University Teaching Hospital, PMB 5025, Nnewi, Anambra State, Nigeria

³Department of Anaesthesia, University of Nigeria Teaching Hospital, Enugu Nigeria

⁴Department of Paediatrics, Nnamdi Azikiwe University Teaching Hospital, PMB 5025, Nnewi, Anambra State, Nigeria

*Corresponding Author: Email: ugwuidefor@yahoo.com +2348177922006

©2021 Afrimed Journal. This work is distributed under the terms of the Creative Commons Attribution License which permits unrestricted use, distribution and reproduction in any medium, provided the original work is properly cited.

diagnostic delays, unavailability of neonatal intensive care and Extracorporeal membrane oxygenation (ECMO).¹ There is gross dearth of these facilities in low income countries like Nigeria.

We therefore report a case of right posterior diaphragmatic hernia with liver herniation and omphalocele in a neonate who was managed in two specialist centres by assembly of specialists from different disciplines. This is to highlight the challenges in a low income countries and how collaborations can be of help.

Case Summary

Baby O U, a day old male referred from a private hospital with complaints of breathlessness, and anterior abdominal defect. The breathlessness worsened with time but no history of cyanosis, drooling of saliva, neither cough nor vomiting. The defect in the anterior abdominal wall was said to be more prominent on crying and the umbilical stump was attached on it. Patient had passed meconium. Pregnancy was supervised in a private hospital from 8 weeks and prenatal ultrasound scan revealed no anomaly. There was no maternal ingestion of herbs or local concoctions. Examination findings were that of a baby in respiratory distress, not pale and acyanosed. Respiratory rate was 110/min, Heart rate was 130/min, temperature- 36.8degrees Celsius. The SpO2 was between 67-76% with intranasal

oxygen. There was reduction in the excursion of the right hemithorax with dull percussion notes and reduced air entry.

There was an anterior abdominal wall defect of about 4cm covered with a membrane; the umbilical stump was attached to its apex. The surrounding anterior abdominal wall was lax with divarication of the recti (see fig 1). A diagnosis of right diaphragmatic hernia with omphalocele was made. Abdominopelvic ultrasound showed herniation of the right liver into the thoracic cavity. Chest x-rays showed a right homogenous opacity contiguous with the cardiac shadows. There was a scanty lucent area at the upper lung zone and the diaphragmatic outline was not appreciated. Thoracoabdominal computed tomographic scanning showed a right diaphragmatic defect 3.24cm with hepatic herniation (see fig 2). Haematocrit and blood urea, creatinine and serum electrolytes were all within normal limits.

He was commenced on intranasal oxygen, vitamin K, parenteral antibiotics and intravenous amino acids. The cardiothoracic unit was invited for review alongside the anaesthetists. The need for a ventilator was highlighted and patient was moved to another centre with a functional neonatal intensive care unit (NICU) for the surgery. Surgery was done under general anaesthesia with endotracheal

intubation and muscle relaxation on the sixth day of life. Findings were that of a right posterior diaphragmatic defect measuring 7x 4 cm, extending from the midline to the right costal margin. With the liver herniating into the right hemithorax, sparing only the distal part and gall bladder. The ipsilateral lung was hypoplastic and there was an incomplete malrotation syndrome. (fig 3 a and b) The liver was reduced and the diaphragm repaired primarily with nylon 0 in an interrupted fashion. Ladd's procedure was also done and a right chest tube (size 14 Fr) was placed in the right pleural cavity (fig 3c). The lungs were re-expanded as much as possible and patient was placed on mechanical ventilation for 48 hours after which he was weaned off and was placed on intranasal oxygen. He made sustained progress and was discharged after 8 days. He has been followed up for a year, three months—without any sequelae. He is now awaiting anterior abdominal wall repair. (see fig 4)

Discussion

Management of Congenital diaphragmatic hernia CDH remains a huge challenge to paediatric surgeons and the overall perinatal mortality remain high world over despite advances in care.^{1,3,5,7} The scenario is worse in low income countries due to unavailability of NICU, ECMO and prenatal diagnosis.¹ Right diaphragmatic hernias are rarer but with worse prognosis due to liver

herniation, pulmonary hypoplasia and persistent pulmonary hypertension.

Despite the prenatal ultrasound scan done on the mother of this index case, the anomaly was not detected until after birth when he presented with breathlessness and omphalocele necessitating a referral from a private hospital. The non detection from the prenatal ultrasound scan could be from inexperience or occasioned by the gestational age at which it was done. The combination of congenital diaphragmatic hernia and omphalocele portend a poor prognosis.⁸ Even though these could be part of syndromic anomalies, we could not clinically establish any other anomalies in the patient.

Aside from clinical assessment of patients with congenital diaphragmatic hernias, other invaluable investigations include prenatal ultrasound scan, chest x rays, upper gastrointestinal series, prenatal magnetic resonance imaging, echocardiography, computerized tomographic scans and karyotyping when syndromic associations are suspected.^{1,7,8,9} The diagnosis in the index patient was with the aid of ultrasonography which picked up the liver in the right hemithorax and findings were corroborated with chest x-ray findings. Furthermore, a computed tomographic scan done further confirmed the diaphragmatic defect,

liver herniation and its relationship with intrathoracic structures. Karyotyping and echocardiography could not be done as they were not available in our centre.

The patient required a pre- and post-operative ventilatory support as evidenced by the low oxygen saturation despite intranasal oxygen administration. Again neonatal ventilatory facilities were not available in our centre which necessitated arrangement for such assistance in a nearby alternative hospital. To obviate these challenges, a team of cardiothoracic surgeon, paediatric surgeons and an experienced intensivist (from another institution) were mobilized and the patient was moved to a nearby centre with requisite neonatal intensive care support for the repair.

Operative access for repair of congenital diaphragmatic hernias could be transthoracic, transabdominal and via laparoscopic approaches.¹ We chose the abdominal route bearing in mind the possibility of repair of the anterior abdominal wall defect and perhaps other concomitant malformations such as malrotation syndromes. With full muscle relaxation achieved by the anaesthetist, a primary repair without prosthesis was achieved and to reduce the intra-abdominal pressure, the anterior abdominal wall defect was not repaired as it provided extra domain for the returned viscera.

Patient was placed on high frequency oscillatory ventilation (HFOV) for 48 hours to ensure adequate lung expansion and improved spo2 after which he was weaned off to intranasal oxygen. He was subsequently transferred to the referring centre for continued post-operative care.

Conclusion

Right diaphragmatic hernias with anterior abdominal wall defects in a neonate has poor prognosis in resource-poor settings. Perhaps a multidisciplinary approach alongside mobilization of inter-institutional facilities may really give these neonates a chance. We also wish to emphasize the benefit of the anterior abdominal wall defect in this circumstance in creating additional domain to house the returning viscera.

References

1. Abubakar A M, Chinda J Y, Danladi K, Umar I M. Challenges in the management of early versus late presenting congenital diaphragmatic hernia in a poor resource setting. *Afr J Paediatr Surg* 2011;8:29-33
2. Odelola M A, Akinsulie A O. Right sided hernia of Bochdalek: A case report. *Niger J Paediatr* 2004;31(2):59-60
3. Shenoy K R, Johri G. Congenital right bochdaleck hernia presenting in old age: a case

- report. Indian J Surg 2013; 75:255-256
4. Banchini F, Santoni R, Banchini A, Bodni F C, Capelli P. Right posterior diaphragmatic hernia (Bochdalek) with liver involvement and alteration of hepatic outflow in adult: a case report. Springer plus 2016;5(1):1561
 5. Harrison M R, Bjordal R I, Langmark F, Knutrud O. Congenital diaphragmatic hernia: the hidden mortality. J pediatr Surg. 1978;13(3): 227-30
 6. Abdur-Rahman L O, Bamigbola K T, Adeoye P O, Akande H J, Nasir AA, Obasa T O. Late presentation of congenital diaphragmatic hernia in sub-saharan Africa: A call for screening and prompt treatment. J Med Trop 2016;18:1-5
 7. Tudorche S, Chiutu L C, Iliescu D G, Geogescu R, Stoica G A, Simionescu CE, Geogescu E F, Nemes RN. Prenatal diagnosis and perinatal outcome in congenital diaphragmatic hernia. Single tertiary centre report. Rom J Morphol Embryol. 2014;55(3): 823-33
 8. Scahill MD, Maak P, Kunder C, Halamek L P. Anterolateral congenital diaphragmatic hernia with omphalocele: a case report and literature review. Am J Med Genet A. 2013 ; 161(3): 585-8
 9. Kumar VHS. Current concepts in the management of congenital diaphragmatic hernia in infants. Indian J Surg. 2015;77(4)313-321
- Conflict of interest- None declared

Figure 1: Associated anterior abdominal wall defect

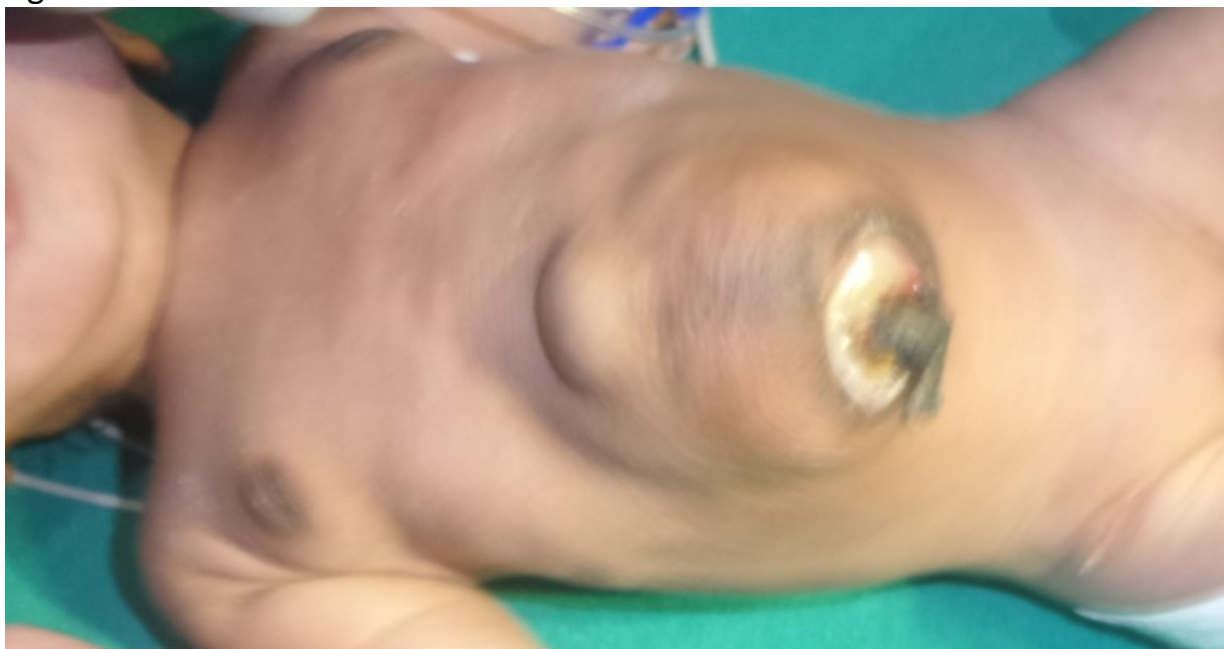


Figure 2: Thoracoabdominal computed tomographic scan showing the liver in the right hemi –thorax

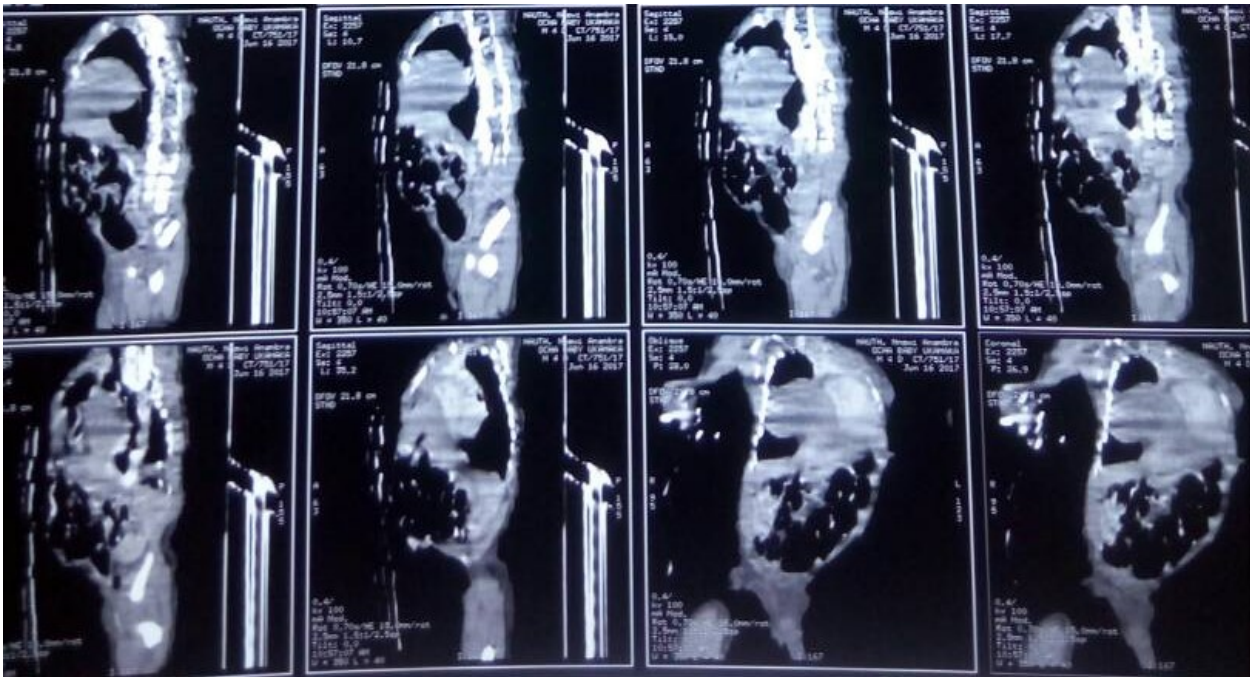


Figure 3: A- Associated malrotation syndrome and B-Diaphragmatic defect and right lung hypoplasia C- Repair with nylon sutures

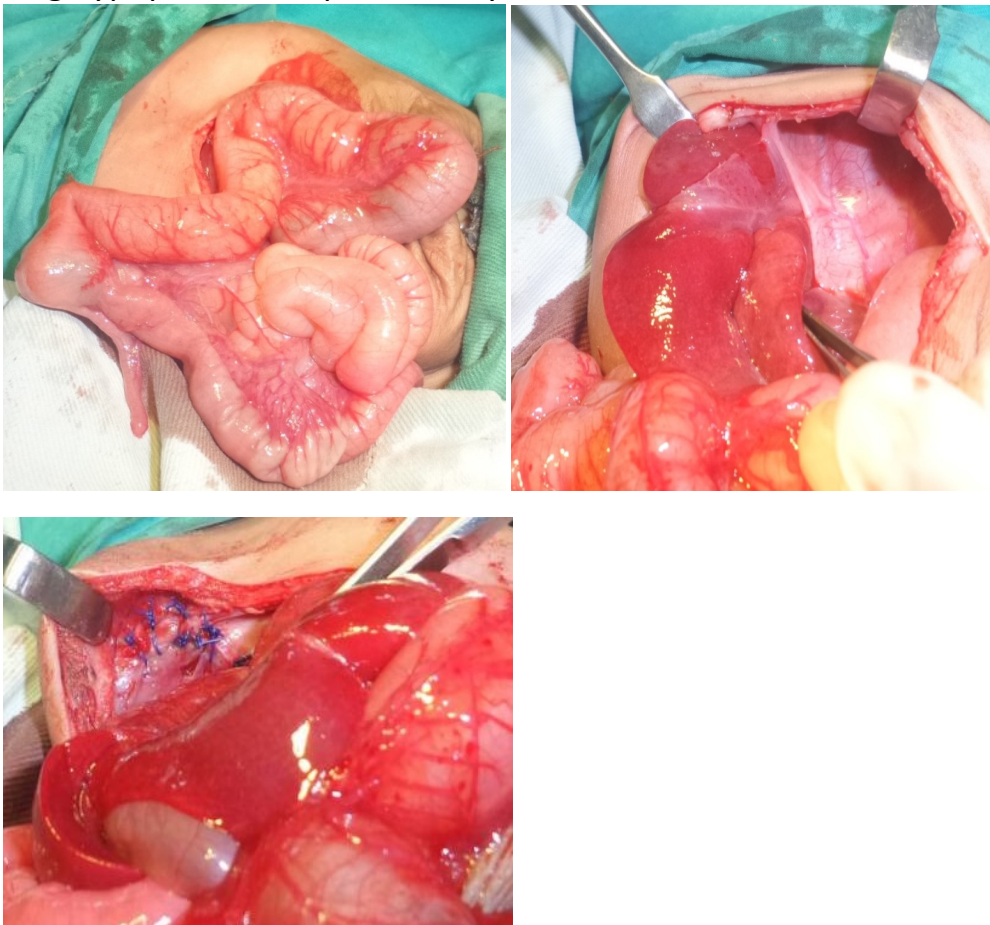


Figure 4: At one year follow-up with residual ventral hernia awaiting repair

