

Urachal Adenocarcinoma

Nguku S, Twahirwa N, Mburugu P, Rukaria K, Etabale J, Githae F, Tharao M.

Aga Khan University Hospital, Nairobi

Correspondence to: Dr. Samuel Nguku, P.O Box 30270-00100, Nairobi, Kenya. Email: samuel.gitau@aku.edu

Abstract

Urachal adenocarcinoma is a rare tumor and represents 0.17–0.34% of all bladder tumors. Most of the reported cases are in western literature and to the best of our knowledge this is the first case report of urachal adenocarcinoma in sub-Saharan Africa. It has an insidious course and variable clinical presentation. We present a case report of a 45 year old female with three

month history of hematuria. Imaging showed a bladder dome mass. After cystoscopy and biopsy, urachal adenocarcinoma was diagnosed histologically.

After a negative screen for distant metastasis based on CT chest and abdomen, the patient underwent anterior pelvic exenteration and ileal neo-bladder reconstruction. Six months later, the patient presented with chest metastases. Clinicians should have a high degree of suspicion for these rare tumors.

Introduction

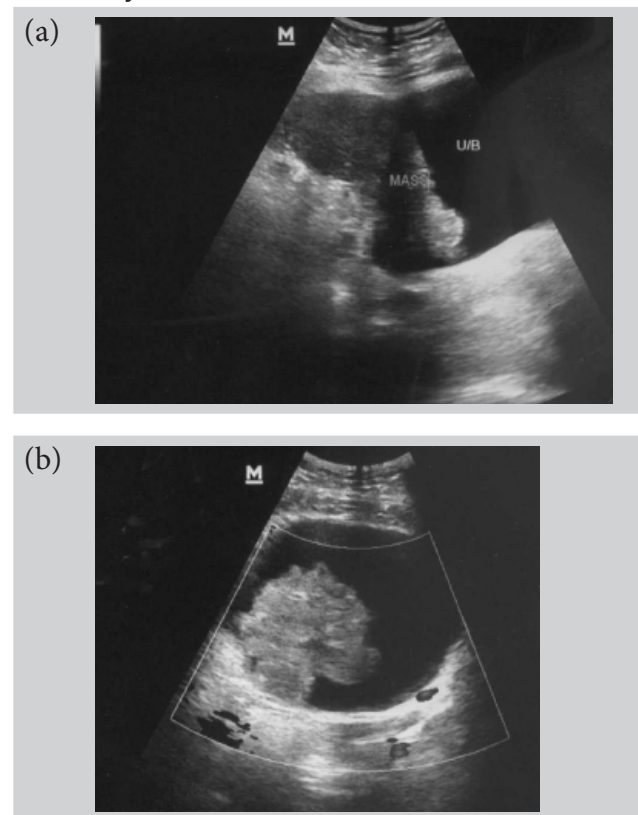
Primary urachal adenocarcinoma is a rare and devastating disease believed to arise from malignant transformation of columnar or glandular metaplastic epithelium (1). Clinically the distinction of urachal carcinoma from other bladder adenocarcinomas may be difficult especially if the tumor is locally extensive and as such imaging plays a vital role in the management of these patients(2). We present a rare case of urachal adenocarcinoma in a 45 year old female. The fact that the patient is female, no known risk factors and later presented with distant metastases only six months after a negative screen and extensive surgery makes this case even more unique.

Case Report

A 45 year old female presented to our facility with three months history of painless hematuria and menorrhagia. She had been treated severally for urinary tract infections. Past medical history was significant for symptomatic fibroids. There was no history of smoking. Physical examination revealed a mobile pelvic mass located in the midline.

An ultrasound (Fig. 1) revealed a poorly defined echogenic mass arising from the dome of the bladder. It had irregular margins but revealed no increased vascularity on Doppler studies. The uterus was bulky with multiple intramural fibroids.

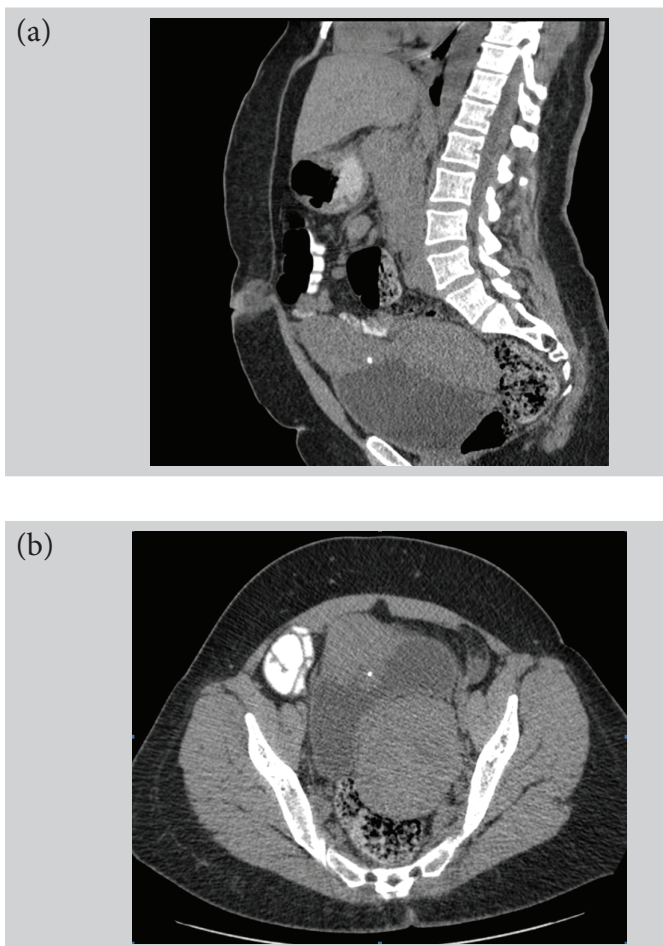
Figure 1: Ultrasound images (a) Sagittal section through the bladder reveals an echogenic mass arising from the dome of the bladder (b) Axial section with colour doppler showing no increased vascularity



The patient had cystoscopy done and biopsy of the mass taken. Histology revealed adenocarcinoma.

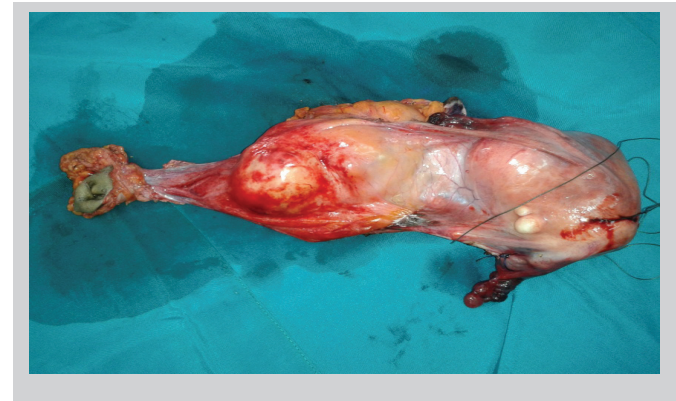
Staging dual contrast CT of the chest, abdomen and pelvis was done (Fig 2.). A soft tissue attenuating mass was seen arising from the midline of the dome of the bladder and extending towards the umbilicus. There was a focal calcification in its posterior aspect. A necrotic node was seen in the umbilicus. No pelvic or para-aortic lymphadenopathy was seen. The uterus was bulky secondary to uterine fibroids. The liver and the rest of the solid organs were normal. No chest metastasis was present.

Figure 2: CT Scan a.) Sagittal section b.) Axial section. A midline soft tissue attenuating mass arising for the dome of the bladder and extending towards the umbilicus. Focal calcification is seen in its posterior aspect. The uterus is bulky.



The patient had surgery where anterior pelvic exenteration and total hysterectomy was done (Fig 3). Ileal neo-bladder reconstruction was then performed.

Figure 3: Gross specimen of showing the umbilicus, urachau, the tumor and the urinary bladder.

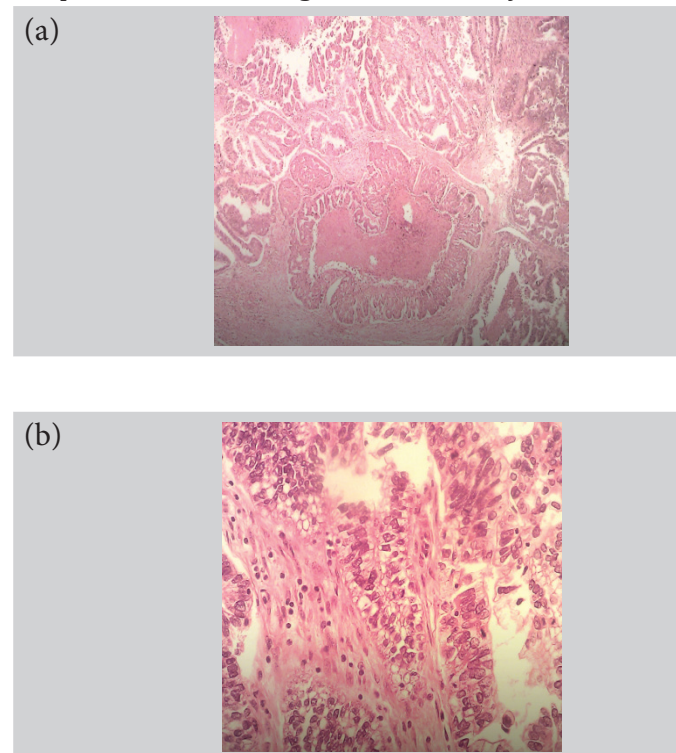


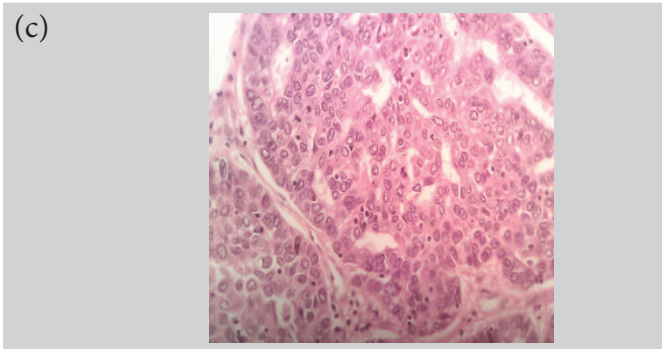
Histology (Fig 4) showed urachal adenocarcinoma. The necrotic node in the umbilicus was negative for metastasis.

Figure: 4: (a) Low Power (Haematoxylin & Eosin-stain) tumour section showing adenocarcinoma with a papillary pattern of growth and a central area of 'dirty' necrosis. There is a strong desmoplastic stroma response to tumour invasion.

(b) High power (H & E stain) section showing connective tissue cores lined by disorganised neoplastic columnar cells with loss of polarity.

(c) High power (H & E stain) section showing neoplastic cells with high mitotic activity.





Six months following the surgery, the patient had a screening CT scan of the chest which showed chest metastases.

Discussion

The urachus is a 5 – 6 cm vestigial structure located between the dome of the bladder and the umbilicus which results from the involution of the allantoic duct. It retracts from the bladder at birth but its lumen may persist and be continuous with the bladder cavity. It is lined by transitional or glandular epithelium (1, 2). Primary urachal neoplasms are rare tumors, representing less than 0.5% of all bladder cancers (3). These tumors are most commonly seen in patients 40–70 years of age, two-thirds of whom are men. Our patient happens to be a 45 year old female.

Although the normal urachus is most commonly lined by the transitional epithelium, urachal carcinoma predominantly manifests as adenocarcinoma (90% of cases), probably due to the metaplasia of the urachal mucosa into columnar epithelium followed by malignant transformation. Histological types include mucinous, enteric, unspecified, signet ring-cell, and mixed variants in order of reducing occurrence (4). Our patient had the enteric variant.

Primary urachal tumors are typically silent because of their extraperitoneal location; consequently, the majority of patients exhibit local invasion or metastatic disease at presentation. Our patient had painless hematuria for about three months. This presentation was likely secondary to the large intravesical extension of the tumor as evidenced by the initial diagnostic ultrasound.

Ninety percent of primary urachal carcinomas arise in the juxtavesical portion of the urachus and extend superiorly toward the umbilicus and inferiorly through

the bladder wall (5). The tumor in our patient was located at the dome of the bladder with an intravesical extension and a supravescical component along the urachal remnant. As such urachal carcinomas may be easily confused with primary tumors of the bladder dome (6); unlike vesical tumors, however, urachal tumors have a propensity to grow in the perivesical space toward the umbilicus as seen in our case. The node in the umbilicus was not positive for malignant cells.

As a primary diagnostic maneuver for unclear gross hematuria, cystoscopy reveals a tumor at the dome of the bladder in about 90% of the cases which was the case in our patient.

Ultrasound, computed tomography (CT), and magnetic resonance (MR) imaging have the ability to display cross-sectional images and therefore are ideally suited for demonstrating urachal anomalies. As in our case, most urachal carcinomas arise in the juxtavesical portion of the urachus. Peripheral calcifications in the soft-tissue-attenuation mass occur in 50%–70% of cases. They may be punctuate (as in our case), stippled, or curvilinear. Presence of calcification is considered almost pathognomonic for urachal adenocarcinoma (7).

Urachal carcinomas are usually locally advanced at presentation with a high risk of distant metastases. In our case, the neoplastic cells had invaded through the muscularis propria of the bladder. No distant metastases were present in the chest or abdomen as assessed by CT. Long-term survival following radical resection is said to occur in a significant fraction of patients, supporting an attempt at margin-negative, en bloc resection if at all possible (8,9). This informed the course of management of our patient who underwent anterior pelvic exenteration entailing removal of her reproductive organs, bladder and urethra. Despite this, our patient presented with distant metastases only six months down the line. Most reported cases of distant metastases in urachal adenocarcinomas tend to occur late. (10-11)

Chemotherapy appropriate for enteric type adenocarcinoma can induce objective responses but meaningful improvement in survival is not yet demonstrated. Our patient is currently under the oncology team and on palliative care.

References

1. Sheldon CA, Clayman RV, Gonzalez R, Williams RD, Fraley EE. Malignant urachal lesions. *J Urol* 1984; 131:1-8.
2. Yu JS, Kim KW, Lee HJ, et al. Urachal remnant diseases: spectrum of CT and US findings. *Radiographics*. 2001; 21(2):451-461.
3. Wilson TG, Pritchett TR, Lieskovsky G, et al. Primary adenocarcinoma of bladder. *Urology*. 1991;38:223-6.
4. Ravi R, Shrivastava BR, Chandrasekhar GM, et al. Adenocarcinoma of the urachus. *J Surg Oncol*.1992; 50:201-203.
5. Grignon DJ, Ro JY, Ayala AG,et al. Primary adenocarcinoma of the bladder: a clinicopathological analysis of 72 cases. *Cancer*. 1991; 67:2165-72.
6. Thali-Schwab CM, Woodward PJ, Wagner BJ. Computed tomographic appearance of urachal adenocarcinomas: review of 25 cases. *Eur Radiol*. 2005; 15:79-84.
7. Wong-You-Cheong JJ, Woodward PJ, Manning MA, et al. Neoplasms of the urinary bladder: radiologic-pathologic correlation. *Radiographics*. 2006; 26(2):553-580.
8. Mengiardi B, Wiesner W, Stoffel F, et al. Case 44: adenocarcinoma of the urachus. *Radiology* 2002; 222(3):744-747.
9. Siefker-Radtke A, Gee J, Shen Y, et al. Multimodality management of urachal carcinoma: The M.D. Anderson Centre experience. *J Urol* 2003; 169:1295-8.
10. Nesbitt JA, Walter PJ. Computed tomographic imaging of microscopic dystrophic calcification in urachal adenocarcinoma. *Urology*. 1986;27:184-186.
11. Molina et.al, Predictors of survival from Urachal cancer: A Mayo Clinic study of 49 cases. *Cancer*. 2007;110:2434-2440.