

Circumcision urethral injuries: outcomes of surgical intervention

Maranya GA^{1,2} MBChB, MMed, Cert.Urol.(E.A.), FCS(ECSA), FCS-Urol, **Mwero BJ**¹ MBChB, MMed, Dip. Hosp. Manag.(Israel), **Kinyanjui GM**¹ MBChB. *Affiliations:* 1- Moi District Hospital, Voi, 2- Coast Province General Hospital. *Correspondence:* Dr. Maranya GA, P.O. Box 91066-80103, Mombasa, Kenya. Email: maranya@wananchi.com

Abstract

Background: Urethral injuries due to circumcision are rare. Coverage of the repairs with well vascularised tissue is associated with excellent outcomes.

Objectives: To assess the outcomes of surgical intervention for urethral injuries of circumcision at two hospitals in the Coast Province of Kenya.

Design: A retrospective study of patients managed for urethral injuries due to circumcision, spanning 8 years, between 2004 and 2011.

Setting: Coast Province General Hospital, Mombasa (2004 -2008) and Moi District Hospital, Voi (2009 -2011).

Patients and methods: Records of 15 patients were analysed for age, diagnosis, surgical procedures and outcome. Thirteen patients with coronal or subcoronal urethrocutaneous fistula had repair and coverage of the reconstruction with dartos fascia. One patient with hypo-

spadiac meatal stenosis with chronic urine retention after circumcision had meatoplasty and tubularised incised plate hypospadias repair with dartos fascia coverage.

Urethral stricture at the level of the corona occurred in a 2.5 year old boy. He had suprapubic cystostomy to relieve urine retention. Augmented anastomotic urethroplasty with full thickness skin graft from the groin was done and the reconstruction covered with dartos layer.

Results: There was no recurrence or occurrence of urethral fistula in any of the patients.

The patient with meatal stenosis was noted to have mild torsion of the penis after surgery.

Conclusion: Use of dartos fascia to cover repairs of urethral injuries of circumcision produced excellent results with no recurrence or occurrence of urethral fistula.

Introduction

Circumcision is the most common operation performed on males worldwide; for cultural, religious and medical reasons (1-4).

Complications of the procedure vary from minor to tragic, these being: haemorrhage, infection, wound dehiscence, removal of incorrect amount of foreskin, glandular and penile injuries, glans and penile amputations, prepucioglandular fusion, glandular necrosis, splitting(opening) of the distal urethra, meatal stenosis, urethral fistula, lymphoedema, and painful scarring(1-8). Serious complications of circumcision are rare (4, 6, 7).

This study evaluates urethral injuries of circumcision and assesses the outcomes of surgery.

Patients and methods

This retrospective study on urethral injuries due to circumcision, covered 8 years at the Coast Province General Hospital (2004-2008) and Moi District Hospital, Voi (2009-2011) both in the Coast Province of Kenya.

Operation and case notes of patients treated for circum-

cision urethral injuries by the authors were reviewed, including a small number from the private practice of the first author.

Abstraction of patient demographics, presentation, diagnosis, surgical procedures and outcome was undertaken. Diagnosis was by clinical examination. No radiological investigations were performed.

Magnifying loupes were used in all the reconstructions. Urethrocutaneous fistulas were closed with 6/0 polyglactin either interrupted through and through or continuous subcuticular. All the repairs were covered with pedicled dartos layer; the superficial fascia of the penis which was mobilised from either the ventral or dorsal side of the penis. It was ensured, the suture lines did not oppose (Figure 1).

Subcoronal hypospadiac meatal stenosis with chronic urine retention occurred in an 11 year old boy following circumcision. Meatoplasty, tubularised incised plate hypospadias repair and dorsal penile dartos coverage were done.

Urethral stricture at the level of the corona in a 2.5 year old boy necessitated suprapubic cystostomy for urinary

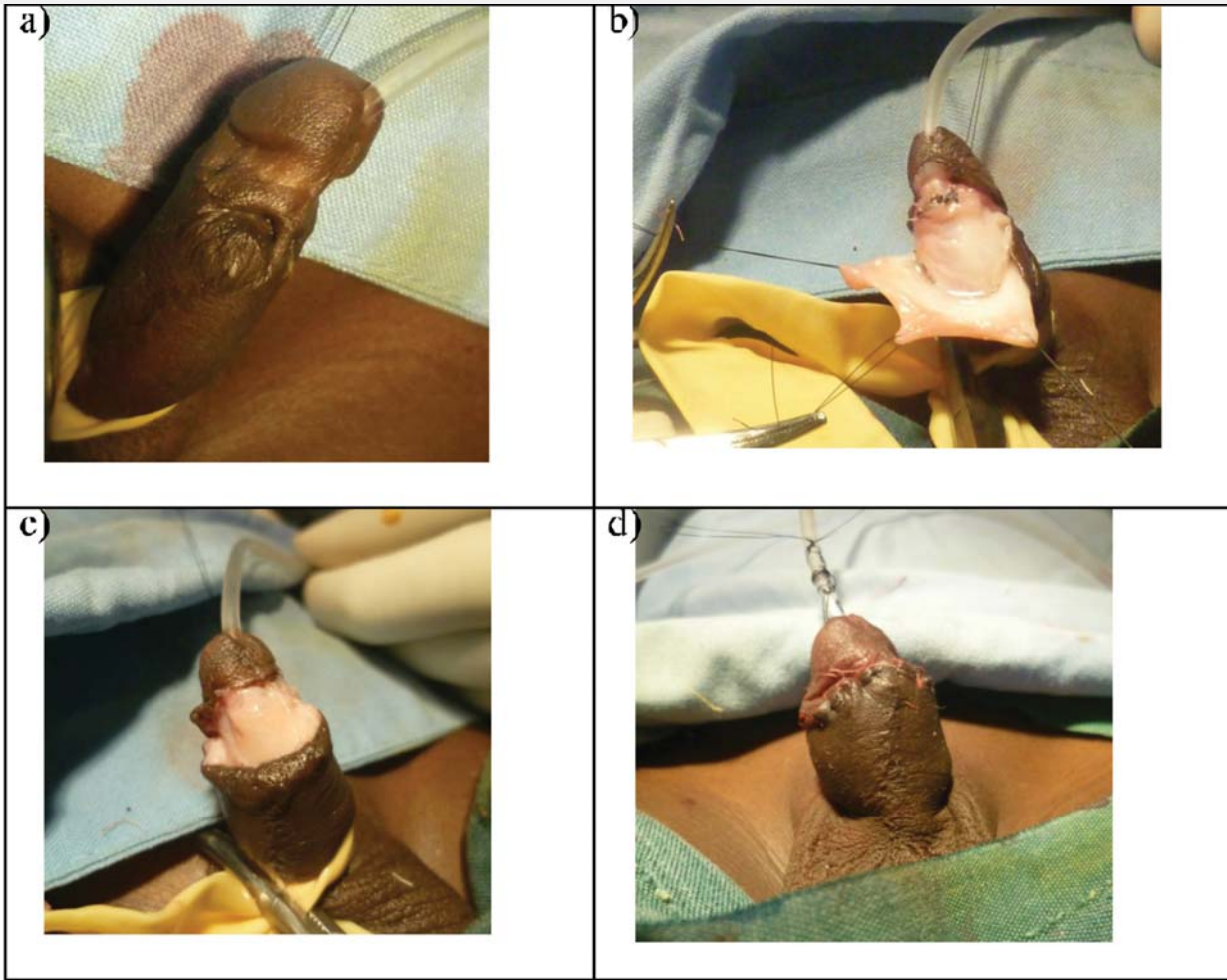


Figure 1: Urethrocutaneous fistula repair. (a) Subcoronal fistula. (b) Closure of fistula. Mobilisation of ventral dartos fascia. (c) Coverage of sutured fistula with dartos layer. (d) Completed reconstruction over a stent.

retention. Repair was by an augmented anastomotic urethroplasty with a full thickness skin graft from the groin, done 4 months after the circumcision (Figure 2). A urethral stent was used in all repairs.

Results

Fifteen patients with urethral injuries due to circumcision were studied (Table 1).

Age range was 1.5 - 24 years, median 6 years and mean of 8 years.

All the 13 patients with urethrocutaneous fistula had good results with no complication such as recurrence of the fistula. The patient with meatal stenosis had mild torsion of the penis after reconstruction. One patient, 2.5 years, with urethral stricture had a good result of normal, asymptomatic voiding following urethroplasty.

Discussion

In our study urethral injuries due to circumcision were rare considering the universal practice of male circumcision in the region for cultural and religious reasons. Similar observations have been made by other authors who report rare occurrence of serious adverse events of circumcision (1, 2, 4, 5, 7).

Urethrocutaneous fistulas were the commonest urethral injuries in our series. Previous authors (2, 6, 7) reported these as the commonest severe circumcision injuries. The fistulas were all coronal or subcoronal in location, in concurrence with other reports that give these sites as the commonest (2, 5, 9).

All our reconstructions were stented and covered with dartos fascia in tandem with the account of Mkony (9). The principle of coverage of a urethral repair with well

Circumcision urethral injuries: outcomes of surgical intervention

Maranya GA, Mwero BJ, Kinyanjui GM

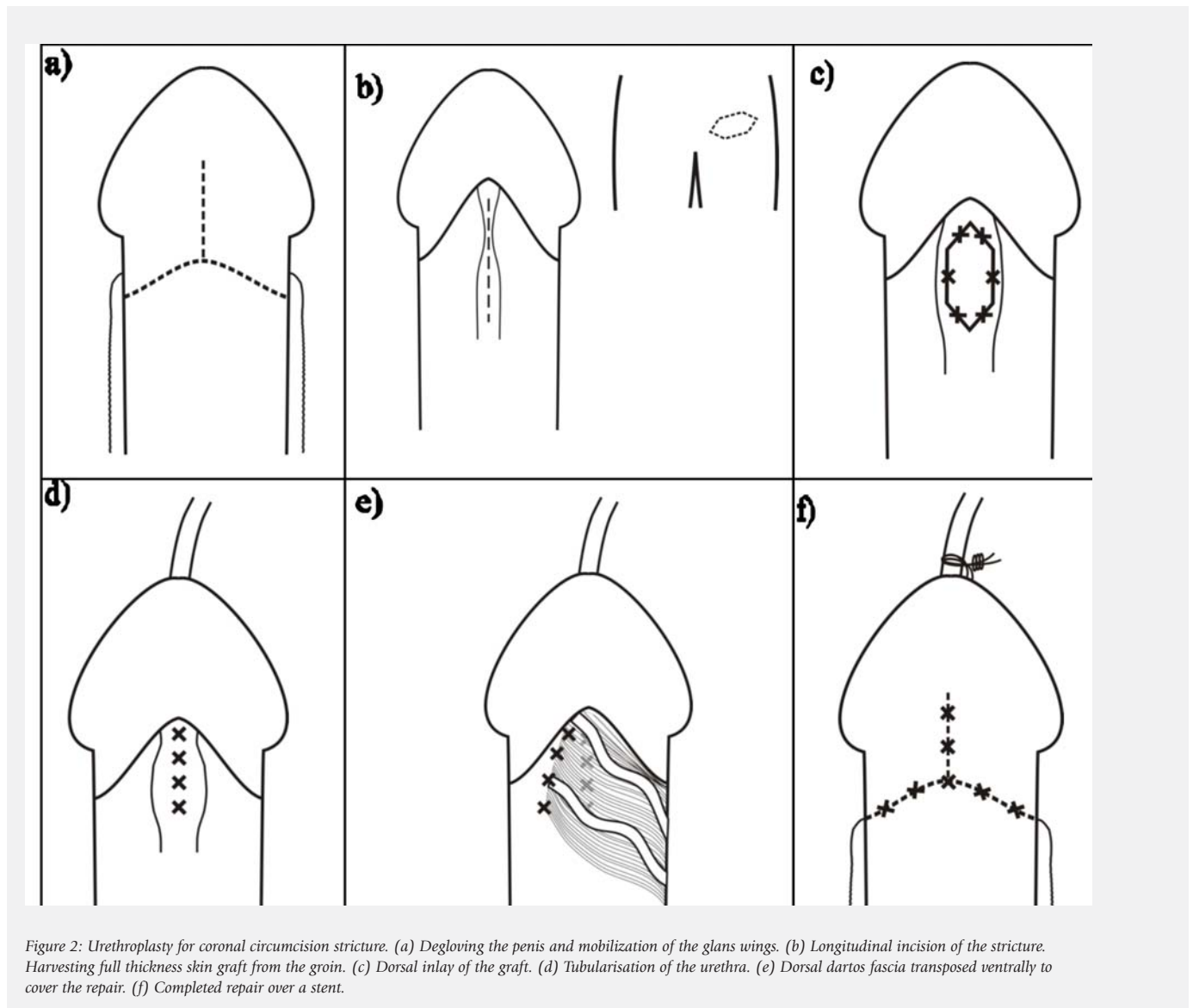


Figure 2: Urethroplasty for coronal circumcision stricture. (a) Degloving the penis and mobilization of the glans wings. (b) Longitudinal incision of the stricture. Harvesting full thickness skin graft from the groin. (c) Dorsal inlay of the graft. (d) Tubularisation of the urethra. (e) Dorsal dartos fascia transposed ventrally to cover the repair. (f) Completed repair over a stent.

vascularised tissue is also used in urethral fistulas resulting from hypospadias repair as dartos or other fascia coverage is associated with lower rates of urethral fistula recurrence (10, 11). The observation in our series of no recurrence or occurrence of fistula after reconstruction, is mainly attributable to coverage with the dartos layer (9-11). In contrast, simple fistula closure was associated with a higher recurrence rate as in the series by Latifoglu et al.(2).

In conclusion, the use of dartos fascia to cover reconstructions of urethral injuries due to circumcision was associated with excellent results with no recurrence or occurrence of urethral fistula.

Acknowledgement

I sincerely thank Jason Mwawana for the computer work and drawings and the Provincial Director of Medical Services, Coast Province, Kenya for authority to publish this article.

References

1. Ceylan K, Barhan K, Yilnaz Y et al. Severe complications of circumcision; an analysis of 48 cases. *Journ of Paed Urol* 2007; 3:32-35.
2. Latifoglu O, Yavuzer R, Unal S et al. Complications of circumcision. *Eur Journ. of Plast Surg* 1999;22:85-88.
3. Johnson PRV. Childhood circumcision. *Surg Int* 2008; 26:314-316.

Age/years	Injury	Number	Procedure	Outcome
Range: 1.5 - 24	Urethral fistula	13	Fistula closure over stent with dartos coverage	Normal asymptomatic voiding
Median : 6	Hypospadiac meatal stenosis	1	Meatoplasty and tubularised incised plate hypospadias urethroplasty	Mild penile torsion
Mean: 8	Urethral stricture	1	Augmented anastomotic urethroplasty with full thickness skin graft	Normal asymptomatic voiding.

Table 1: Surgery of urethral injuries due to circumcision

- Weiss HA, Larke N, Halperin D et al. Complications of circumcision in male neonates, infants and children: a systematic review. *BMC Urol* 2010; 10:2.
- Baskin LS, Canning DA, Snyder III HM, et al. Surgical repair of urethral circumcision injuries. *Journ. of Urol.* 1997; 158: 2269-2271.
- Oriaifo IO, Osifo OD, Circumcision mishap in Nigeria children. *Annals Afri. Med.* 2009; 8: 266-70.
- Sowande OA, Adejuyigble O. Circumcision mishap: a continuing challenge in the developing countries. *East, Centr. Afr. Journ. Surg.* 2009; 14: 109-113.
- Okeke LI, Asinobi AA, Ikuerowo OS. Epidemiology of complications of male circumcision in Ibadan, Nigeria. *BMC Urol* 2006; 6:21
- Mkony C A, Aboud M. Post-circumcision urethrocutaneous fistula: the Key to Successful Reconstruction. *East, Centr. Afr. Journ. Surg.* 2006; 11(1):118 - 120.
- Muruganandham K, Ansari MS, Dubey D, et al. Urethrocutaneous fistula after hypospadias repair: outcome of three types of closure techniques. *Paediatr. Surg. Int.* 2010; 26: 305-308.
- Holland AJA, Abubacker M, Smith GHH et al. Management of urethrocutaneous fistula following hypospadias repair. *Paediatr. Surg. Int.* 2008; 24: 1047 - 1051