

Experience with Hirschsprung's Disease at a Tertiary Hospital in Kenya

K. Ongeti, BSc., MBChB, Kikuyu Mission Hospital, Kikuyu, Kenya, **H. Saidi**, BSc, MBChB, MMed, FCS, FACS, Department of Human Anatomy, University of Nairobi, Kenya, **J. Ogeng'o**, BSc., MBChB, PhD and **M. Tharao**, BSc., MBChB, Aga Khan University Hospital, Nairobi

Corresponding author: K. Ongeti, Kikuyu Mission Hospital, Kikuyu, Kenya

Abstract

BACKGROUND: Hirschsprung's disease presents unique characteristics in Africans. Previous literature has reported high complication rates. We examined our single-institution experience with Hirschsprung's disease (HD) to evaluate outcomes related to the different phases of care.

STUDY DESIGN: Records were reviewed for children with HD managed during the years 2002 to 2006. Morbidities and mortalities were evaluated in relation to the different phases of care. Categorical variables were compared using Chi-square analysis.

SETTING: Kenyatta National Hospital (KNH) a teaching and referral hospital, Nairobi, Kenya.

RESULTS: One hundred and twelve patients with clinical diagnosis of HD were evaluated. Eighty nine had histological confirmation of HD. Forty four (39%) were aged 30 days or below. Eighteen children were lost to follow up before definitive diagnosis while a further 14 were lost after colostomy formation (before definitive surgery). Fifty six patients underwent definitive surgery (between one day and four years). Two had single-stage surgery while the rest had Swenson (52) and Boley's (2) endorectal pull-through after interim colostomies. Thirty nine of 69 patients (56.5%) developed complications related to colostomies or definitive care. Morbidity related to colostomy alone was 34.7% while that related to the

definitive surgery was 64.8%. There were sixteen deaths. The mean time to reversal for patients with colostomies was 23 ± 12 months. Colostomy duration of more than one year was associated with more complications, increased duration of hospital stay and overall length of management.

CONCLUSIONS: This retrospective review of a single-institution experience with treatment for HD has demonstrated a morbidity rate similar to other centres but a mortality rate higher than in published literature. Only 39% of patients with HD present during the neonatal period in our environment. The long duration of colostomy is associated with complications, prolonged duration of treatment as well as significant losses to follow up. A single-stage repair may expedite care and reduce the colostomy morbidity.

Introduction

Aganglionic megacolon (Hirschsprung's disease) is the total or partial absence of ganglion cells from whole segments of the colon (1). As a result the disease presents with features of functional intestinal obstruction (delayed passage of meconium, constipation, abdominal distension) and associated poor feeding and failure to thrive (2). Its prevalence among children ranges from 1 in 4400 to 1 in 7000 (1-3). Rectal biopsy is the gold standard for the diagnosis of HD (4). Treatment may involve preliminary decompression of the gut by enemas and leveling divided colostomies (5) or

upfront definitive surgery. With regard to surgical therapeutic options, Swenson and Bill have been credited for the first successful therapeutic approach (5). Other described operations include; Souave-Boley (6), Rehbein (7), State (8) and Duhamel (9). Irrespective of the method of therapy, treatment of HD is associated with many important complications. Data from African countries indicate disease presentation beyond the neonatal period in the majority of cases - an important cause of morbidity and mortality (10). Although some complications have been documented by previous studies at KNH (11,12), the total experience remains unpublished. We examined the KNH experience to document the management and outcomes of HD in its different phases of care.

Patients and Methods

After the KNH-ERC approval, we reviewed the medical records for all cases of HD for the period between January 2002 and December 2006. The following data were collected: patient demographics, clinical, procedural, pathologic, follow up and outcome. Categorical variables were compared using chi-square analysis while continuous data were compared using the Student t-test analysis. A p-value < 0.05 was considered significant.

Results

There were 117 patients with a clinical diagnosis of HD during the study period. We excluded from analysis five patients who had been referred to KNH after surgery in other centres.

Demographic characteristics: There were 17 (15%) females and 95 (85%) males (gender ratio 5.5: 1).

At presentation, 27.7% of the patients were younger than two weeks of age while the rest (82.3%) were older. The mean age of the group was 709 ± 400 days (range, one day to 17 years). The age at diagnosis was ≤30 days in 44 children

(39%), one month to one year in 26 (24%), and ≥ one year in 42 (37%).

Clinical characteristics: The main symptoms included repeated vomiting (48% of children), chronic constipation (90%), delayed passage of meconium (69%), abdominal distension (90%) and failure to thrive (29%). None of the patients had a positive family history of HD. Admission diagnoses before consultant inputs included HD (69%), rickets (1%), enterocolitis (2%), severe neonatal sepsis (3%), intestinal obstruction (20%), meconium plug syndrome (2.5%), neonatal small left colon (0.9%) and psychiatric disorders in the older patients (12 years and 17 years) (1.7%). Of the 112 patients, 28% had associated congenital malformations including anorectal (12%), trisomy 21 (5%), cardiac (2%), and a combination (2%) of Down's syndrome with cardiac, anterior abdominal wall defects, paraesophageal hernia, congenital cataract, phimosis, hydrocele and renal agenesis. Other (6%) anomalies recorded were: phimosis, hydrocele, ambiguous genitalia, renal agenesis and prune belly syndrome.

Pathology: Eighty nine patients underwent rectal biopsies (suction technique in 33 children and full thickness in 56 children) to confirm clinical suspicion. Microscopy revealed absent ganglion cells in the rectal mucosa and wall. The length of the lesions was unstated, ultra short, short or long in 49%, 1%, 26% and 24% respectively.

Management and Outcome: Five children died before histological confirmation of HD while eighteen others were lost to care before the phase of definitive diagnosis.

Of the 89 patients, 69 underwent colostomy creation after stabilization, three died before any intervention, two underwent single stage repair while 15 were lost to follow up. Only 54 of the patients with colostomies underwent definitive surgery (between one day and four years). The two procedures employed were Swenson (52) and Boley's (2) pull through. By the end of the study period, 28 patients had presented for colostomy reversals (interval of three months to 11 years)

while 19 were still awaiting reversals. While 112 patients initially presented to the hospital, only 30 patients were fully managed (Figure 1).

Thirty five percent of the patients developed colostomy complications. These included distal prolapse (11.6%), proximal prolapse (11.6%), colostomy obstruction (2.9%) and broken colostomy bridge (1.4%) (Table 1). Twelve colostomies were reversed within one year of creation, while 16 were closed after one year. The rate of complications were similar for divided transverse and divided sigmoid colostomies, p-value 0.609. The rate of complications was significantly higher for those whose duration before reversal was longer than one year (17% versus 69%, p-value 0.02). The total duration of hospitalization incorporating all admission episodes was also longer (41+15 days and 76+ 20 days, p = 0.02) for patients whose colostomies were reversed after one year. For patients whose management had been completed by the close of this study, the duration to completion of care for patients with colostomy duration > one year was

366+ 156 days while that for colostomy duration > one year was 1001 + 942 days respectively, p=0.012.

The documented complications related to definitive surgery included hemorrhage (11.1%), infections (48%), obstruction (24%), intestinal leaks (3.7%), burst abdomen (3.7%), failed pull through (5.6%) and mortality (12.9%) (Table 2).

Overall, 16 children (14.3%) died (five with a clinical impression of HD, three with pathologic diagnosis while awaiting colostomy, one with colostomy while awaiting definitive surgery, and seven within 1-2 days of definitive pull through (Figure 1).

Table 1: Complications related to colostomies (n 69)

Complications	Number	%
Distal prolapse	8	11.6
Proximal prolapse	8	11.6
Colostomy obstruction	2	2.9
Colostomy stenosis	5	7.2
Broken colostomy bridge	1	1.4
None	45	65.3

Figure 1: A flow chart showing the handling of patients with a clinical impression of hirschsprungs disease

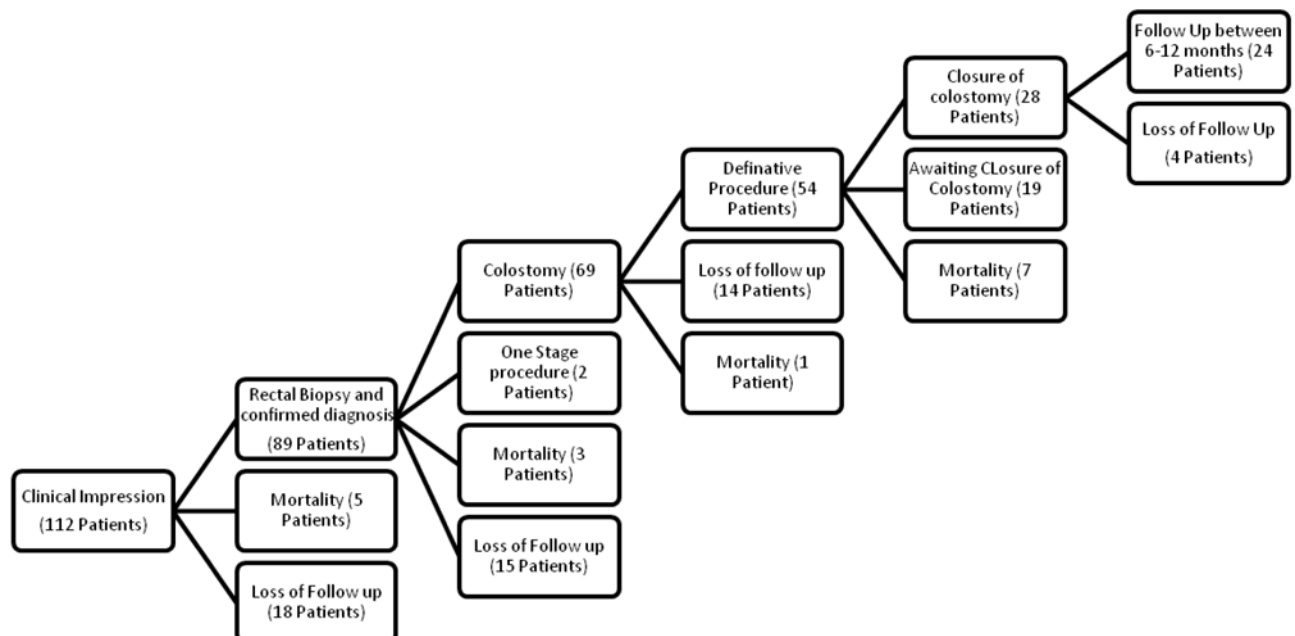


Table 2: Complications related to definitive surgery (n 54)

Complications	Number	%
Infection	26	48
Obstruction	13	24
Intestinal leak	2	3.7
Hemorrhage	6	11.1
Burst abdomen	2	3.7
Stenosed anastomosis	2	3.7
Rectourinary fistula	1	1.8
Broken/failed pull through	3	5.6
Colon perforation	1	1.8
Mortality	7	12.9
Nil	19	35.2

Discussion

KNH is the main paediatric surgical facility in Kenya. The population described in this study is unique in several respects. The gender ratio of 5.5:1 in favour of males is higher than the widely quoted ratio of 4:1 (4). Thirty nine percent of the patients in this study were diagnosed in the neonatal period. This contrasts western literature where up to 90% (13) are treated in the neonatal period but similar to other experience from Africa (10). Further, a few patients in this study presented in their teenage years.

The symptoms of delayed passage of meconium, vomiting, constipation, abdominal distention and failure to thrive, while useful for a presumptive diagnosis of HD, can be non-specific as demonstrated in our study population. In this study, 39% patients were admitted for diagnoses other than HD. Although delayed passage of meconium has been described to be presumptive of HD in newborns (4), using this symptom alone may miss 31% of the cases in our setting. Other accounts indicate that 6-42% of patients with HD may not present with delayed passage of meconium in the neonatal life (14). A high index of suspicion is necessary to investigate early for HD.

The rectal biopsy remains the main diagnostic tool in HD, with a diagnostic accuracy of 99.7% (15). All the clinical impressions of HD were confirmed on rectal biopsy. Most children did

not have an indication of the length of segment involved. The potential for exploring the prognostic value of this pathologic variable was therefore not pursued in this study. In the study by Chirda and Uba (10), all patients with total aganglionosis died.

Only two patients underwent the single stage option in this study. In paediatric surgical practice in recent decades, increasing numbers of surgeons are abandoning the routine use of colostomies in favour of one-stage pull through, with multiple studies suggesting that this approach is safe and efficacious (2,13,16,17). The staged repairs in this study were probably informed by the late presentation of the children who needed resuscitation and stabilization. In such a setting, preliminary colostomies would seem justified. However, it is also probable that the choice for colostomy was guided by established practice rather than the safety data. In a recent study from Nigeria, Chirdan and Uba reported that none of their 31 patients presenting in the neonatal period had primary pull-through carried out (10).

We have recorded a high rate of colostomy complications especially for those whose colostomy reversals were beyond the first year of creation. This latter group had more readmission episodes, longer lengths of hospital stays, higher loss to follow up rates and an average time to completion of care of 1000 days. One-stage pull-through may limit the effects of colostomy creation we have documented in this study. In any case, an argument for earlier closure for those who must have colostomies created has been generated.

Although the spectrum and rate of post-pull through complications observed in our patients (haemorrhage 11.1%, obstruction 24%, intestinal leaks 3.7%) are similar to previous reports (5,1,19), sepsis and mortality rates were higher. In the original Swenson operation, mortality ranged from 1.25 to 2.5% (4). The mortality rate in this study is similar to the data by Mwanthi (11), two decades earlier. The determinants of this high mortality need to be prospectively evaluated.

While 112 patients were recruited, only 30 patients were completely managed. Losses of patients to follow up are a major challenge in our

environment. There are many reasons for this – inappropriate health-seeking behaviours, long durations of care, multiple phases, long travelling distances and financial constraints. This was a retrospective study. The missing data could also have been occasioned by poor record keeping and retrieval. Altogether, the goal of management should be to have all the patients complete the course of treatment of HD.

In conclusion, the presentation of Hirschsprung's disease is late. The colostomy morbidity is high especially for patients with long periods before reversal. The mortality associated with HD at KNH is higher than in literature. One stage pull-through for stable neonates/infants and prospective evaluation of the causes of high mortality are recommended.

Acknowledgements

We would like to thank Miss Anne Pulei and Dr. Lesan, for their critical comments and advice.

References

1. Soave F. Hirschsprung's disease: A new surgical technique. *Arch. Dis. Child.* 1964; **39**: 116-124.
2. Pierro A., Fasoli L. and Kiely E.M. Staged pull-through for rectosigmoid Hirschsprung's disease is not safer than primary pull-through. *J. Pediatr. Surg.* 1997; **32**: 505-509.
3. Spounge D. and Baird P. Hirschsprung's Disease in a large birth cohort. *Tetralogy.* 1985; **32**: 171-177.
4. Grosfeld J.L., O'Neill J.A., Fonkalsrud E.W. *et al.* Paediatric Surgery. 6th Ed, Philadelphia Mosby Elsevier. 2006; (2) 1514-1559.
5. Swenson O. and Bill A.H. Resection of the rectum and rectosigmoid with preservation of the sphincter for benign spastic lesions producing megacolon. *Surgery.* 1948; **24**: 212-220.
6. Boley S. An endorectal pull through operation with primary anastomosis for Hirschsprung's disease. *Surg. Gynaecol. Obstet.* 1968; **127**: 353-357.
7. Rehbein F. and Von Zimmermann H. Results with abdominal resection in Hirschsprung's disease. *Arch. Dis. Child.* 1960; **35**: 29-37.
8. State D. Segmental colon resection in the treatment of congenital megacolon. *Amer. J. Surg.* 1963; **105**: 93-101.
9. Duhamel B. A new operation for the treatment of Hirschsprung's disease. *Arch. Dis. Child.* 1960; **35**: 38-39.
10. Chirdan L.B. and UBA A.F. Hirschsprung's disease presenting in the neonatal period in Jos, Nigeria. *Nig. J. Surg. Res.* 2006; **8**: 62-64.
11. Mwanthi C.G.K. Hirschsprung's disease and other allied diseases at KNH during the last 5 years (1973-1978). MMed (Surg.) dissertation of the University of Nairobi. 1978.
12. Kuria F.N. Postsurgical complications of HD and their management a ten year perspective (1991 - 2000). MMed (Surg.) dissertation of the University of Nairobi. 2003.
13. Langer J.C., Durrant A.C., Torre L.D., *et al.* One-stage transanal Soave pull-through for Hirschsprung's disease: A multicentre experience with 141 children. *Ann. Surg.* 2003; **238**(4): 569-576.
14. Swenson O., Sherman J. and Fisher L. Diagnosis of Congenital megacolon: An analysis of 501 patients. *J. Pediatr. Surg.* 1973; **8**: 587-594.
15. Kessmann J. Hirschsprung's Disease: Diagnosis and Management. *Amer. Fam. Physician.* 2006; **74**: 1319-1322, 1327-1328.
16. Langer J.C., Fitzgerald P.G. and Winthrop A.L. One vs. two stage Soave pull-through for Hirschsprung's disease in the first year of life. *J. Pediatr. Surg.* 1996; **31**: 33-37.
17. Teitelbaum D.H., Cilley R.E. and Sherman N.J. A decade of experience with the primary pull-through for Hirschsprung disease in the newborn period: a multicentre analysis of outcomes. *Ann. Surg.* 2000; **232**: 372-380.
18. Sherman J.O., Snyder M.E. and Weitzman J.J. A 4-year multinational retrospective study of 880 Swenson procedures. *J. Pediatr. Surg.* 1989; **24**: 833-838.
19. Archibong A.E. Pattern of aganglionic megacolon in Calabar, Nigeria. *S. Afr. Med. J.* 2002; **92**: 642-644.