

# Surgery for ureteral complications of bilharziasis

**G. A. Maranya**, MBChB, MMed (Surg.), Cert. Urol. (E.A.), FCS(ECSA), **A.Y. Al-Ammary**, MBChB, MMed (Surg.) Cert. Urol. (E.A.) FCS(ECSA) and **P. R. Oduor**, MBChB, MMed (Surg.), FCS(ECSA), Coast Province General Hospital

Corresponding author: **G. A. Maranya**, Coast Province General Hospital, P.O. Box 91066-80103, Mombasa, Kenya, Email: maranya@wananchi.com

## Abstract

**OBJECTIVE:** To review our experience with reconstructions of ureteral complications of *Schistosoma haematobium*, in a centre situated in an endemic zone.

**PATIENTS:** Fifty one patients operated for bilharzial complications of the ureters.

**METHODS:** A retrospective analysis of patients operated upon, at the Coast Province General Hospital, Mombasa, Kenya between 1996 and 2008. All patients had obstructive ureteral complications. Data abstracted included demographics, level and nature of complication, surgical options utilized and follow-up.

**RESULTS:** Endoscopic visual internal ureterotomy (VIU) was performed in 21 (41%) patients, resection and ureteroneocystostomy in 27 (49% of 55 procedures done), resection and ureteroureterostomy in one, nephrectomy in two and ileal replacements in two. Nephrostomy was performed in two patients who presented with anuria. Two patients restenosed after VIU and were offered resection and ureteroneocystostomy. One patient restenosed after ureteroneocystostomy and underwent a revision with psoas hitch. One patient with nephrostomy had bilateral ureteric replacement with ileum to skin. The two patients with anuria who had nephrostomy done eventually died of progressive renal failure.

**CONCLUSION:** *Schistosoma haematobium* is associated with severe complications of the

upper urinary tracts. Once established these complications are amenable to surgical correction, by both open and endoscopic techniques as long as renal function is not irretrievably impaired.

## Introduction

The trematode *Schistosoma haematobium* is transmitted to man by contact with contaminated water (Figure 1).

The adult worms reside in the vesical and pelvic venous plexuses where the female lays eggs.

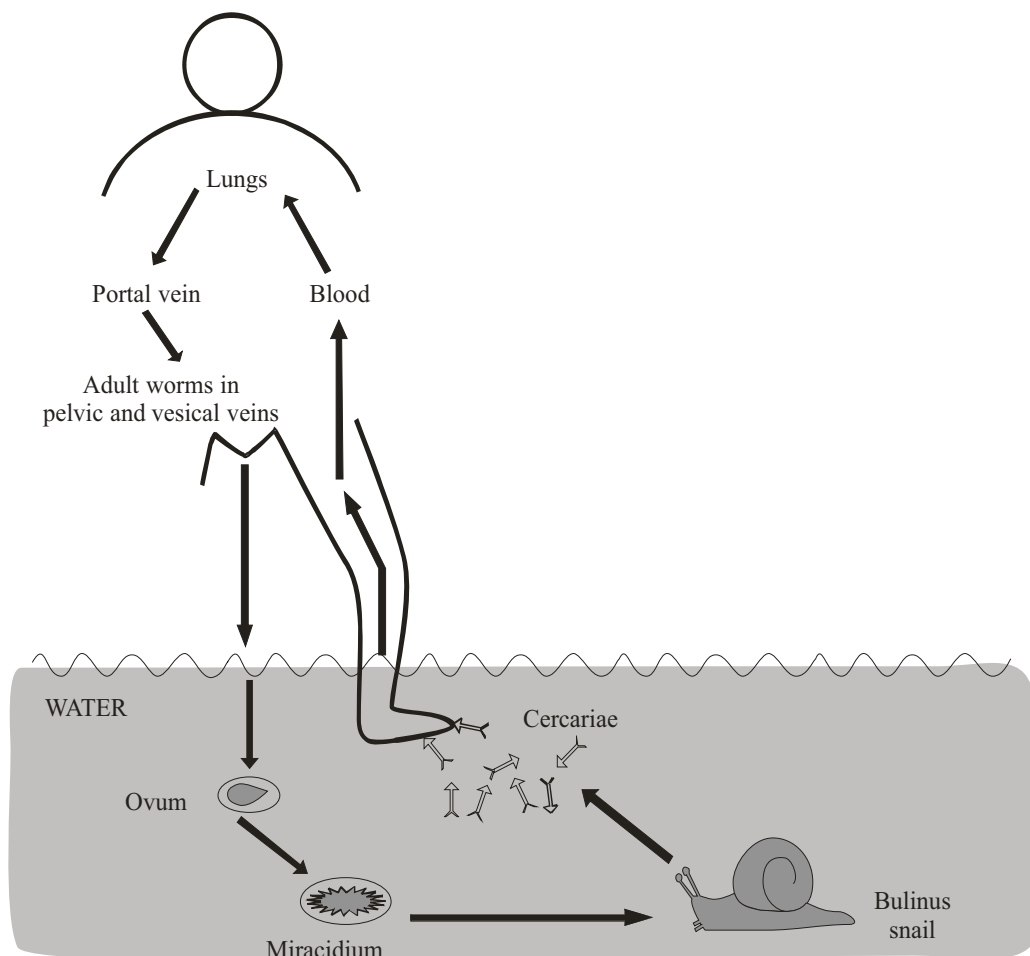
The urinary bladder, distal ureters and seminal vesicles are most commonly affected, due to their rich venous supply (1).

The pathological effects of *Schistosoma haematobium* infestation in man are mainly the result of an intense host reaction to the eggs which secrete a histiolytic antigen that evokes a cell mediated immune response, culminating in formation of granulomatous lesions (1). There is an association between egg burden and histological severity of tissue reaction (2,3).

Eggs may be found in all layers of the distal ureters; with resultant mural fibrosis, leading to loss of muscle and development of periureteral adhesions. Ureteric obstruction occurs; being caused by stricture formation and/or hypotonia with dilatation of the involved segment. Urinary stasis and secondary bacterial infection predispose to calculi formation (1).

After assessment, the treatment options of the ureteric complications are endoscopic and open surgery (1).

**Figure 1. The life cycle of *Schistosoma haematobium***



This report documents the surgical experience with ureteral complications of *Schistosoma haematobium* and describes the outcomes of the interventions employed.

## **Patients and methods**

This retrospective study was conducted at the Coast Province General Hospital, Mombasa Kenya. This institution is the referral centre of the Coast Province where bilharzia is endemic. Included were patients with upper urinary tract complications of schistosomiasis treated surgically between 1996 and 2008.

Diagnosis was made through a combination of history (flank pains, lower abdominal pain and dysuria), clinical examination, blood

investigations, abdominopelvic ultrasonography, excretory urography and urethrocytostomy. Data was collected on patient age, gender, nature and level of complication, operative technique and complications following surgical treatment. Operative techniques utilized are illustrated in Figure 2. Patients were followed for complications necessitating repeat surgery.

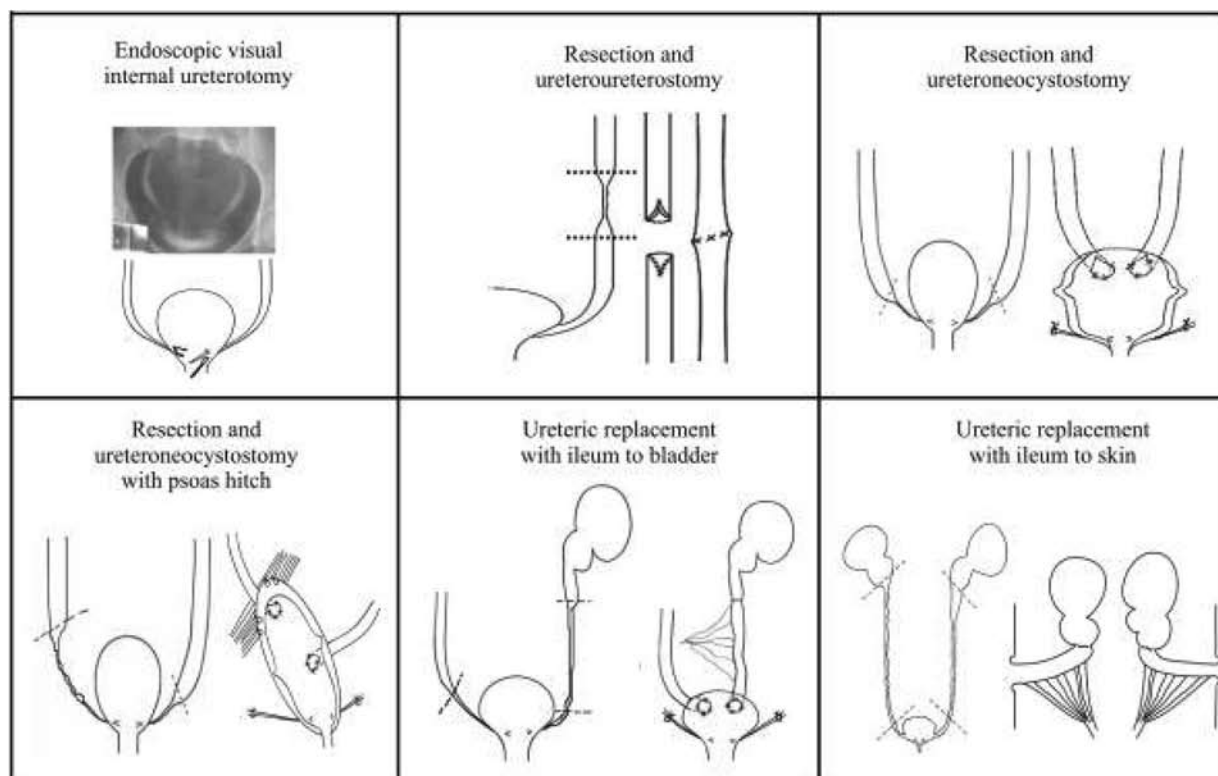
## **Results**

Patient ages ranged from 13 to 60 years (mean age 36 years). Majority (65.3%) were male (gender ratio 2:1). Operative treatment options were endoscopic and open surgery (Figure 2). Endoscopic VIU was used in 19 patients; ten being bilateral (Table 1).

**Table 1. Operations done on 51 patients with upper urinary tract bilharzial complications (1996 to 2008)**

Patients' profile	Procedures done	Number	Side	Psoas hitch
Age range/years: 13-60	Endoscopic ureteral meatotomy	21	Unilateral 9	
			Bilateral 12	
Mean age/years: 36	Ureteroneocystostomy	27	Unilateral 15	2
			Bilateral 12	3
Gender: Male: 34 Female: 17	Resection and ureteroureterostomy	1		
	Ureteric replacement with ileum	2	Unilateral to bladder 1	
			Bilateral to skin 1	
Gender ratio: Male : Female 2 : 1	Nephrostomy	2		
	Nephrectomy	2		
Total number: 51	Total number of procedures: 55			

**Figure 2. Some of the operations done for upper urinary tract schistosomiasis.**



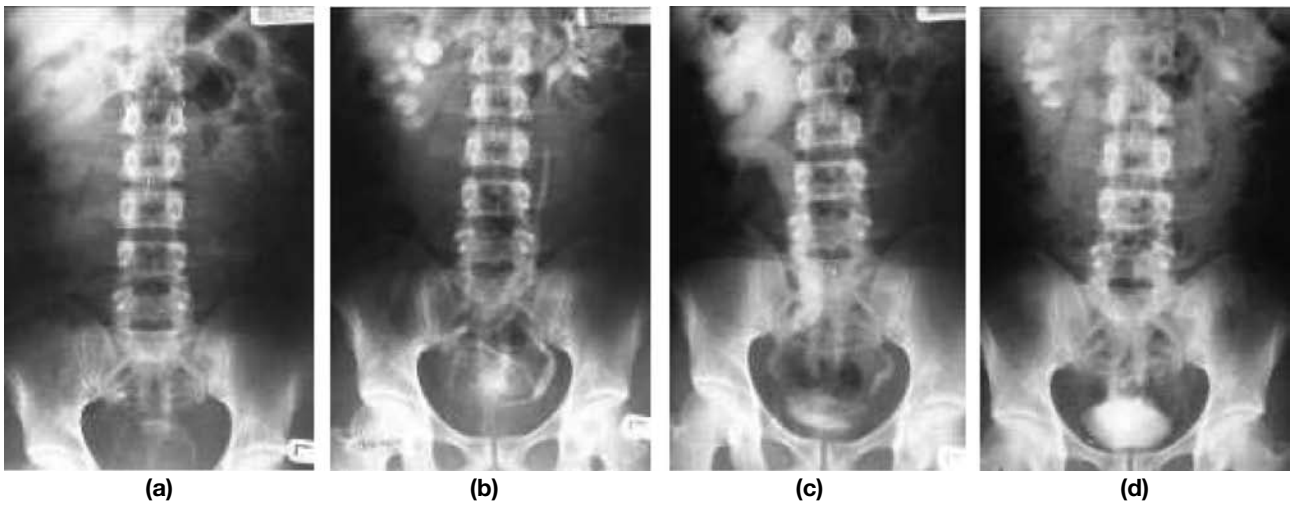
Resection and ureteroureterostomy was performed in one patient with a short segment stricture. A double J stent was left in place. Ureteroneocystostomy, where the ureters were reimplanted flush to the dome of the bladder to minimise restenosis, was the procedure of choice for strictures of the lower ends of the ureters. This was done in 26 patients; 12 being bilateral. In four patients with moderate length distal ureteric strictures, ureteroneocystostomy with psoas hitch was performed (Figure 3).

Ureteric replacement with ileum was performed in two patients. These were patients whose strictures were long and multiple.

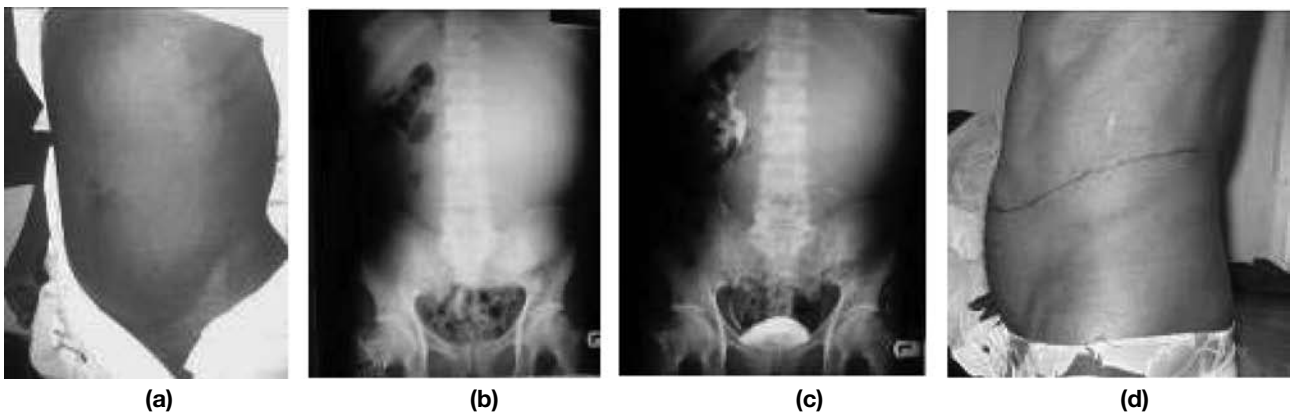
In this series nephrostomy was performed in two patients with anuria while nephrectomy was done for gross ureterohydronephrosis in two patients with total loss of the ipsilateral renal function (Figure 4, Table 1).

On post-operative follow-up, two patients who had unilateral visual internal ureterotomies had restenoses requiring ureteroneocystostomies. One

**Figure 3. Excretory urogram of a 36 year old man before and after bilateral ureteroneocystostomy with right psoas hitch. (a) Plain film. Note the secondary right distal ureteric calculus and bladder calcification. (b) Contrast. Early film. (c) Late film. (d) Post operative contrast film 1 year later. There is prompt excretion and drainage of the ureters.**



**Figure 4. A 45 year old man with massive left hydronephrosis. (a) Presentation as a huge abdominal mass. (b) Excretory urography; plain film. (c) Contrast film. (d) Post operatively after nephrectomy**



patient with gross bilateral ureterohydronephrosis and non-function of one side had ureteroneocystostomy, but presented five years later with anuria necessitating haemodialysis. He had revision of the ureteroneocystostomy with psoas hitch.

The two patients who had nephrostomies had presented with anuria and gross bilateral ureterohydronephrosis. One had progressive renal failure and died as dialysis was not available. The other had bilateral ileal replacement of the ureters to skin as the bladder was markedly contracted; with a view to later augmentation cystoplasty. She developed progressive renal failure over several weeks and died as dialysis was then not available

and the prospects of renal transplant non-existent.

## **Discussion**

The changes in the ureter that necessitated the surgical interventions were an indication of the severity of infestation with *Schistosoma haematobium*, implying a higher egg burden and consequently more intense inflammatory reaction (2).

The proportion of patients in the current series who underwent endoscopic visual internal ureterotomy (41%) compares well with the series

by Ghoneim (1,4), where the procedure was successful in 40%. We found the procedure useful for early, short segment strictures.

The other patients underwent open ureteric surgery. A prime consideration during these procedures is the preservation of the ureteric blood supply by mobilising it with its sheath to prevent stenosis or stricturing at the site of reconstruction (5).

In the patient where resection and ureteroureterostomy was done, the stricture was short and a double J stent was inserted considering the fibrosis that may be associated with impaired blood supply in bilharziasis (6). Otherwise a stent is not usually required for ureteroureterostomy in a normal ureter.

Ureteroneocystostomy was the most commonly performed procedure at 49% with 19% having a psoas hitch done. This differs with Mee (7) where this was performed in 85% of patients in his small series. In both series the re-implantation was flush to the dome of the bladder after excising a wide, full thickness core, in contrast to standard tunnelling. This minimises restricturing as fibrosis may progress. Because the ureters are hypotonic, this also aids drainage by gravity (7,8).

Nephrostomy was offered to two patients who presented with anuria. One died of renal failure before further surgery. The other died after bilateral ileal substitution to skin; also due to progressive renal failure. In our experience, patients who present with anuria have a poor prognosis; due to severe renal damage.

Ileal replacement was performed in two patients with very long strictures; one unilateral to bladder with contralateral ureteroneocystostomy and the other bilateral to skin as the bladder was severely contracted. Substitution with ileum is the best option in such scenarios (9,10). The latter patient died from progressive renal failure. In patients with impaired or borderline renal function, progressive deterioration does occur after ileal replacement (10).

Nephrectomy, done in two patients with gross symptomatic hydronephrosis with total loss of renal function, was inevitable (1).

In conclusion, *Schistosoma hematobium* is

associated with severe complications of the urinary tract. Once established, the effects on the upper urinary tracts are amenable to surgical correction; both open and endoscopic, if renal function is not irretrievably impaired.

## Acknowledgements

We are sincerely grateful to J. Mwawana for the computer work, Dr M. N. Noorani for the drawings, F. N. Karanja of GlaxoSmithKline for references and the Chief Administrator of Coast Province General Hospital, Mombasa, Kenya for authority to publish this work.

## References

1. Ghoneim M.A. Bilharziasis of the genitourinary tract. *BJU Int.* 2002; **89**: 22-30.
2. Smith J.H. and Christie J.D. The pathobiology of schistosoma haematobium in humans. *Hum. Pathol.* 1986; **17**: 333-345.
3. Smith J.H., Kamel I.A., Elwi A. *et al.* A quantitative postmortem analysis of urinary schistosomiasis in Egypt. *Amer. J. Trop. Med. Hyg.* 1974; **23**: 1054-1071.
4. Ghoneim M.A., Nabeeh A. and El Kapany A. Endourologic treatment of ureteral strictures. *J. Endourol.* 1988; **2**: 263-270.
5. Frober R. Surgical anatomy of the ureters. *BJU Int.* 2007; **100**: 949-965.
6. Stief C.G., Jonas U., Petry K.U. *et al.* Ureteric reconstruction. *BJU Int.* 2003; **91**: 138-142.
7. Mee D.D. and Youssef A.M. The management of bilharzial strictures of the ureters. *Br.J. Urol.* 1982; **54**: 103-105.
8. Eshleman J.L. Helminthic infections of the urinary tract; Schistosomiasis. In: *A textbook of urology and nephrology in Africa.* Eshleman J.L. (Ed). Eshleman J.L. (Publisher). 1999:163-172.
9. Ghoneim M.A. and Shoukry I. The use of ileum for correction of advanced or complicated bilharzial lesions of the urinary tract. *Intern. Urol. and Nephrol.* 1972; **4**: 25-33.
10. Bonfig R., Gerharz E.W. and Riedmiller H. Ileal ureteric replacement in complex reconstruction of the urinary tract. *BJU Int.* 2004; **93**: 575-580.