

A Case Report and Technique Guide for Stabilization of Tibialis Posterior Tendon Dislocation in an Athlete

Hussein Ibrahim Hussein¹  and Mordicai Atinga² 

¹University of Nairobi

²Aga Khan University Hospital

Correspondence to: Dr. Hussein Ibrahim Hussein; email: hussein28652009@gmail.com

Received: 25 Oct 2022; Revised: 15 Mar 2023; Accepted: 21 Mar 2023; Available online: 1 Apr 2023

Summary

Acute dislocation of the posterior tibial tendon is an infrequent injury that is often missed. This injury is typically observed in young individuals in the course of sports. This is a case of an athlete who presented to our orthopedic clinic a week after injury to his ankle, following forceful eversion of the foot during a football game. Case reports have shown satisfactory results from surgical management, suggesting that this is the preferred treatment option. The report describes a simple and cost-effective technique for the retinaculum repair as well as adding to the small number of case reports on the description and treatment of tibialis posterior tendon dislocation.

Keywords: Tibialis posterior dislocation, Case report, Technique, Athlete

Ann Afr Surg. 2023; 20(3): 94-98

DOI: <http://dx.doi.org/10.4314/aas.v20i3.4>

Conflict of interest: None

Funding: None

© 2023 Author. This work is licensed under the Creative Commons Attribution 4.0 International License.

Introduction

Acute dislocation of the posterior tibial tendon is described as a rare injury that is frequently missed (1). This injury is typically observed in young individuals in the course of sports (2). The treatment options are varied in the literature, given the rare nature of the injury and the absence of large patient series.

Anatomically, the position of the tibialis posterior tendon behind the medial malleolus is maintained by two main constraints: the depth of the retromalleolar groove and the integrity of the posterior retinaculum. Injury results in damage to the retinaculum which may tear, avulse off the medial malleolus, or elevate off the medial malleolus, allowing it to be undermined by the dislocating tibialis posterior tendon (3).

The injury has been described as being due to a forceful twisting of the ankle in an everted position. There is normally medial side pain, which may be accompanied by feeling the cord-like tibialis posterior tendon over the medial malleolus (3).

Delayed diagnosis leads to persistent medial ankle pain, tendon instability, and possible tendon tears. Furthermore, there may be attenuation of the retinaculum, making it harder to perform delayed repair. Late diagnosis has been associated with delayed recovery and return to sporting activities (4). The case reports on tibialis posterior dislocation have shown satisfactory results from surgical management, suggesting that this is the preferred treatment option (5). Such surgical management options include direct flexor

retinaculum reparation, bone grafting, retinaculum restoration with grooved-deepening techniques, malleolar osteotomies suture anchor, and buttress plate fixation (6). This report describes a simple and cost-effective technique for the retinaculum repair and adds to the small number of case reports on the description and treatment of tibialis posterior tendon dislocation.

Case presentation

The athlete presented to the orthopedic clinic 1 week after having injured his ankle during a football game. He was kicked on the lateral aspect of the ankle, forcibly everting the foot. He had immediate pain with swelling and was unable to continue playing. He described feeling a cord-like structure moving over his medial malleolus with associated pain. He had not suffered any prior injuries and was otherwise extremely fit and active. The radiographs taken at his initial assessment were unremarkable. He was initially diagnosed as having an ankle sprain and had been discharged to physiotherapy before seeking further attention.

On examination, he had an antalgic gait pattern with bruising over the medial malleolus. His tibialis posterior tendon was clinically dislocated and lying over the medial malleolus. The tendon could be reduced manually; however, the default position was over the medial malleolus. From the history of trauma and the clinical presentation, the diagnosis of tibialis posterior tendon dislocation was made and no further imaging or investigation was sought. The patient was offered a surgical option for reduction of the tendon and repair of the retinaculum.

Surgical technique

The procedure was performed under general anesthesia with a tourniquet used throughout. The patient was positioned in the left lateral position exposing the left medial malleolus. A curved incision was made posterior to the malleolus in line with the tibialis posterior tendon. Dissection was performed to the deep fascia to expose the retinaculum and malleolus. He had a type 2 dislocation with the retinaculum intact superficially (Figure A).

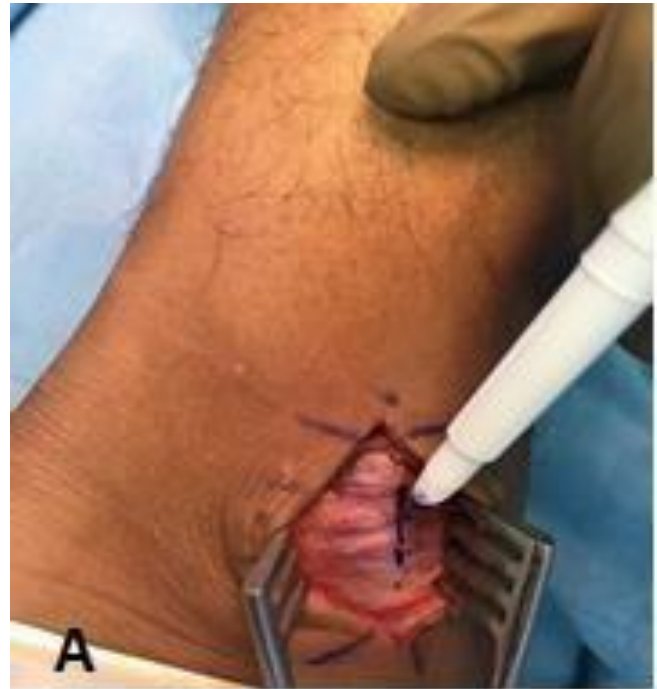

Figure A. Retinaculum intact superficially.

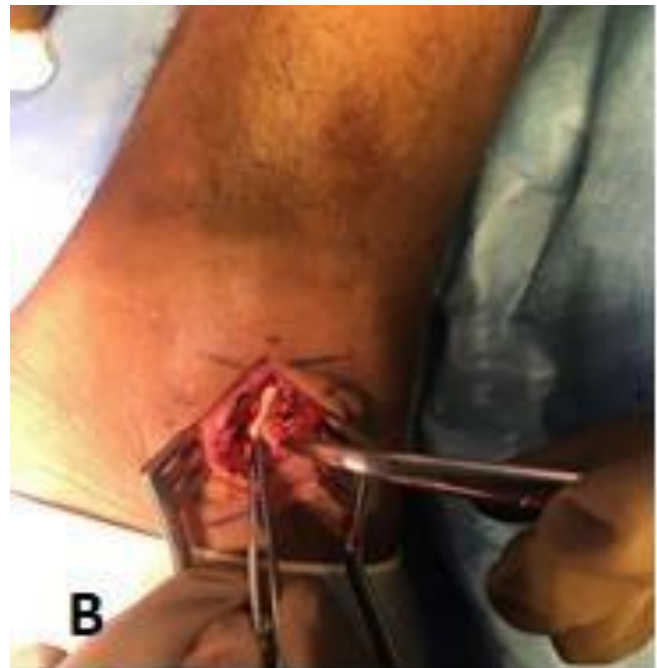


Figure B. Tendon relocated.

The deep retinaculum fibers were detached from the medial malleolus along with the periosteum, with the tendon anteriorly dislocated. The retinaculum was divided in line with the posterior border of the malleolus, exposing the dislocated tibialis posterior tendon. The

tendon was easily reduced into its groove behind the medial malleolus (Figure B). The retinaculum footprint on the posterior aspect of the medial malleolus was prepared with a curette to create a raw surface suitable for healing (Figure C).

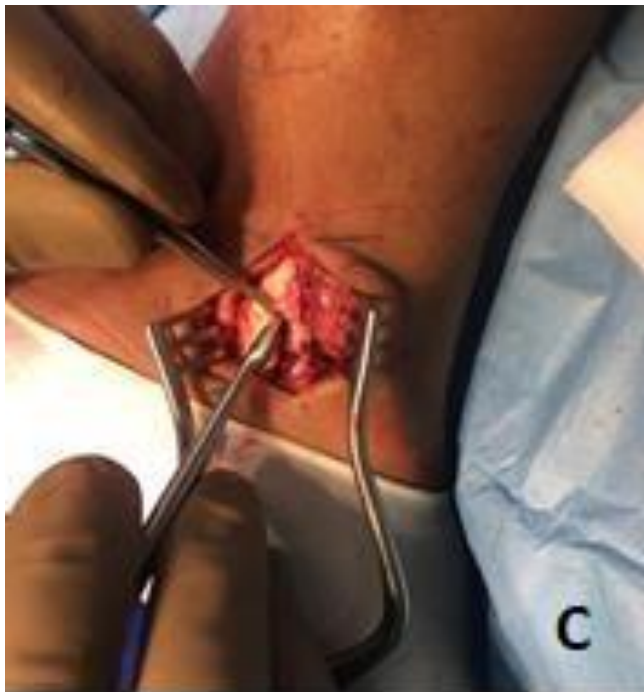

Figure C. Preparing retinaculum footprint.

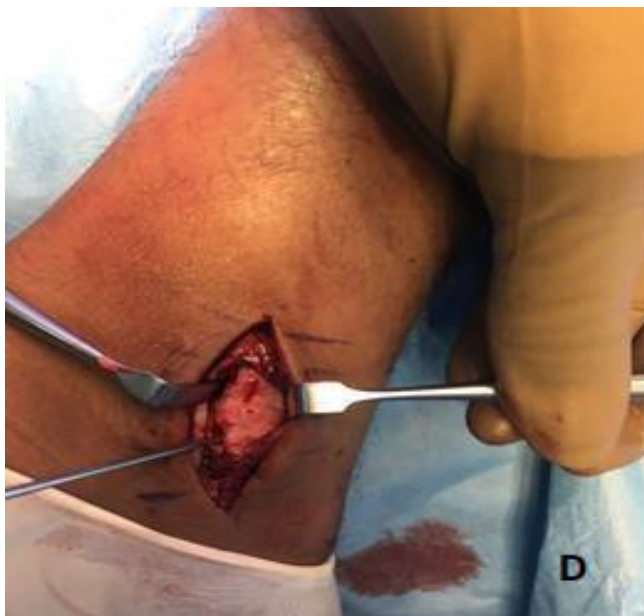

Figure D. Drill holes made in the malleolus from posterior to anterior in the sagittal plane.

Two 2-mm drill holes were made into the posterior surface of the malleolus from posterior to anterior in the sagittal plane, taking care to avoid accidental intra-articular intrusion (Figure D).

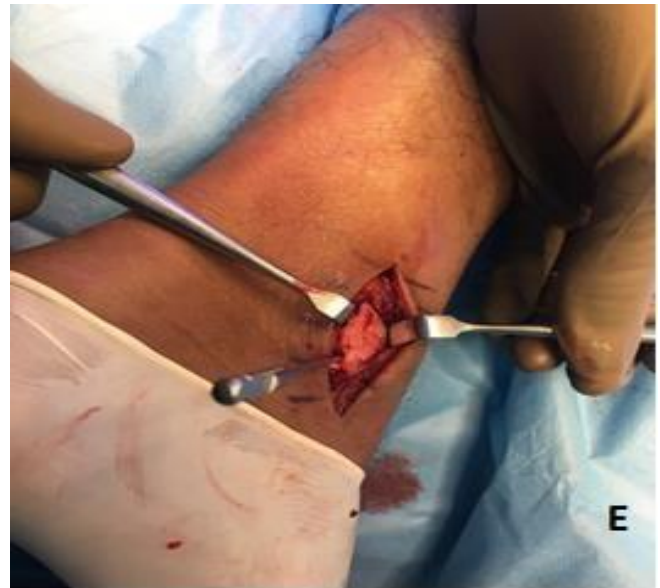

Figure E. Drill bits in situ.

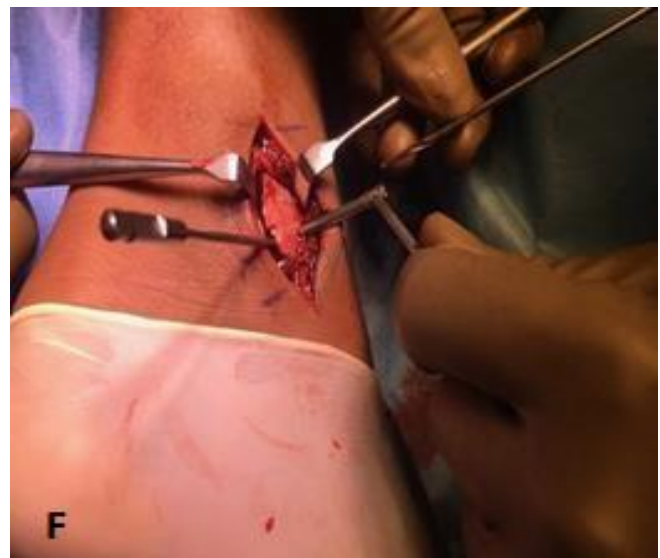

Figure F. Drill holes made in the malleolus from medial to lateral in the coronal plane.

These tunnels were 1-cm apart to create a bone bridge. Leaving a drill bit in each tunnel (Figure E), a connecting drill hole was made from the medial malleolar surface in a medial to lateral direction, aiming for the drill bit in situ (Figure F). The drill bit left in the

in situ protected from accidental joint intrusion and ensured the tunnels to be connected. Two Ethibond sutures, 1-cm apart, were locked into the retinaculum. These sutures were then shuttled through the two bone tunnels from posterior and exiting medially (Figure G).

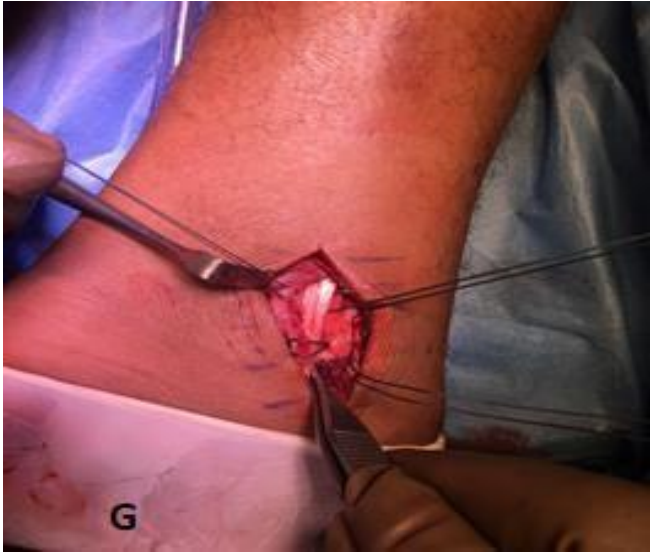

Figure G. Two Ethibond sutures, 1-cm apart, were locked into the retinaculum and shuttled through the tunnel.

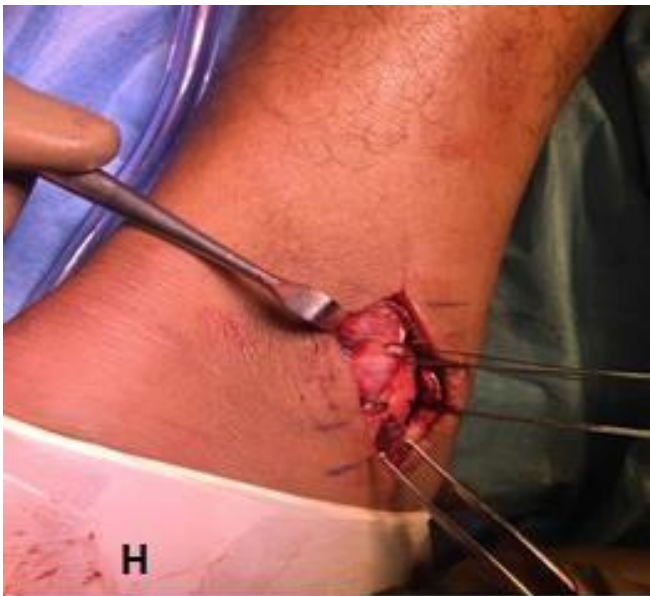


Figure H. Sutures pulled through the tunnels reproducing the retinaculum attachment to the medial malleolus and tied onto the medial surface of the malleolus over a bone bridge.

Ethibond suture was used for the shuttling. The tendon was reduced into the retromalleolar groove before the

retinaculum was advanced to the prepared footprint using the sutures. The sutures were pulled through the tunnels reproducing the retinaculum attachment to the medial malleolus. The two sets of sutures were then tied onto the medial surface of the malleolus over a bone bridge (Figure H). The ankle was put through a range of motion confirming that the tendon was able to glide unrestricted. The anterior leaf of the retinaculum was then repaired and the wound closed in layers. The patient was placed into a mild equines position plaster, which reduced the tension from the tibialis posterior tendon on the repair.

Post-operative care

The patient was reviewed at 2 weeks, when the wound healing was confirmed and the posterior tibial tendon was noted to be behind the medial malleolus. He was immobilized for a further 3 weeks and started walking at 5 weeks post-surgery. At 6 weeks, he commenced physiotherapy to strengthen his calf muscles and improve proprioception. He completed 6 weeks of rehabilitation before returning to football at 3 months.

Discussion

Tibialis posterior tendon dislocation is a relatively rare injury and has frequently been missed. The available case reports show that surgical management yields good to excellent results and appears to be the preferred treatment. Understanding the types of dislocation is useful, as it may help determine the best surgical treatment. In the classification by Strydom et al., they view the retinaculum as being avulsed, torn, or attenuated as a result of delayed diagnosis. The modifier in the Strydom classification of surgical management is inclusion of a groove-deepening procedure if the groove is deemed to be shallow (7).

Various management options have been described, including direct repair of the retinaculum, and suture anchor and drill hole techniques. This report describes a drill hole technique that is reproducible and cost-effective while achieving good results.

In reviewing the case reports on the surgical management of these injuries, some surgeons used

groove-deepening techniques when the retromalleolar groove was deemed shallow (6). A groove-deepening procedure was not performed as the tendon appeared stable intra-operatively. At present, this is a judgment made by the surgeon intra-operatively as there is no objective assessment of retromalleolar groove depth.

Review of the rehabilitation protocols showed great variability in immobilization and subsequent rehabilitation following surgery (4, 8, 9). Given that almost all patients performed well with variable protocols, it suggests that surgery was the most important factor and early mobilization is acceptable. The ankle joint was immobilized for 5 weeks before starting walking and progressing on to strengthening and proprioception exercises.

Much as the awareness among orthopedic surgeons is increasing, this report highlights both the ease of missing and making the diagnosis in the emergency unit. It is important to maintain a high index of suspicion when viewing patients with ankle sprains.

Conclusion

This case demonstrates a simple and cost-effective technique in dealing with these injuries once the diagnosis is made.

Ethical consideration

Informed consent was acquired from the patient for publication of the case report.

Author contributions

AM led in the conceptualization, methodology, supervision and validation while HH contributed to data curation, formal analysis, project administration and, reviewing and editing the original draft.

References

1. Alamri WM, Aljeaan R, Almulhim AK, et al. Traumatic dislocation of tibialis posterior tendon: a case report and literature review. *Cureus*. 2020; 12: e10885.
2. Teixeira da Mota P, Sapage R, Branco C, et al. Tibialis posterior tendon dislocation. *JBJS Case Connect*. 2020; 10: e1900590.
3. Soler R, Castany G, Ferret R, et al. Traumatic dislocation of the tibialis posterior tendon at the ankle level. *J Trauma*. 1986; 26: 1049–52.

4. Sakakibara Y, Kura H, Teramoto A, et al. Early surgical management of traumatic dislocation of the tibialis posterior tendon: a case report and review of the literature. *J Med Case Rep*. 2018; 12: 348.
5. Stefania Z, Carlo B, Domenico A, et al. Posterior tibial tendon dislocation: a case report. *J Foot Ankle Surg*. 2022; 61: 417–20.
6. Gkoudina A, Graikos G, Chatziargiriou M, et al. Posterior tibialis tendon dislocation: case report and review of literature. *Cureus*. 2021; 13: e19301.
7. Strydom A, Saragas NP, Tladi M, et al. Tibialis posterior tendon dislocation: a review and suggested classification. *J Foot Ankle Surg*. 2017; 56: 656–65.
8. Lee K, Byun W, Ha J, et al. Dislocation of the tibialis posterior tendon treated with autogenous bone block: a case report. *Foot Ankle Int*. 2010; 31: 254–7.
9. Rolf C, Guntner P, Ekenman I, et al. Dislocation of the tibialis posterior tendon: diagnosis and treatment. *J Foot Ankle Surg*. 1997; 36: 63–5.