










# Intraoperative Diagnosis of Gallbladder Agenesis: A Case Report

Abdullahi Ibrahim<sup>1,2</sup> , Mutisya Cosmas<sup>2</sup> , Ngugi Moses<sup>1</sup> , Osiemo Deborah<sup>3</sup> , Gumbe Ester<sup>3</sup> , Kiptoon Dar<sup>2</sup> , Hungu Eric<sup>1</sup> , Dahir Mohamed<sup>2</sup> , Ojuka Daniel<sup>2</sup> 

<sup>1</sup>Department of Surgery, Kenyatta National Hospital, Nairobi, Kenya

<sup>2</sup>Department of Surgery, Faculty of Health Sciences, The University of Nairobi, Kenya

<sup>3</sup>Department of Diagnostic Imaging and Radiation Medicine, Faculty of Health Sciences, The University of Nairobi, Kenya

**Correspondence to:** Abdullahi Ibrahim; email: [abdullahi552@gmail.com](mailto:abdullahi552@gmail.com)

Received: 21 Jan 2022; Revised: 1 Dec 2022; Accepted: 3 Dec 2022; Available online: 17 Dec 2022

## Summary

Gallbladder agenesis (GA) is an uncommon congenital anomaly with an incidence of 0.09%. Lack of awareness, coupled with vague clinical and radiological characteristics, has led to infrequent preoperative diagnosis. This is the case of a 42-year-old female who presented with right upper quadrant (RUQ) pain and features of obstructive jaundice. The patient was listed for open cholecystectomy and common bile duct (CBD) exploration for cholelithiasis and choledocholithiasis. At laparotomy, diagnosis of GA with adhesion bands tethering the duodenum to the common hepatic duct (CHD) resulting in biliary stricture, was made. Release of the adhesion bands (adhesiolysis) resulted in CHD stricture relaxation and complete biliary decompression.

**Keywords:** gallbladder agenesis, case report, magnetic resonance cholangiopancreatography, endoscopic retrograde cholangiopancreatography.

Ann Afr Surg. 2023; 20(2): 74-79

**DOI:** <http://dx.doi.org/10.4314/aas.v20i2.7>

**Conflict of interest:** None

**Funding:** None

© 2023 Author. This work is licensed under the Creative Commons Attribution 4.0 International License.

## Introduction

Gallbladder agenesis (GA) is a rare congenital anomaly caused by either inability of the cystic duct to develop or lack of recanalization of the cystic bud during its development (5). Since Lemery first reported the condition in 1701, several cases have been described in the literature, with a reported incidence of 0.09% (2–4). Apart from agenesis, other gallbladder anomalies that can occur are duplication, ectopic position, and internal septations (5). As an anomaly of the embryonic development, GA may be associated with other congenital malformations, for example, biliary duct

atresia, cardiac anomalies, anorectal malformations, malrotation of the gut, renal agenesis, and musculoskeletal anomalies (e.g., syndactyly) (6). Other anomalies associated with GA are Trisomy 18 and Klippel-feil syndrome (7).

About 30–50% of patients with GA present with symptoms of gallbladder disease, often in the 4th or 5th decade of life and would often undergo surgery (2, 7). Half of the symptomatic patients have a dilated biliary tree or choledocholithiasis (2). Common presenting complaints are pain in the right upper quadrant (RUQ)

(90%), dyspepsia (30%), nausea and vomiting (66%), and jaundice (35%) (2).

In addition to being uncommon, lack of awareness and failure of routine diagnostic tools to differentiate between GA and other gallbladder conditions (cholecystitis), make preoperative diagnosis uncommon (7).

To create awareness of GA among surgeons and radiologists, we hereby report a case of symptomatic GA diagnosed at laparotomy.

**Case presentation**

A 42-year-old female presented to our hospital’s surgical clinic as a referral from a peripheral facility with RUQ abdominal pain for 4 months. The pain was intermittent, colicky in nature, non-radiating, and associated with nausea and occasional non-bilious vomiting. She also reported progressive yellowness of eyes, pruritus, pale stool, and dark urine for 4 months. Physical examination revealed jaundice, RUQ tenderness, and hepatomegaly (8 cm below the costal margin). Murphy’s sign was found to be negative.

On musculoskeletal examination, she had hypoplasia of the left index, middle, ring, and little fingers. Liver function tests revealed a total bilirubin level of 121 μmol/L, ALP, 1683U/L, and gamma GT, 298 U/L.

On imaging, a thickened and calcified gallbladder was reported to be seen on abdominal ultrasound (US). This was concluded as cholecystitis.

Computed tomography (CT) scan revealed diffuse intrahepatic biliary duct dilatation with hepatolithiasis, and the gallbladder was not visualized.

Magnetic resonance cholangiopancreatography (MRCP) was done and revealed calculi in the intrahepatic biliary radicles, which were markedly dilated. The gallbladder and cystic duct were not visualized (Figure 1).

The hospital’s weekly meeting of the hepatobiliary multidisciplinary team (MDT) arrived at a diagnosis of hepatolithiasis with intrahepatic biliary dilatation. Endoscopic retrograde cholangiopancreatography (ERCP) and biliary clearance was recommended.

ERCP was performed but there was difficulty in passing the scope from the first to the second part of the duodenum due to a duodenal stricture. Contrast-enhanced cholangiogram revealed a normal CBD with hilar CHD stricture (Bismuth Corlette IIIB) and dilated intrahepatic ducts. A plastic biliary stent, 10 Fr × 120 mm, was deployed past the stricture to the anterior right hepatic duct (ARHD). The gallbladder was not visualized. Thereafter, the jaundice resolved and the liver function tests normalized.

A repeat MRCP to further characterize the hilar and duodenal strictures was done. This revealed a proximal CBD defect, possibly a calculus causing the obstruction. There was associated stranding at the porta hepatis without any mass lesion or lymphadenopathy. There was no duodenal lesion.

This prompted a repeat ERCP with contrast-enhanced occlusion cholangiogram. This once again revealed dilated intrahepatic biliary tree with two defects, possibly calculi, at the confluence, each defect >10 mm in diameter. The gallbladder was not visualized (Figure 2).

Sphincterotomy and controlled radial expansion (CRE) balloon sphincteroplasty up to 12 mm was done. No calculi were extracted. A plastic biliary stent, 10 Fr × 120 mm was re-deployed to the ARHD past the hilar stricture. The patient was then scheduled for open cholecystectomy and CBD exploration.

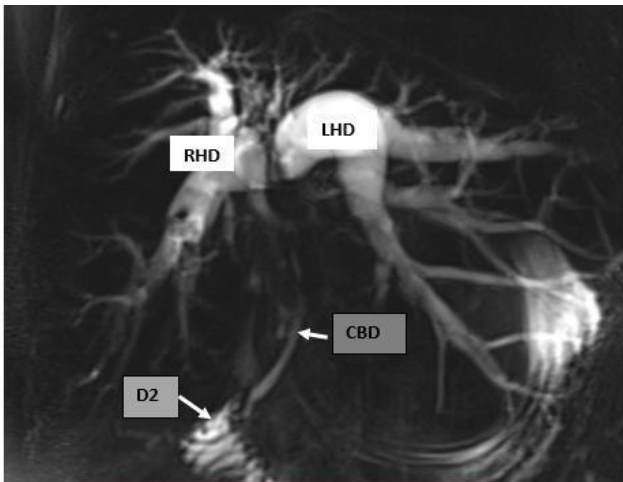


Figure 1. Magnetic resonance cholangiopancreatography: Dilated right and left hepatic ducts, the gallbladder, and cystic ducts not visualized.

At laparotomy, hepatomegaly and extensive adhesive bands (adhesions) were encountered, but no gut malrotation. The first part of the duodenum (D1) was tethered to the porta hepatis by the adhesion bands causing a duodenal stricture. The gallbladder was absent with no gallbladder fossa or cystic plate (Figure 3).

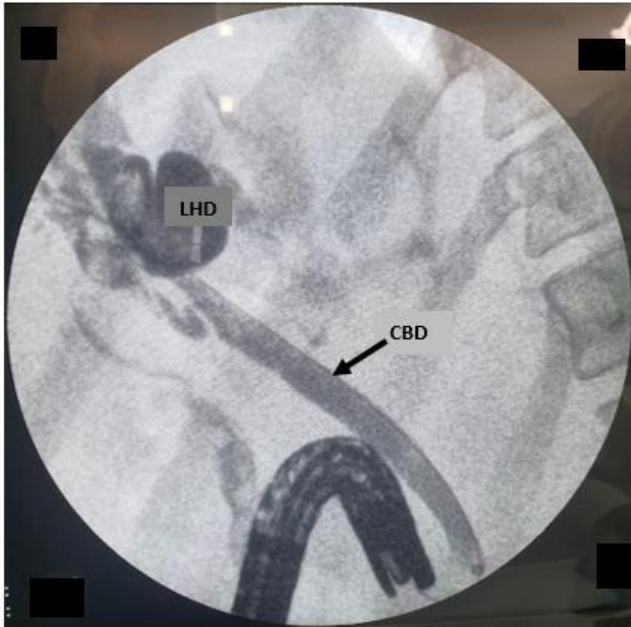


Figure 2. ERCP: Occlusion cholangiogram showing the CBD and dilated intrahepatic ducts. Gallbladder and cystic ducts not visualized.

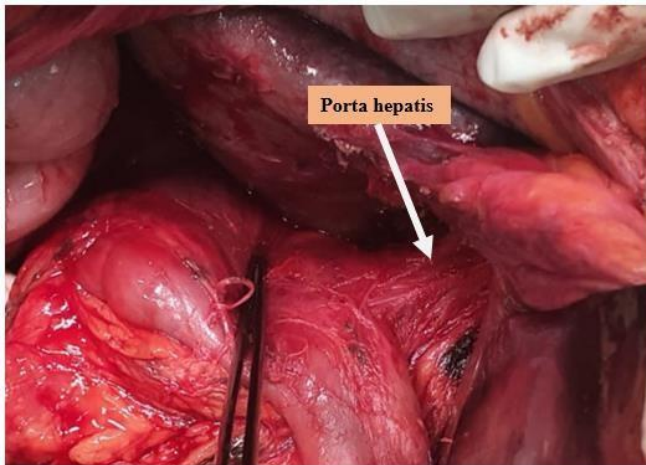


Figure 3. Intraoperative view of the porta hepatis and empty gallbladder fossa

The plastic biliary stent was well inside the CBD, CHD, and into the right hepatic duct (RHD). Adhesiolysis was performed.

Release of the duodenum tethered to the porta hepatis resulted in a D1 perforation of about 0.5 cm in diameter, which was primarily repaired. Upon completion of adhesiolysis, the normal anatomy of the biliary tree at the porta hepatis and the duodenum was restored. There was no residual luminal defect or calculi upon bimanual palpation of the extrahepatic biliary ducts. This explains the stranding at the porta hepatis revealed by MRCP, duodenal, and hilar strictures encountered at ERCP. Abdominal drain was placed, and incision closed.

On review of the labeled abdominal US images, the gallbladder was not visualized.

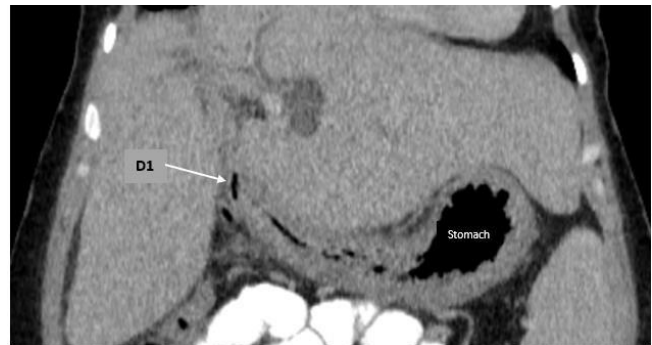

Figure 4. Coronal image of abdominal CT scan, revealing a tented D1 to the porta hepatis.

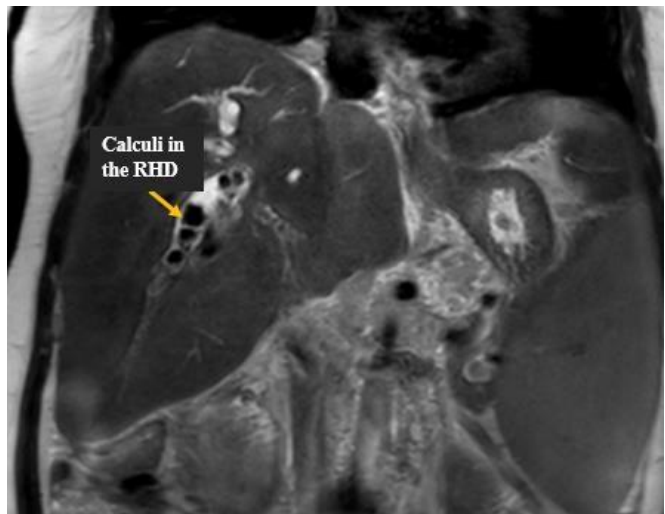


Figure 5: T2 MRI coronal image. Multiple calculi are seen in the RHD

On the CT scan, the first part of the duodenum (D1) was seen being pulled up and attached to the porta hepatis (Figure 4). Multiple intrahepatic calculi were seen on the MRCP images (Figure 5). In all these preoperative images, the gallbladder was not visualized.

The post-operative period was uneventful, abdominal drain was removed on post-operative day 2, and the patient was discharged home on post-operative day 5. Subsequently, the biliary stent was removed 12 weeks later. The patient has since been on follow-up at the surgical outpatient clinic and is symptom-free.

### Discussion

In the 4th week of gestation, a ventral outgrowth of the caudal part of the foregut develops. This is the embryological origin of the gallbladder, biliary system, and liver (5). This outgrowth divides into two parts: the primordium of the liver and the primordium of the gallbladder and cystic duct. Later, recanalization of the gallbladder and cystic duct occurs (5). Failure of this developmental process at any stage leads to GA (5). Also, ectopic gallbladder can occur if the primordium of the gallbladder migrates to a different position (5). This should prompt a search of the gallbladder in case of its absence in the gallbladder fossa. Possible sites of ectopic gallbladder are intrahepatic, left-sided, within the falciform ligament, between the leaves of the lesser omentum, retroperitoneal, retrohepatic, retropancreatic, and retroduodenal (2).

Initial diagnosis of GA is difficult as patients present with symptoms of gallbladder disease (2, 7). Pathogenesis of these symptoms are thought to be like that of post-cholecystectomy syndrome, which is caused by biliary dyskinesia (1). When GA is diagnosed preoperatively, surgical intervention is not indicated, and patients would be put on smooth muscle relaxants (1). Failure of this medical management would prompt an ERCP and sphincterotomy for symptomatic relief (1). Currently available imaging techniques are inadequate in differentiating between GA and other biliary diseases; this has made preoperative diagnosis of GA difficult (9). Also, the lack of awareness of this condition among surgeons and radiologists contributes to this problem (1).

The initial imaging modality for a patient presenting with RUQ pain is an abdominal US (1, 9). Although highly user-dependent, it has a sensitivity of 95% for detecting gallstones. False positives and inconclusive findings occur in cases of intestinal gas artifact, periportal tissue, or subhepatic peritoneal folds (9). US findings of contracted and shrunken gallbladder seen in chronic cholecystitis is difficult to differentiate from GA (1, 9). This is a common report seen in preoperative US for patients diagnosed with GA intraoperatively (8, 10). If a contracted and shrunken gallbladder is seen on abdominal US, further imaging is needed preoperatively to make accurate diagnosis and to avoid unnecessary surgical intervention if indeed it is GA (10). In this case, the tethered D1 to the porta hepatis led to a false positive finding of gallbladder disease on US. Although further investigations were performed (CT, MRCP, and ERCP), and in all these modalities, a gallbladder was not visualized, lack of awareness might have led to the misdiagnosis of gallstones in this case. This highlights the need to create awareness of this condition among surgeons and radiologists.

ERCP is a useful modality, but also non-visualization of the gallbladder is thought to be caused by either cystic duct obstruction or even inadequate contrast (10). In this case, ERCP was done, and the gallbladder was not seen on the cholangiogram. This was thought to be due to inadequate contrast.

MRCP, which is not invasive and not affected by bile stasis, is the modality of choice (9). This modality can be used to confirm the absence of gallbladder or even localize it in the case of ectopic position (9). The MRCP images in this case revealed that the gallbladder was absent. On post-operative review of the images, an ectopic gallbladder was not seen as well.

A preoperative diagnostic algorithm suggested by Malde is useful in patients with suspected GA (Figure 6). In the case of non-visualization of the gallbladder on US in a patient who is symptomatic, MRCP, CT scan, ERCP, or endoscopic US is recommended (1, 2, 10).

In this case, a non-visualized gallbladder on CT scan, MRCP, and ERCP should have raised suspicion of GA. We also propose an addition to the algorithm by Malde; whereby surgical exploration should be considered if all



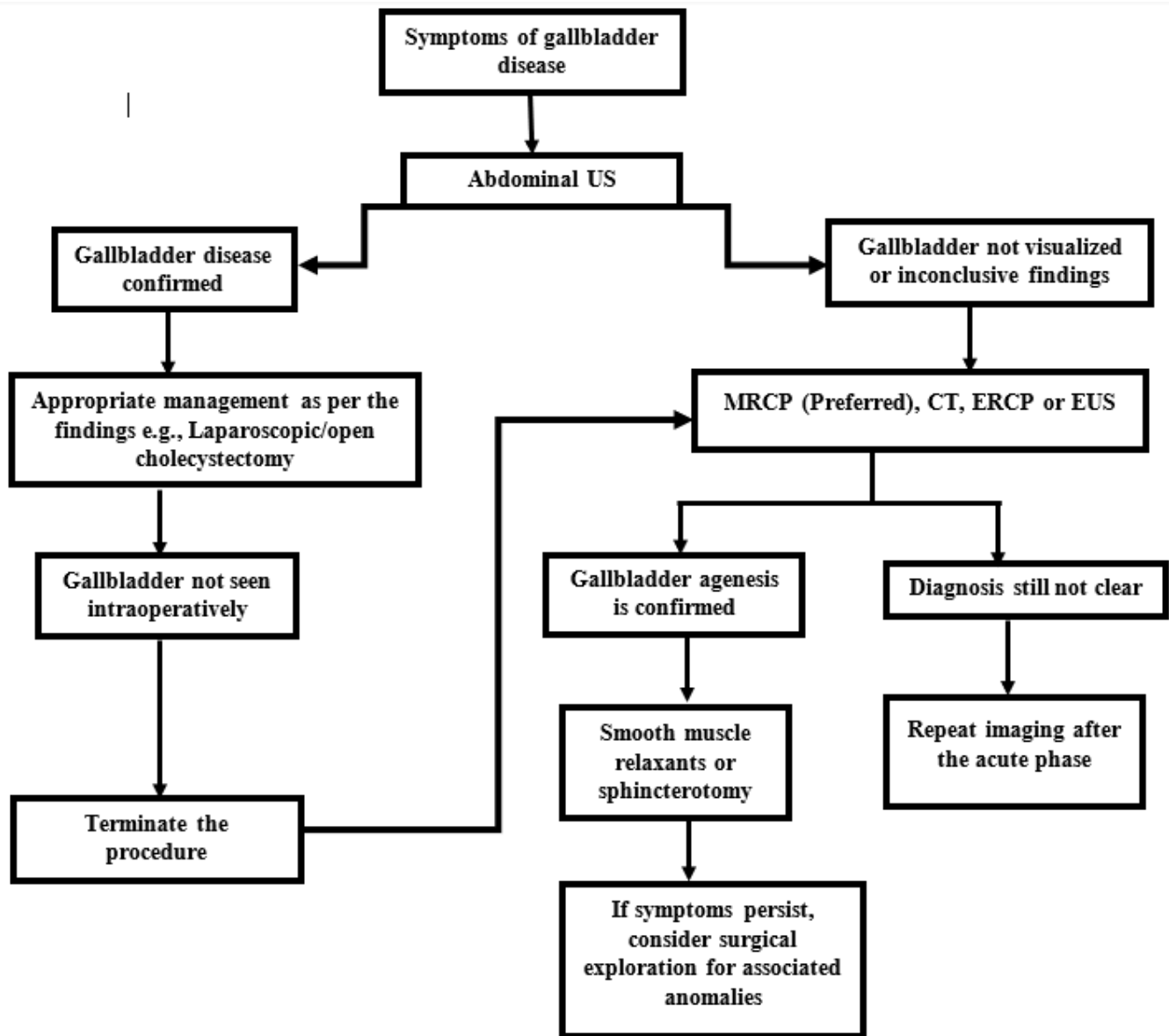


Figure 6: Diagnostic algorithm for gallbladder agenesia (1, 2).

other less-invasive modalities are unsuccessful. This is due to the fact that there may be associated anomalies with GA, like for this particular patient, the adhesive bands causing the duodenal and biliary strictures needed to be addressed and therefore a surgical approach was indeed necessary. Simply giving smooth muscle relaxants or performing endoscopic sphincterotomy would not have sufficed.

**Conclusion**

Adequate preoperative workup is pursued if GA is suspected. Appropriate treatment with smooth muscle relaxants or sphincterotomy is then initiated in patients diagnosed with GA. In the case of preoperative diagnosis, the need to look out for associated anomalies and addressing them should not be ignored.

In the case of intraoperative diagnosis, extensive dissection in search of the gallbladder is discouraged. Rather the procedure should be abandoned and further post-operative workup using MRCP should be pursued.

**Ethical consideration**

The patient gave her consent for this case report and attached images to be published. A copy of the written consent is available and can be reviewed.

**Acknowledgment**

We acknowledge contributions made by the hepatopancreatobiliary tumor board of the Kenyatta National Hospital and the University of Nairobi.

**Author contributions**

AI led in the conceptualization and writing of the first draft. All other authors contributed equally to reviewing and editing the original draft.

**References**

1. Malde S. Gallbladder agenesis diagnosed intra-operatively: a case report. *J Med Case Reports*. 2010; 4: 285.
2. Bahraini A, Odom JW, Talukder A. A case report of a patient with gallbladder agenesis resulting in a common bile duct injury. *Int J Surg Case Rep*. 2018; 51: 99–101.
3. Fiaschetti V, Calabrese G, Viarani S, et al. Gallbladder agenesis and cystic duct absence in an adult patient diagnosed by magnetic resonance cholangiography: report of a case and review of the literature. *Case Rep Med*. 2009; 2009: 1–4.
4. Ben Ismail I, Rebi S, Zenaidi H, et al. Gallbladder agenesis in the elderly: a diagnostic challenge. *Pan Afr Med J*. 2020; 37: 259.
5. Standring S, ed. *Gray's Anatomy: The Anatomical Basis of Clinical Practice*. Forty-first edition. New York: Elsevier Limited; 2016. p. 1562.
6. Cañizares Díaz JI, Arrobas Velilla T. Agenesis of the gallbladder: a case report. *Gastroenterol Hepatol*. 2014; 37: 24–7.
7. Naim H, Hasan SA, Khalid S, et al. Clinical cholecystitis in the absence of the gallbladder. *Cureus*. 2017; 9: e1834.
8. Balakrishnan S, Singhal T, Grandy-Smith S, et al. Agenesis of the gallbladder: lessons to learn. *JLS*. 2006; 10: 517–9.
9. Tagliaferri E, Bergmann H, Hammans S, et al. Agenesis of the gallbladder: role of clinical suspicion and magnetic resonance to avoid unnecessary surgery. *Case Rep Gastroenterol*. 2017; 10: 819–25.
10. Scobie JL, Bramhall SR. Congenital agenesis of the gallbladder: a UK case report. *Oxf Med Case Rep*. 2016; 2016: omw040.