

# Benign Prostatic Hyperplasia in a 13-Year-Old Boy

Chrispine Onyango Oluoch<sup>1</sup> , James Ikol<sup>1</sup> , Gitobu Mburugu<sup>1</sup> , Maxwell Gachie<sup>2</sup> , Dennis Inyangala<sup>3</sup> 

<sup>1</sup>Department of Surgery, Kenyatta National Hospital, Nairobi, Kenya

<sup>2</sup>Department of Radiology, Kenyatta National Hospital, Nairobi, Kenya

<sup>3</sup>Department of Pathology, University of Nairobi, Nairobi, Kenya

**Correspondence to:** Chrispine Onyango Oluoch; email: chrolongreat@yahoo.com

Received: 12 Apr 2022; Revised: 30 Aug 2022; Accepted: 30 Aug 2022; Available online: 5 Sep 2022

## Summary

Benign prostatic hyperplasia (BPH) is most common in men 40 years and above. It rarely occurs in childhood. As a result of the scarcity of cases, the pathogenesis is not clear, and treatment of BPH in this age group is challenging. This report focuses on a 13-year-old patient diagnosed with a histologically confirmed BPH, having presented with a 2-year history of recurrent hematuria and acute urinary retention. Magnetic resonance imaging (MRI) revealed a 287 g prostatic mass, with no signs of malignancy nor metastasis detected. A decision for open suprapubic prostatectomy was made. Post-operative follow-up at 1 year was uneventful. The possible causes of juvenile BPH have been postulated as gonadotropin supplementation for cryptorchidism and human chorionic gonadotropin-containing agent use by the mother during pregnancy. Our case had a history of the right inguinal undescended testis with scrotal orchidopexy done at 11 years of age. However, the

patient had no history of human chorionic gonadotropin use, endocrinologic abnormality, or other possible contributing factors. His antenatal history was normal, with no use of human chorionic gonadotropin by the mother. Due to the very few reported cases, there is insufficient data to help understand the pathogenesis of childhood BPH.

**Keywords:** Benign Prostatic Hyperplasia, Pediatric, Childhood

Ann Afr Surg. 2023; 20(2): 51-57

**DOI:** <http://dx.doi.org/10.4314/aas.v20i2.3>

**Conflict of interest:** None

**Funding:** None

© 2023 Author. This work is licensed under the Creative Commons Attribution 4.0 International License.

## Introduction

Benign prostatic hyperplasia (BPH) is a recognized pathology in aging males. It is extremely uncommon in men below 50 years of age. Rare reports have come out in the pediatric population. The literature review reveals about nine reported cases (Table 1). The rarity of the cases poses a significant challenge in understanding the pathogenesis and treatment in the pediatric population. Our patient was a 13-year-old male who had intermittent gross hematuria and recurrent acute urine retention for 2

years and was finally treated for BPH through open suprapubic prostatectomy.

## Case presentation

A 13-year-old patient presented with a 2-year history of intermittent hematuria and recurrent acute urine retention. He was initially evaluated in our facility in December 2018 and discussed in a multidisciplinary

Table 1. Cases of BPH in young patients reported in the literature

CASE	AUTHOR	YEAR	PRESENTATION	TREATMENT AND OUTCOMES
1.	Powell et al.	1939	17-year-old. Dysuria. Gonadotrophin use for cryptorchidism treatment.	Conservative management.
2.	Sumiya et al.	1987	20-year-old. C/O dysuria, perineal pain.	380 g prostate excised via open suprapubic prostatectomy.
3.	Harada et al.	1989	28-year-old. C/O dysuria, hematuria.	31 g prostate excised via open suprapubic prostatectomy.
4.	Romano et al.	2001	23-year-old. C/O dysuria, acute urine retention, urine incontinence, enuresis. Had acromegaly.	38 g prostate. Underwent TURP.
5.	Choi et al.	2005	10-year-old. C/O dysuria, hematuria.	55 g prostate. Underwent TURP at 10 years and suprapubic prostatectomy at 13 years.
6.	Georgiades et al.	2014	27-year-old. C/O lower urinary tract symptoms. Hematospermia.	181 g prostate. Underwent TURP.
7.	Ismail Yagmur et al.	2017	17-year-old male. C/O hematuria, acute urine retention.	Prostate size: 48 × 55 × 68 mm <sup>3</sup> . Underwent TURP. Uneventful follow-up at 1 year.
8.	Skander Zouari et al.	2018	22-year-old male. C/O acute urine retention, left renal colic.	Prostate size 60 g, post-void residue 280mL, bilateral hydronephrosis. Underwent TURP.
9.	ZhangchengLiao et al.	2019	29-year-old male. C/O ketamine abuse, dysuria, frequency, urgency.	Hydronephrosis, hydroureters, bladder thickening, enlarged prostate, post-void residual volume 100mL.

Abbreviations: C/O, complains of; TURP, transurethral resection of the prostate.

meeting. He had no history of urethral instrumentation or pelvic or perineal trauma.

He did not have any neurological abnormality, constipation, or kidney stones. There was no prior treatment with hormonal therapy, nor was there a history of prostate gland disease in his family. His antenatal period was normal, with no history of his mother using human chorionic gonadotropin-like hormone supplements. At 11 years, he underwent scrotal orchidopexy for the right undescended testis. He had bilaterally palpable scrotal testes with a well-developed circumcised penis. There were no palpable nodules in the prostate. The prostate-specific antigen (PSA) measurements were all below 0.3ng/mL. The contrast-

enhanced computed tomography (CECT) scan performed at the initial presentation demonstrated a prostatic mass of 62 g with other abdominal viscera normal (Figure 1, A and B). A multidisciplinary meeting decided to offer him transurethral resection of the prostate (TURP) and tumor biopsy. However, a pediatric resectoscope was lacking. Eleven months later, the parents sought treatment from a different facility.

The patient was diagnosed with a bladder mass followed by an unsuccessful attempt at open excision of the tumor. The surgery was abandoned after realizing that the tumor was not a urinary bladder tumor (Figure 2A). However, the patient underwent incisional biopsies (Figure 2B).

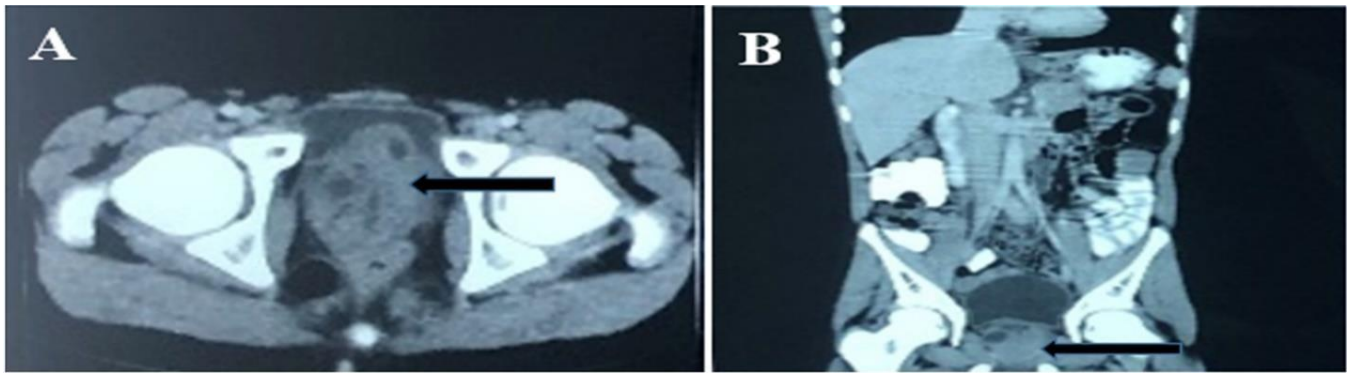


Figure 1. Initial abdominal–pelvic CECT scan (December 2018), shows an enlarged heterogeneous prostate mass of 60 g (black arrows) indenting the bladder base. Other abdominal viscera such as kidneys are normal. (A) Axial plane. (B) Coronal plane. Abbreviation: CECT, contrast-enhanced computed tomography.

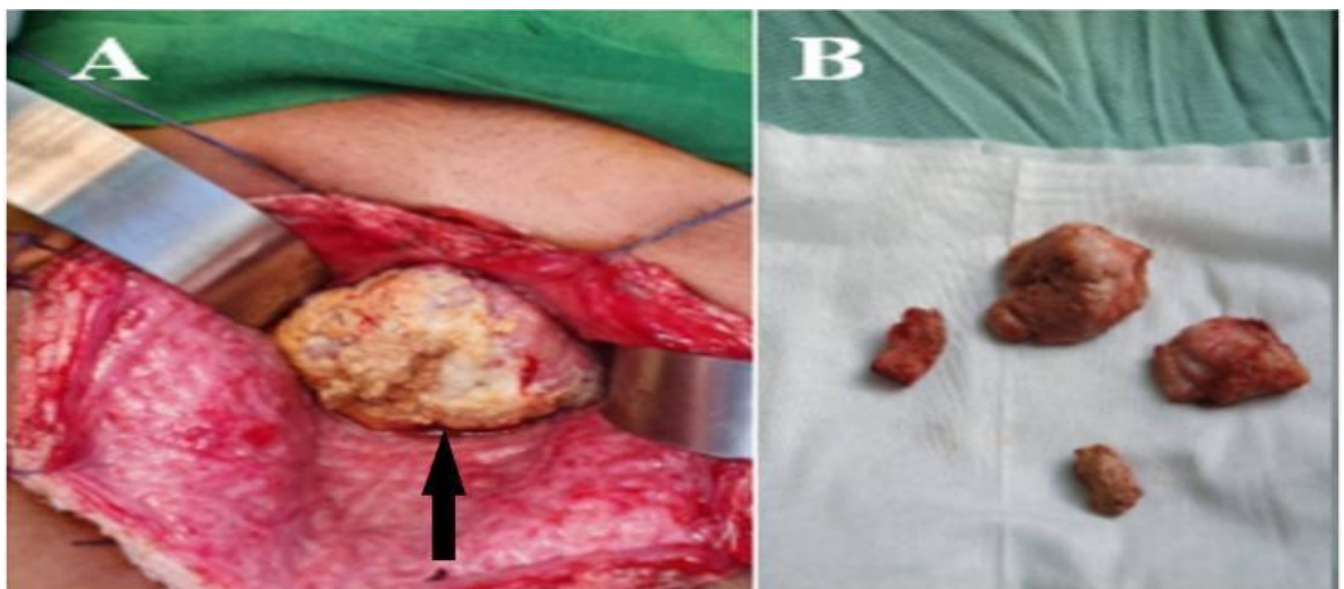


Figure 2. (A) Opened urinary bladder showing prostate median lobe (black arrow) protruding into the bladder lumen. (B) Incisional biopsies taken during the aborted surgery.

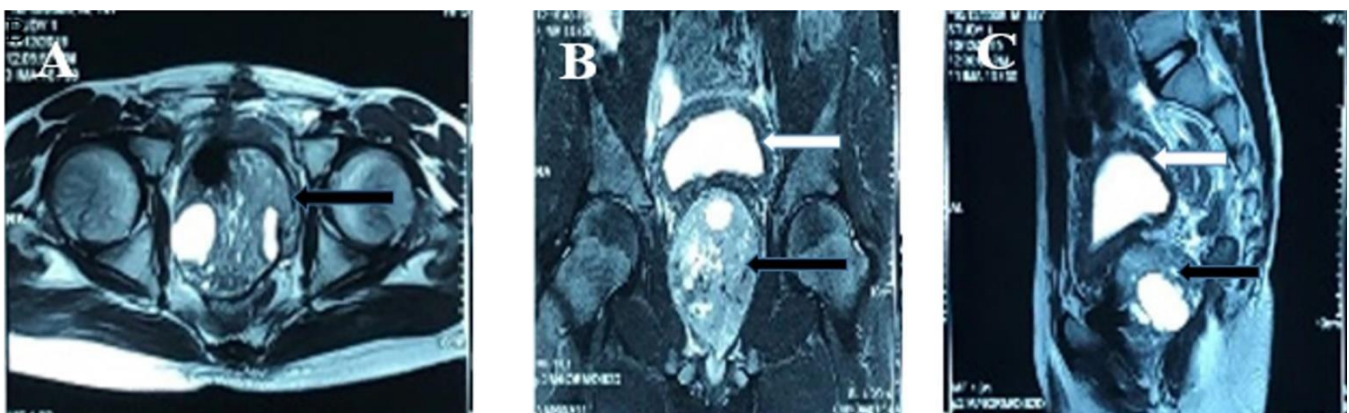


Figure 3. Initial MRI image (December 2019) shows an enlarged prostate mass measuring 189 g with multiple cystic locules and an intact capsule (black arrows), concentric regular bladder wall thickening (white arrows). (A) Axial plane. (B) Coronal plane. (C) Sagittal plane. Abbreviation: MRI, magnetic resonance imaging.



He was sent back to our facility for further assessment and treatment. Magnetic resonance imaging (MRI) showed an enlarged solid prostatic mass (189 g) with multiple cystic locules, an intact capsule, and a concentric regular bladder wall thickening (Figure 3). His follow-up became irregular with the emergence of the COVID-19 pandemic and the subsequent travel restrictions.

He was eventually admitted through the emergency department to our facility 1 year later, as an emergency with sepsis. A repeat MRI showed an interval increase in the size of prostatic mass to 291 g and the development of a pelvic abscess (Figure 4)

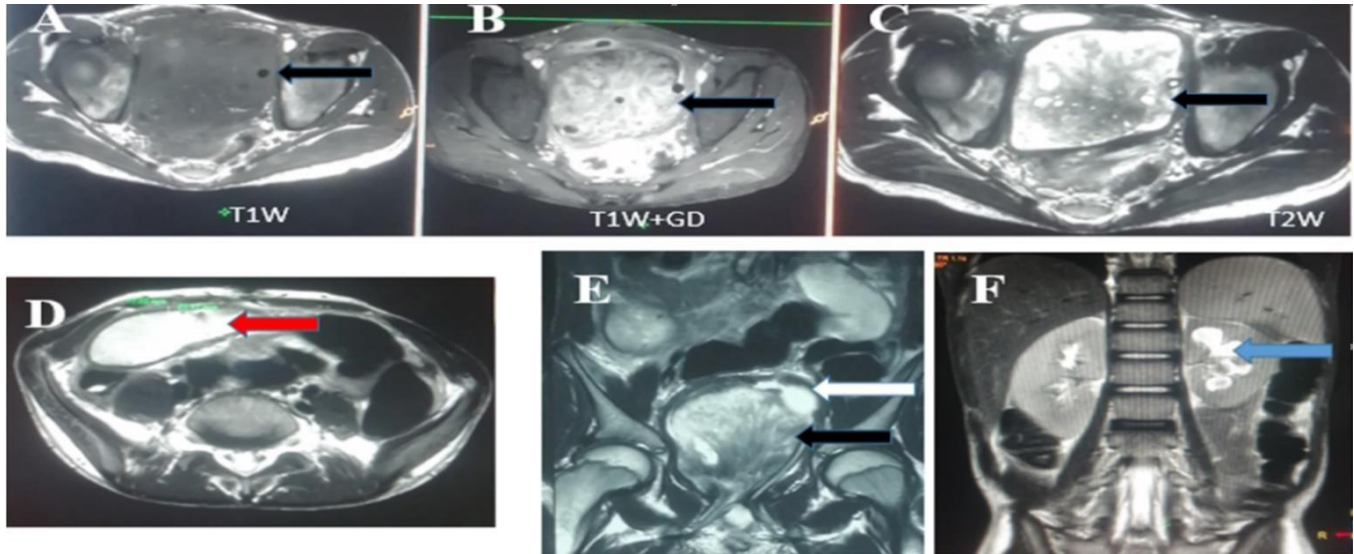


Figure 4. MRI images (September 2020) show an interval increase in the size of the prostate mass to 291 g (black arrows) (A, B, C, E). The mass is heterogeneous with cystic locules and flow voids and fills the bladder lumen which is collapsed with a catheter in situ (white arrow) (E). There is bilateral hydronephrosis more pronounced on the left side (blue arrow) (F), loculated peritoneal collections with thick walls concerning for abscesses (red arrow) (D). (A, B, C, D)—Axial plane, (E, F)—Coronal plane. Abbreviation: MRI, magnetic resonance imaging.

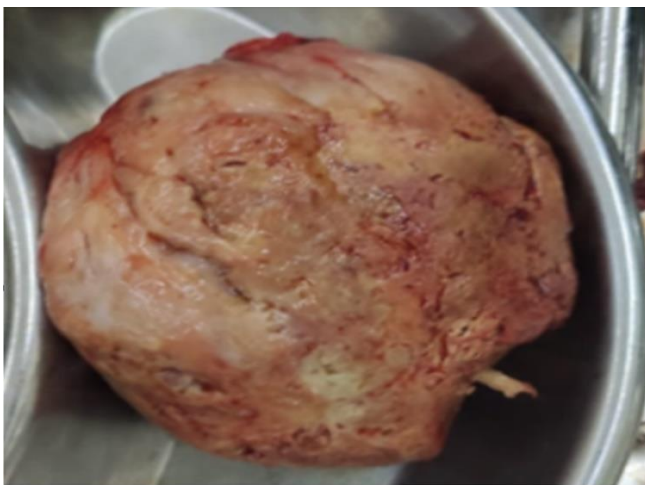

Figure 5. Enucleated prostatic mass during the open suprapubic prostatectomy weighing 258 g.

There was no lymph node enlargement or any pelvic or abdominal metastases on imaging. The abscess underwent drainage percutaneously, and he received culture-directed

antibiotics. The patient underwent fresh transrectal prostatic biopsies, with a reevaluation of the initial ones. A repeat multidisciplinary tumor board discussion opted for open suprapubic prostatectomy.

Intraoperatively, the enucleated prostatic tissue mass was 258 g (Figure 5). The histological examination of the specimen from open suprapubic prostatectomy revealed a benign prostatic enlargement (Figure 6).

Post-operatively, the patient developed a delay in urinary bladder healing, which was managed

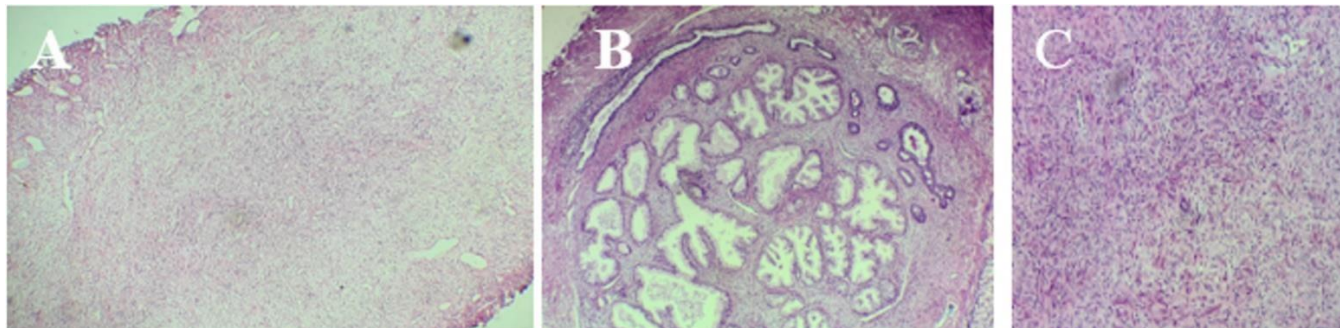


Figure 6. Microscopic histological examination of the specimen from open suprapubic prostatectomy revealed benign prostate hyperplasia using the hematoxylin-eosin stain. Benign stromal proliferation composed of bland spindle cells (A) 40 $\times$  magnification and (C) 200 $\times$ . Nodule composed of variably sized glands showing dilatations and papillary infoldings (B).

conservatively through a long stay percutaneous drain and an indwelling urethral catheter.

He was discharged from the hospital on the 28th day post-operatively, fully ambulant, and without a urethral catheter or percutaneous drain. His follow-up at our clinic has been uneventful. At 1-year post-operative, he has no lower urinary tract symptoms (LUTS), gained significant weight, and resumed schooling. His total PSA level is 0.201 ng/mL, and total testosterone is 28.47mmol/L. We intend to offer him long-term follow-up at our urology clinic to monitor complications such as urethral stricture, erectile dysfunction, and retrograde ejaculation and to document his progress and adulthood.

### Discussion

BPH is a histologically confirmed noncancerous growth of prostatic tissue. Population-based studies show that it develops after the fourth decade of life, with an age-dependent prevalence reaching up to 60% in older men over 50 years (1,2). Pediatric prostatic tumors are sporadic, with only a few cases of rhabdomyosarcoma and BPH reported in the literature (3,4). The pathogenesis of BPH is wide-ranging. Some postulated causes in adults include testosterone, dihydrotestosterone (DHT), increased prostatic stem cells with aging, and prostatic stromal-epithelial interaction (5,6). The testes produce testosterone which is converted into DHT by 5-alpha-reductase type 2 within the prostate stromal cells. DHT accounts for about 90% of prostatic androgens and has autocrine, paracrine, and endocrine effects on prostatic tissue and adjacent cells, hence influencing cellular proliferation

and cell death. Growth factors, such as FGF, EGF, TGF-beta, and so on, also impact the growth of the prostatic cells (7). BPH eventually develops due to the loss of control of cell proliferation and cell apoptosis, causing an imbalance in favor of cell proliferation (5). There is a scarcity of data describing the development of BPH in the pediatric age group. Two cases of BPH in childhood had an etiological link. In one case, there was gonadotropin supplementation for cryptorchidism. In the other, a human chorionic gonadotropin-containing drug was used during pregnancy. In the other cases, no risk factors were established (4,8). Our patient did not have any endocrinologic abnormality, had no history of hormonal drug use, or any other potential contributor. Childhood cases like ours without any associated etiology suggest that other etiologic causes are involved. Thus, more information is required.

BPH leads to a progressive increase in urethral resistance. The presentation is with LUTS, which encompass storage, voiding, and/or post-micturition symptoms. The urinary bladder responds by compensatory hypertrophy and increased deposition of interstitial collagen, resulting in increased urinary bladder weight. Initially, the enormous bladder bulk is adequate for maintaining good detrusor muscle contractility and voiding, but with persistent obstruction, the bladder decompensates with consequent incomplete bladder emptying and development of complications. The complications include bladder stones, urinary tract infections, urinary retention, and renal insufficiency (9). Our patient had recurrent acute urinary retentions with intermittent hematuria. A palpable mass on digital rectal

examination should trigger a clinician to consider a prostatic rhabdomyosarcoma besides a rarer BPH. Imaging evaluation includes ultrasonography, CECT scanning, and MRI (8). Rhabdomyosarcoma is an aggressive tumor leading to early metastasis. Our patient had neither metastases nor lymph node involvement. The initial histopathology reported a spindle cell tumor likely to be a prostatic leiomyosarcoma. As the patient lacked any features of a malignancy, a repeat transrectal biopsy was performed. A team of pathologists reevaluated the specimens and confirmed BPH. Suprapubic open simple prostatectomy was performed. Pre-operative histological diagnosis of BPH precluded the patient from undergoing a more aggressive radical prostatectomy.

Treatment of BPH in adults is well established, with international guidelines. The adult guidelines recommend surgery in case of severe LUTS, high pressure chronic urinary retention, persistent gross hematuria, and recurrent urinary tract infections. Without those mentioned above, medical therapy with 5-alpha reductase inhibitors, alpha-blockers, anti-muscarinic, and/or phosphodiesterase type 5 inhibitors are used (10). There is no study on the use of these drugs in pediatrics. Simple open prostatectomy is a preferred treatment for a prostate gland of more than 80 g.

The scarcity of pediatric cases causes a challenge in developing consensus on the management. The experiences gained from treating adults are used to guide pediatric treatment options. In the published literature, open prostatectomy was performed in most BPH cases in the pediatric age group. TURP was performed on a 10-year-old boy with a prostate of 33 g. The author, however, dissuaded urologists from performing TURP in pediatric patients due to quick regrowth (11).

Longer post-operative follow-up is required to monitor surgery complications such as urethral stricture, retrograde ejaculation, and erectile dysfunction and to document post-childhood life and progress. Recommended follow-up involves taking history using validated questionnaires such as International Prostate Symptom Score, targeted physical examination, for example, digital rectal examination, PSA level, post-

void residual volume, and free uroflowmetry as per the adult practice (12).

### Conclusion

BPH is an infrequent disease entity in childhood. Urologists should, however, always be aware of its possibility while evaluating boys with acute urinary retention and prostatic masses. Radiological and histological evaluation is essential in patients who present with LUTS and a suspicious prostate on rectal examination. Optimal urosurgical management in pediatric patients is currently unknown. The practicing urologists may have to borrow from adult management guidelines.

### Ethical consideration

Informed consent for publication was obtained from both the patient and the father. This review also underwent ethical approval from the Institutional Review Board with a review, Ref: KNH-ERC/01/PUB/2.

### Author contributions

All other authors contributed equally in the conceptualization and writing of the first draft to reviewing and editing the original draft.

### References

1. Platz EA, Joshu CE, Mondul AM, et al. Incidence and progression of lower urinary tract symptoms in a large prospective cohort of United States men. *J Urol.* 2012; 188:496–501.
2. Yeboah ED. Prevalence of benign prostatic hyperplasia and prostate cancer in Africans and Africans in the diaspora. *J West Afr Coll Surg.* 2016; 6:1-30.
3. Yağmur I, Turna B, Tekin A. et al. Benign prostatic hyperplasia: case report of a 17-year-old. *J Pediatr Urol.* 2016; 12:267. e1-4.
4. Ciammella P, Galeandro M, D'Abbiere N, et al. Prostate embryonal rhabdomyosarcoma in adults: case report and review of literature. 2013; 18:310–5.
5. Roehrborn C. Pathology of benign prostatic hyperplasia. *Int J Impot Res.* 2008;20: S11-8.
6. Madersbacher S, Sampson N, Culig Z. Pathophysiology of Benign Prostatic Hyperplasia and Benign Prostatic Enlargement: A Mini-Review. *GER.* 2019; 65:458–64.
7. De Nunzio C, Presicce F, Tubaro A. Inflammatory mediators in the development and progression of benign prostatic hyperplasia. *Nat Rev Urol.* 2016; 13:613–26.

8. Choi YD, Cho NH, Kwon DH, et al. Juvenile prostatic hyperplasia. *Urology* 2005; 66:881.
9. Speakman MJ, Cheng X. Management of the complications of BPH/BOO. *Indian J Urol* 2014; 30:208–13.
10. Gravas S, Cornu J, Gacci M, et al. Management of non-neurogenic male lower urinary tract symptoms (LUTS), incl. benign prostatic obstruction (BPO). *European Association of Urology. Guidelines; 2022; 1:70*
11. Liao Z, Wang Z, Jin Z.etal. Dysuria due to benign prostatic hyperplasia of the median lobe with ketamine-associated uropathy in a young male. *BMC Urol.* 2019;19: 105.
12. Zouari S, Bouassida K, Ahmed KB, et al. Acute urinary retention due to benign prostatic hyperplasia associated with cystitis glandularis in a 22-year-old patient. *Pan Afr Med J.* 2018; 30:30.