

Clinical Spectrum, Management, and Outcome of Rectovaginal Fistulae

Silindokuhle Revivial Sibiya , Surandhra Ramphal , Thandinkosi Madiba , Frank Anderson 

University of KwaZulu-Natal, Durban, South Africa

Correspondence to: Silindokuhle.R. Sibiya; email: slindosibiya88@gmail.com

Received: 11 Oct 2021; Revised: 24 Aug 2022; Accepted: 25 Aug 2022; Available online: 12 Sep 2022

Abstract

Background: There are limited reports on rectovaginal fistulae in South Africa. **Methods:** This was a prospective analysis of all patients undergoing treatment for RVF at a tertiary referral hospital. Data was extracted from the database between 2006 and 2018 and analysis included demographics, aetiology, management, and outcome. The main outcome measure was healing of the fistula. **Results:** Fifty patients were identified [Median age 36 (IQR 28-42) years]. HIV status was positive (31), negative (5) and unknown (14). Commonest causes were obstetric (17), perineal sepsis (14) and spontaneous (8) (Table 2). Median duration of symptoms was 34.5 months (IQR 5-72) (Diagram 1). Forty-two patients underwent 55 surgical procedures (including 14 redos). In 32 patients RVF repair was undertaken under colostomy cover and 28/42 fistulae healed after the initial repair (66.7%), final success

rate was (41/42) 97.6%. Two of eight fistulae healed after non-operative management (25%). **Conclusion:** Obstetric injury was the leading cause of RVF. HIV positive patients predominated. Spontaneous fistulae were seen in immunocompromised patients. Success rate was 97.6% over a healing time of 3 months. Non-operative management led to healing in 25% of cases.

Keywords: Rectovaginal fistula, fistula repair, fistula management

Ann Afr Surg. 2022; 19(4): 200-206

DOI: <http://dx.doi.org/10.4314/aas.v19i4.7>

Funding: None

© 2022 Author. This work is licensed under the Creative Commons Attribution 4.0 International License.

Introduction

Rectovaginal fistulae (RVF) are abnormal epithelialized connections between the rectum and/or anal canal on the one end and the vagina on the other end (1). They are associated with significant distress and poor quality of life (2). They result from difficult labor, inflammatory bowel disease (IBD), neoplasms, and infections such as cryptoglandular and Bartholin gland abscess, tuberculosis, and lymphogranuloma venereum. RVF occur as a complication of delivery or uterine evacuation usually in the absence of skilled medical staff assistance in situations where there is lack of access to

high-quality obstetric care (3). Obstetric fistula is associated with several preventable risk factors, which include young age (teens) at delivery, primiparity, prolonged labor, and home delivery (3). The mechanisms of obstetric injury are prolonged obstructed labor leading to necrosis of the rectovaginal septum and third- or fourth-degree perineal tears sustained during difficult labor (3-5). The fistula is clinically apparent 1 to 2 weeks after delivery and is most often located at the level of the anal sphincters (3). Approximately 10% of immediate repairs fail leading to anorectal pelvic floor

dysfunction such as anal incontinence and/or RVF (3). Surgical repair has reported success rates ranging between 69% and 80% in the African continent (5).

Obstetric causes are rare in high-income countries, but they remain prevalent in low- and middle-income countries (6). More than 2 million women worldwide have RVF, with at least 50,000 to 100,000 new cases occurring annually (6, 7). Among these, the majority are from low- and middle-income countries, which tend to be resource-poor and with ineffective health delivery systems (2, 4, 7). In sub-Saharan Africa, lifetime prevalence ranges between 0.4 and 19.2 per 1000 women of reproductive age (3, 8).

The classification of RVF is based on location, size, and etiology (1). A common classification system is based on the size and anatomic position in the vagina, as described by Zitsman and Glowacki (20) (Table 1). The anorectal part of the fistula is also classified as suprasphincteric, intersphincteric, or low/trans-sphincteric.

Although there is a plethora of data from African series reporting on RVF, there is scarce literature describing the management of this condition in the South African context. A previous report from South Africa reported on 87 genital tract fistula, and 36 (41.4%) of which were RVF (9). All were repaired transvaginally and 9.2% required stomas, two of which were permanent (9). The overall success of the initial repair was 85.1% but the RVF were not analyzed separately in this report, and the present research sought to analyze RVF as a single entity (9).

Materials and Methods

The prospective study was carried out at the colorectal unit of a quaternary referral hospital. The prospective database commenced in 2006 in a colorectal clinic, and the study duration was from 2006 to 2018. Patients with malignant fistulae were excluded from the analysis.

We classified RVF as shown in Table 1. Anal endosonography was selectively used in patients with suspected anal sphincter compromise. Biopsy of the fistula was routinely performed to identify or exclude infectious causes and malignancy. High RVF were repaired transabdominally, and a local approach was

used for low fistulae (transvaginal, endorectal, or transperineal). The decision on the surgical approach was made by a pelvic floor multidisciplinary team.

Table 1. Classification of rectovaginal fistulae (adapted from zitsman & glowacki)

Fistula type	Size & Location
Simple	Diameter < 2.5 cm
	Any location above dentate line
Complex	Diameter > 2.5 cm
	Any location above dentate line Recurrent fistula
Low	Near vaginal opening and posterior fourchette
Mid-level	Above posterior fourchette; distal to level of cervix
High	Level of posterior fornix

The main outcome measure was healing of the fistula at digital rectal examination—epithelization without residual tract, external or internal openings, or perianal discharge (10). Persistence of anal fistula was defined as presence after more than 6 months after surgery, recurrence as reappearance after complete healing within 1 year after surgery, and de novo fistula as clinical appearance after complete healing more than 1 year after surgery (10). The median follow-up was 5.5 months (range, 1–108 months) (Table 2). Continuous variables were analyzed as median and interquartile range, and categorical variables as numbers (percentage). Ethics approval was granted by the Biomedical Research Ethics Committee of the University of KwaZulu-Natal (reference number: BE297/18 substudy of BE231/13).

Results

Of the 91 patients presenting with RVF, 41 were excluded because of a malignant etiology. The median age of the 50 patients was 36 years (interquartile range, 28–42 years). The causes are presented in Table 2.

Thirty-one patients were HIV+, 5 were HIV–, and 14 had unknown HIV status. Most fistula were obstetric-related (Table 1). Eight patients (16%) had anal sphincter weakness, and 5 (10%) had coexistent cryptoglandular anorectal fistulae (10%); none were

related to IBD. The median duration of symptoms before referral was 34.5 months (interquartile range, 5–72 months). The median follow-up was 5.5 months (range, 1–108 months) (Table 2). The fistulae were classified as complex (n=40) and simple (n=10). A prior diverting colostomy was created in 32 patients.

Table 2. Comparative table of aetiology and outcomes in Rectovaginal fistula

Year	n	Age(years)	Aetiology	n(%)	Success:n(%)	Surgical approach	n	Success (%)	Procedures/patient	Follow-up
2021	50	36 (28-42)	Obstetric	17 (34 %)	40 (95%)	Transvaginal	14	92.90%	1.3	5.5 months
			Perineal sepsis	14 (28%)		Transperineal	26	96.20%		
			Spontaneous	8 (16%)		Transabdominal	1	100%		
			Previous surgery	6 (12%)		Endorectal	1	100%		
			Trauma	2 (4%)						
			Radiation	2 (4%)						
			Iatrogenic	1 (2%)						
2021	40	23 - 65 (41.6)	Obstetric trauma	33(82.5%)	33(82.5%)	Trans-anal endorectal advancement Flap with sphincteroplasty	20	95%	NS	24 months (12-36)
			Iatrogenic	4(10%)		Trans-vaginal purse string inversion	8	75%		
			Radiotherapy	2(5%)		Trans-perineal repair with Sphincteroplasty	4	75%		
			Traumatic	1(2.5%)		Overall local repair	32	87.50%		
			Recurrent	5(12.5%)		Trans-abdominal repair	8	50%		
						Overall repair	33	82.50%		
2010	177	41.8(± 13)	IBD	57(45.6%)	103(87.3%)	endorectal advancement flap	71	56.30%	1.5	20.1 months
			a. Crohns dis	45		gracilis muscle interposition	24	79.20%		
			b. Mucosal UC	12		transvaginal repair	15	60%		
			obstetric injury	30(24%)		transperineal	15	66.70%		
			surgical trauma	20(16%)		Other	52	50%		
			Others	18(14.4%)						
2019	90	49 (16–80)	Radiation	27(29.3)	39(42.4%)	Diverting stomy alone	5	8.20%	1.4	17 months (0–123)
			Pelvic surgery	26(28.3)		Transanal rectal advancement flap	19	51.40%		
			Obstetric trauma	15(16.3)		Gracilis muscle transposition	3	42.90%		
			Perineal operation	11(12)		Bowel resection	2	33.30%		
			Cancer invasion	7(7.6)		Sphincteroplasty with perineoplasty	6	100%		
			Crohns disease	4(4.3)		Fistulectomy with seton	1	20%		
			Trauma	1(1.1)		Stem cell injection	2	66.70%		
			Unknown	1(1.1)		Martius flap	1	33.30%		
2010	100	42.8±10.5 years	Obstetric trauma	60(60%)	68(68%)	Diverting stoma	62	62%	Healed: 2 (1–5)	45.8±39.2 months
			Cvrytroglandular abscess	40(40%)		Episioproctotomy	39	78%	UnheaLed: 4 (1–8)	
						Advancement flap	23	62.20%		
						Colo-anal anastomosis	3	50%		
						Other	3	42.90%		

Eight patients with a spontaneous etiology had HIV infection (n=7) and diabetes (n=1). The CD4 counts in 4 patients ranged from 293 to 576 cells/mm³. In an HIV+ patient on antiretroviral treatment (ART) with unknown CD4 count, the fistula healed spontaneously. The other six patients were managed successfully operatively. Forty-two patients underwent 55 surgical repairs, and 8 patients were managed non-operatively. Of the 42 patients, 41 underwent local repair of the fistulae and 1 underwent laparotomy for a successful repair of a high fistula. The surgical approach for local repair was transperineal (n=26), transvaginal (n=14), and

endorectal (n=1) (Figure 1 and Table 2). Eight (16%) had associated anal sphincter defects that were reconstructed.

The transvaginal approach had an initial success rate of 57.1% (8/14). Six patients had redo procedures: four transvaginally, with one failure, and two were successfully repaired using a transperineal approach. The one failed transvaginal repair was lost to follow-up and never healed. The overall success rate of the transvaginal approach was 92.9% (13/14) (Figure 1 and Table 2).

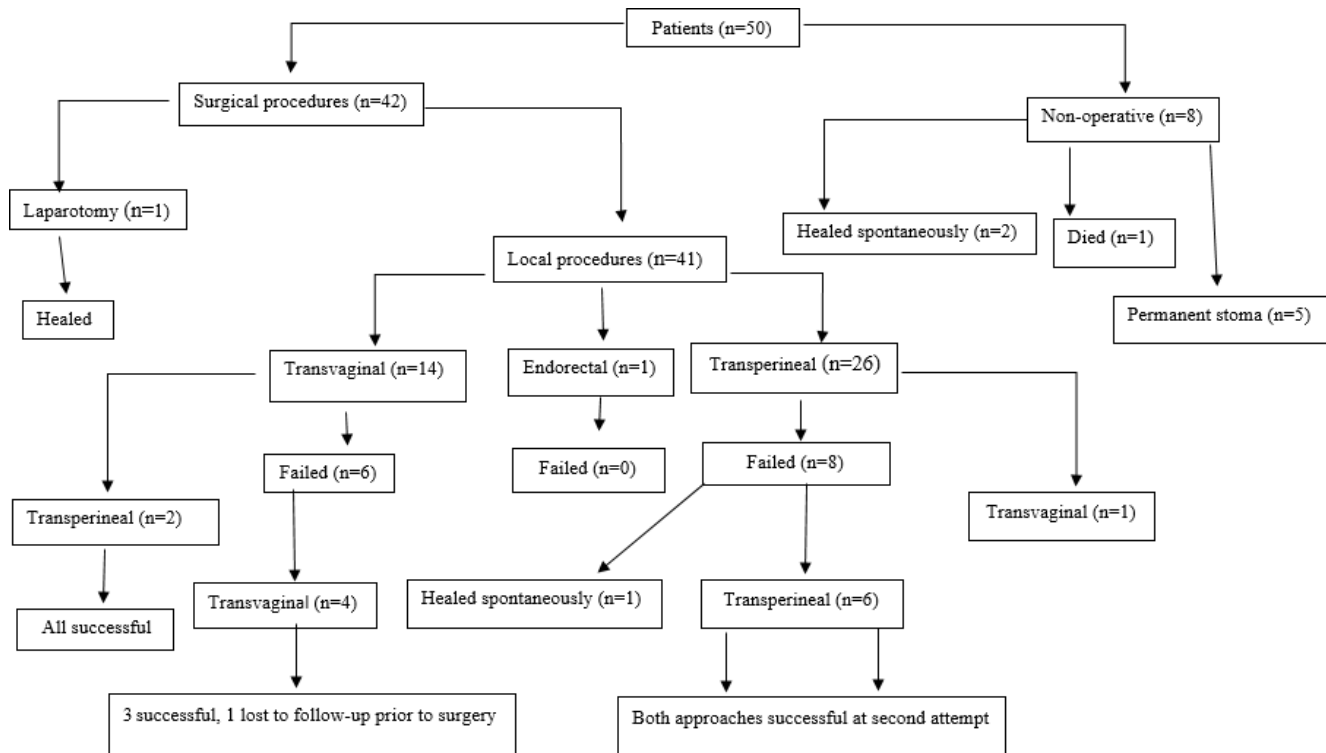


Figure 1. Management of Rectovaginal fistula

The initial success rate for transperineal repair was 69.2% (18/26) and after repeat surgery 96.2% (25/26) (Table 2). In six patients, the second operation was transperineal (6/8) and transvaginal (1/8), all of which were successful. One patient healed spontaneously prior to re-do surgery (Figure 1).

Of 14 patients with failure of initial repair, 7 had wound sepsis. The rest had dehiscence of the repair without wound sepsis. Of the 14 patients with persistent fistula,

13 had redo procedures. Two of these with deficient rectovaginal septa had a modified Martius flap interposition.

Of the 31 HIV+ patients, 19 had known CD4 counts, of whom 12 and 7 had CD4 counts >200 and ≤200 cells/mm³, respectively. In those with CD4 counts >200 cells/mm³, the surgical success rate was 91.7% (11/12). The one failure had a radiation-induced fistula. In patients with CD4 ≤200 cells/mm³, 5 (71.4%) had

successful surgical management and 1 (14.3%) had spontaneous healing. Two patients with spontaneous fistula who were not on ART and had CD4 counts >200 cells/mm³ (453 and 500 cells/mm³) healed with one surgical procedure.

Of the patients who were managed non-operatively (n=8), 2 had spontaneous fistula following abscesses that healed spontaneously. Both were HIV+ on ART. The CD4 count was 60 cells/mm³ in one, but unknown in the other. Five patients were managed with permanent stomas. Of the 5 patients with permanent stomas, 2 had radiation-induced fistula, 2 patients chose non-operative management, and 1 patient had uncontrolled sepsis, which destroyed the anal canal. The patient who was managed non-operatively died; she had diabetes and associated cardiac problems and died from her comorbidity prior to theater. This patient had a spontaneous fistula without underlying sepsis and was HIV- (Figure 1).

Discussion

In a previous report on genital tract fistula from our country, RVF was found in 36 (41.4%) of 87 patients (9). The etiology of RVF was found to be multifactorial as is the case in other reports. Obstetric-related trauma (34%) was higher than the 12–16% reported in international literature (11). The median follow-up was shorter than that of other studies, but the range (1–108 months) was similar (Table 2).

Despite the sizeable numbers of patients with IBD being seen in our hospital, none of the patients in this series presented with Crohn disease-related RVF. Others have reported IBD to be the causative factor for RVF in 2–23% (1, 11, 12). Infection, such as cryptoglandular anorectal and Bartholin abscess, was the second most common etiology (28%) (4). The infectious causes of RVF are rarely reported in the international literature, but in African studies, they were associated with 40% of fistula and 40% of non-obstetric fistula (4). Spontaneous fistulae in this series (16%) are rarely reported in the international literature (Table 2). RVF following previous surgery was seen in 12%, which compares favorably with the reports of 32% and 76% (13). The incidence of radiation-induced fistulae in patients

receiving radiotherapy ranges between 3% and 11% (14). The defect is often large with fibrosis, fixation of tissues, and associated poor vascularity (15). Closure of the defects by the usual techniques carries a high failure rate (16). A diverting colostomy may often be the only possible treatment for palliation of symptoms. The two patients with radiation-induced fistulae in this series were managed with a diverting colostomy for these reasons.

Surgical techniques for repair of RVF are either local (transanal, vaginal, or perineal approach) or tissue transposition procedures (omentum, gracilis muscle, or labial fat–Martian flap) or transabdominal repair (Table 2). The majority of patients in this study underwent transvaginal/perineal and abdominal repair, as in another large study where 1560 (68%) and 728 (32%) of 2288 patients underwent a transvaginal/perineal and an abdominal repair, respectively. The number of repairs was found to influence the failure rate, as the median number of repairs was 2 (range, 1–5) in the 68% who healed vs. 4 (range, 1–8) in those who had failure of repair ($p=0.007$).

In our study population, the prevalence of HIV was 62% (31/50), which is higher than the general population prevalence of 13.5% (17). Spontaneous closure was found in 2 patients who were both on ART, 1 with a CD4 <200 cells/mm³, and the other unknown. The failure of operative and non-operative management seems to be linked less to the CD4 count but closely related to the underlying cause of the fistula; as is seen in our results, those who never healed had fistula related to radiation. Successful surgical management was independent of CD4 count as 6 of 7 with CD4 <200 cells/mm³ and 11 of 12 with CD4 >200 cells/mm³.

Endoanal ultrasonography is utilized to determine the integrity of the internal sphincter and the septum in the rectum and vagina (18). We employ it in the presence of suspected anal sphincter compromise to better define the anatomy. It is seen in up to 50% of RVF resulting from an obstetric injury. Among the 8 patients (16%) who required additional anal sphincter reconstruction, all except one healed the first time.

The modified Martius labial fat pad flap (MMF) remains the simplest and most versatile interposition tissue for

complex vaginal surgery (19). The MMF uses vascularized adipose tissue flap from the labium majus, and it divides the vaginal and rectal layers and improves wound healing by enhancing blood supply through neovascularization (19). The MMF is useful during RVF repair where tissue integrity is a concern especially in the management of recurrent low fistulae (19). We employed the modified Martius flap in 2 patients with a very thinned-out rectovaginal septum.

The 37.5% success rate in 8 patients who had conservative management in this series was serendipitous. A waiting period of 6 to 9 months is warranted if symptoms remain manageable. Approximately 50% of small RVF heal spontaneously (1, 20).

The diversion of feces by way of a stoma helps control the symptoms and supports the healing of the fistula (11, 21). However, it means an additional distressing condition for the patients and an additional operation with associated complications (22). Its use should be selective and only in patients with contamination of the perianal area or when management of the perianal area is impossible without a stoma.

The initial success rate in this series was 66.7%, and this improved to 97.6% after repeat surgery. This compares favorably with international literature, which reported success rates of 55–93% (23) (Table 2). This success rate can be explained by the centralization of the management, the short follow-up period, the absence of Crohn disease (Table 2), and operations not exceeding two procedures in all patients. This is pertinent, as surgical success rate decreased with successive attempts (24). Although not evaluated in our study, the risk of unsuccessful fistula repair is related to parameters such as large fistulae (>3 cm), circumferential fistulae, and marked vaginal scarring (moderate to severe scarring) (7).

This study has some limitations. There was no long-term follow-up, and this is a possible explanation for the high cure rate. The factors used to select a particular surgical approach other than for high fistula was not documented. Assessment of a deficient rectovaginal septum was also not adequately explained. This is not confined to the current study but applies to other reports

on RVF where there is poor documentation of the evaluation process and tailored surgical approaches. Because of the small number of HIV+ patients in this series, the role of HIV infection cannot be generalized to the rest of the population at risk.

Conclusion

Obstetric injury was the leading cause of RVF in our institution. Spontaneous fistulae were associated with HIV infection. Management of RVF in our setting had reasonable success, with healing rates comparable to international norms. The management of patients with RVF should be surgical regardless of HIV status.

Conflict of interest

None to disclose

Author contributions

SS led in the conceptualization and writing of the first draft. All other authors contributed equally to reviewing and editing the original draft.

References

1. Das B, Snyder M. Rectovaginal fistulae. *Clin Colon Rectal Surg.* 2016; 29 (1): 50-6.
2. Bashah DT, Worku AG, Mengistu MY. Consequences of obstetric fistula in sub Sahara African countries, from patients' perspective: a systematic review of qualitative studies. *BMC Womens Health.* 2018; 18(1): 1-12.
3. Tebeu PM, Fomulu JN, Khaddaj S, et al. Risk factors for obstetric fistula: a clinical review. *Int Urogynecol J.* 2012; 23(4): 387-94.
4. Debeche-Adams TH, Bohl JL. Rectovaginal fistulas. *Clin Colon Rectal Surg.* 2010; 23(2): 99-103.
5. Bernard L, Giles A, Fabiano S, et al. Predictors of obstetric fistula repair outcomes in Lubango, Angola. *J Obstet Gynaecol Canada.* 2019; 41(12): 1726-33.
6. Lilungulu A, Gumodoka B, Nassoro M, et al. Obstetric fistulae, birth outcomes, and surgical repair outcomes: a retrospective analysis of hospital-based data in Dodoma, Tanzania. *SSMJ.* 2018; 11(4): 93-6.
7. Kayondo M, Wasswa S, Kabakyenga J, et al. Predictors and outcome of surgical repair of obstetric fistula at a regional referral hospital, Mbarara, Western Uganda. *BMC Urol.* 2011; 11(1): 23-32.
8. Maheu-Giroux M, Filippi V, Samadoulougou S, et al. Prevalence of symptoms of vaginal fistula in 19 sub-saharan africa countries: a meta-analysis of national

- household survey data. *Lancet Glob Heal*. 2015; 3(5): 271-8.
9. Naidoo TD, Moodley J, Naidoo S. Genital tract fistula: a case series from a tertiary centre in South Africa. *Int Urogynecol J*. 2018; 29(3): 383-9.
 10. Emile S. Recurrent anal fistulas: when, why, and how to manage? *World J Clin Cases*. 2020; 8(9): 1586-91.
 11. Ryoo SB, Oh HK, Ha HK, et al. Outcomes of surgical treatments for rectovaginal fistula and prognostic factors for successful closure: a single-center tertiary hospital experiences. *Ann Surg Treat Res*. 2019; 97(3): 149-56.
 12. Casadesus D, Villasana L, Sanchez IM, et al. Treatment of rectovaginal fistula: a 5-year review. *Aust New Zeal J Obstet Gynaecol*. 2006; 46(1): 49-51.
 13. Devesa JM, Devesa M, Velasco GR, et al. Benign rectovaginal fistulas: management and results of a personal series. *Tech Coloproctol*. 2007; 11(2): 128-34.
 14. Akiba RT, Rodrigues FG, Da Silva G. Management of complex perineal fistula disease. *Clin Colon Rectal Surg*. 2016; 29(2): 92-100.
 15. Zelga P, Tchórzewski M, Zelga M, et al. Radiation-induced rectovaginal fistulas in locally advanced gynaecological malignancies—new patients, old problem? *Langenbeck's Arch Surg*. 2017; 402(7): 1079-88.
 16. Tebeu P, Ekono R, Fouogue J, et al. Pattern of non-obstetric infectious recto-vaginal fistula: a case series and literature review in Cameroon, Central Africa. *Int J Reprod Contraception, Obstet Gynecol*. 2016; 5(7): 2239-42.
 17. Statistics South Africa. Midyear population estimate 2019. *Stat South Africa*. 2019; (July): 1-24.
 18. Yin HQ, Wang C, Peng X et al. Clinical value of endoluminal ultrasonography in the diagnosis of rectovaginal fistula. *BMC Med Imaging*. 2016; 16(1): 1-6.
 19. Durga K, Chandra Kumar AB. Successful repair of complex rectovaginal fistula by modified Martius procedure: a case report. *Int J Clin Obstet Gynaecol*. 2020; 4(1): 42-5.
 20. Zitsman S, Glowacki C. Obstetrics & gynecology: practical CME newsletter for clinicians. *Top Obstet Gynecol*. 2017; 37: 1-5.
 21. Trompetto M, Luc AR, Novelli E, et al. Use of the Martius advancement flap for low rectovaginal fistulas. 2019; 1-8.
 22. Lambertz A, Lüken B, Ulmer TF, et al. Influence of diversion stoma on surgical outcome and recurrence rates in patients with rectovaginal fistula—a retrospective cohort study. *Int J Surg*. 2016; 25: 114-7.
 23. Pinto RA, Peterson T V, Shawki S, et al. Are there predictors of outcome following rectovaginal fistula repair? *Dis Colon Rectum*. 2010; 53(9): 1240-7.
 24. El-Gazzaz G, Hull TL, Mignanelli E, et al. Obstetric and cryptoglandular rectovaginal fistulas: long-term surgical outcome; quality of life; and sexual function. *J Gastrointest Surg*. 2010; 14(11): 1758-63.
 25. Falih Noori I. Rectovaginal fistulas, outcomes of various surgical repair and predictive factors of healing success. A retrospective cohort study of 40 cases. *Int J Surg Open*. 2021; 32: 1-6.