




Optimizing Clinical Outcomes of Acute Appendicitis

Cecilia Munguti , Stanley Mugambi , Abdulkarim Abdallah 

¹Department of Surgery, Aga Khan University Hospital, Nairobi, Kenya

Correspondence to: Cecilia Munguti; email: cecmunguti@gmail.com

Received: 17 Aug 2021; Revised: 5 Apr 2022; Accepted: 12 Apr 2022; Available online: 4 May 2022

Abstract

Background: Appendectomy is a common emergency procedure in general surgery. The objective of this study was to identify factors that impact on outcomes following appendectomy for acute appendicitis. **Methodology:** A chart review of all patients with a diagnosis of acute appendicitis who underwent appendectomy at Aga Khan University Hospital between January 2018 and December 2019 was performed. **Results:** Most of the patients (male-to-female ratio, 2:1; mean age, 35±15.6 years) presented with acute uncomplicated appendicitis within an average of 2.98 days from symptom onset. The most common clinical sign was right lower quadrant tenderness. Abdominal ultrasound had a low sensitivity (33%), but computed tomography of the abdomen, which is the preferred imaging modality, had a high sensitivity (93%). The overall complication rate was 10.9%, with no statistically significant difference between open and

laparoscopic appendectomy in terms of duration of surgery, length of hospital stay, and complication rates. The negative appendectomy rate was 6%. **Conclusion:** The complication rates of acute appendicitis in this setting are within international rates, but the negative appendectomy rate remains high. A more accurate interpretation of available imaging modalities is needed to improve this rate.

Keywords: Acute appendicitis, Appendectomy, Patient outcomes.

Ann Afr Surg. 2022; 19(3): 137-143

DOI: <http://dx.doi.org/10.4314/aas.v19i3.2>

Funding: None

© 2022 Author. This work is licensed under the Creative Commons Attribution 4.0 International License.

Introduction

Acute appendicitis is the most common abdominal surgical emergency worldwide, with a lifetime risk of 7%-19% and a mortality rate of 0.3%-1.7%. The incidence is higher in males than in females, with a peak between ages of 10 and 19 years (1).

The diagnosis of acute appendicitis remains a challenge due to variability in clinical presentation (2). On the one hand, missed or delayed diagnosis of acute appendicitis may lead to poor clinical outcome, and on the other hand, a negative appendectomy has been shown to increase patient morbidity, increase risk for adhesive small bowel obstruction, and increase overall healthcare costs (3). Diagnosis based on clinical presentation alone

has pitfalls and has been associated with a negative appendectomy rate of up to 20% (4).

Numerous scoring systems have been formulated to assist clinicians in diagnosing acute appendicitis accurately, albeit with varied sensitivity and specificity, and the Modified Alvarado score is the most commonly used (5, 6). Ultrasound imaging has been proposed as a first-line imaging for patients with a low Alvarado score, but even in such scenarios, ultrasound has been found to be extremely user-dependent and with variably low sensitivity and specificity (7). With the need for more accurate diagnostic modalities, the use of abdominal computed tomography (CT) scan has been investigated,

and studies show a reduction in the negative appendectomy rate to 2% (8).

This is a single-center case series description of demographics, clinical presentation, visual grade, surgical approach, and negative appendectomy rate and a comparison of diagnostic data, management, and outcomes, including the negative appendectomy rate in patients presenting with acute appendicitis over a period of 2 years in a teaching and referral hospital.

Methodology

Ethics statement

Ethical approval was obtained from the ethics and research committee of Aga Khan University Hospital.

Study population

This study included all patients diagnosed with acute appendicitis on histology and imaging at Aga Khan University Hospital, a single tertiary facility, between January 2018 and December 2019.

Data acquisition

A chart review of all patients with a diagnosis of acute appendicitis on histology and imaging was done. Information retrieved included patient age, sex, symptoms and signs, duration of illness, presence of leukocytosis, diagnostic workup, duration to surgery, duration of surgery, surgical approach, and outcomes (length of hospital stay, negative appendectomy rate, and complications).

Operational definition and terms

Symptoms were grouped into peritoneal (abdominal pain, localized or migratory), gastrointestinal (anorexia, nausea, and vomiting), and change in bowel habit (diarrhea or constipation).

The disease severity scoring grading for acute appendicitis was used for visual assessment: grade 1, inflamed; grade 2, gangrenous; grade 3, perforated with free localized fluid; grade 4, perforated with a regional abscess; grade 5, perforated with diffuse peritonitis (9). Radiological descriptive terms used to infer acute appendicitis in this series were *dilated*, *enlarged*, or *thickened appendix* and *fat stranding*. The CT scan

grades based on the radiologist's description of the images were the following: grade 0, normal appendix; grade 1, early uncomplicated with dilatation or fat-stranding; grade 2, local complication with phlegmon or peri-appendiceal fluid; grade 3, regional complication with peritoneal or pelvic fluid or free peritoneal gas.

Histological grades were translated from the pathologist's description of the specimen on microscopy: grade 0, normal appendix (no congestion or mucosal inflammation or ulceration); grade 1, early uncomplicated (mucosal or transmural inflammation); grade 2, local complication (partial necrosis, no perforation); grade 3, complicated (perforated and/or gangrenous).

Statistical analysis

Descriptive statistics were used to analyze the patients' characteristics, clinical symptomatology, and diagnostic and management approaches. The sensitivity and specificity of laboratory investigations and imaging modalities were calculated using the histopathology diagnosis of acute appendicitis as the gold standard. Multivariate analysis was used to determine associations between the management modalities and outcomes.

Results

Patient characteristics

The records of 180 patients with a diagnosis of acute appendicitis were identified. Of 180 patients, 173 underwent surgery, 4 were managed medically with no surgery for an appendicular phlegmon, and 3 were managed with image-guided percutaneous drainage of abscess (Figure 1). Three patients presented with grade 5 appendicitis and underwent a laparotomy and washout, whereas three other patients with a diagnosis of an appendicular phlegmon had a right hemicolectomy. One hundred sixty-seven patients underwent an appendectomy (male, 111, 66%; female, 56, 34%). The overall age range was 6 to 82 years, with a mean of 35 ± 15.6 years (male, 35.2 ± 15.0 years; female, 34.9 ± 16.8 years). The overall peak age was 30 to 40 years (male, 30-40 years; female, 20-40 years; male-to-female ratio, 2:1) (Figure 2). The 167 patients who

underwent a simple appendectomy were subjected to further analysis.

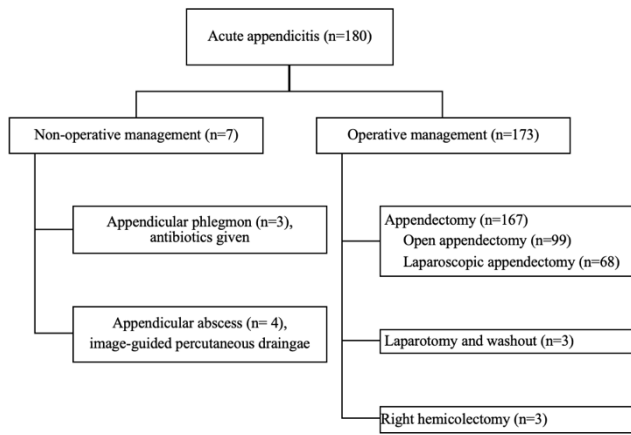


Figure 1. Flowchart of patient management

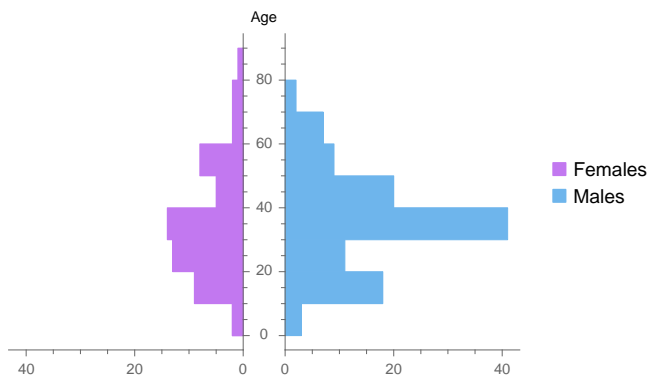


Figure 2. Age and sex distribution

Clinical presentation

Mean duration of symptoms was 2.98 days, with a minimum of 1 day and maximum of 14 days. Most patients presented with peritoneal (local, generalized, or migratory abdominal pain; 177/180, 98.3%) and gastrointestinal symptoms (anorexia, nausea, or vomiting; 120/180, 60%). Most patients did not have fever (136/180) or change in bowel habit (148/180). The most common clinical sign was right lower quadrant tenderness (152, 84%).

The most common of appendicitis score was grade 1, but 21% of the patients presented with grade ≥ 3 . There was no association between disease severity and sex, age, and pre- and in-hospital delay.

Diagnosis assessment

One hundred seventy (94%) of the reviewed cases had a full hemogram, 80% had a kidney function (urea/electrolytes/creatinine) test, and 47% had a urinalysis done. Of the 66 female patients (one of whom had acute appendicitis in her third trimester), only 18 (27%) had a pregnancy test prior to imaging, and all results were negative.

Sixty-four percent of the patients who had full hemogram had increased white cell count. Of the 142 patients with histology-confirmed appendicitis and hemogram at admission, 93 (65.4%) had leukocytosis. The sensitivity of leukocytosis for predicting acute appendicitis was 65.49%, whereas the specificity was 45%.

Thirty-one patients had an ultrasound as index imaging, of whom 10 underwent follow-up CT imaging for equivocal findings. Twenty-one patients had ultrasound as the only imaging done; 1 had a right iliac fossa abscess, which was drained percutaneously; 9 were diagnosed with acute appendicitis and 11 had negative imaging results. All 9 patients with positive imaging results and 9 of the 11 patients with negative imaging results had acute appendicitis on histology. The sensitivity of ultrasound alone was 33%, with specificity of 100%.

Table 1. Comparison of CT scan and histology findings

CT	Grade				Histology	
	0	1	2	3	+ve	-ve
IV contrast only	8	55	1	0	62	2
IV + oral contrast	1	17	1	0	17	2
KUB	4	40	1	1	43	3
Total	13	112	3	1	122	7

CT, computed tomography; IV, intravenous; KUB, kidneys, ureters, and bladder.

Of the 167 patients, 129 (77%) had CT imaging, of which 46 were plain CT of the kidneys, ureters, and bladder, 64 were CT with intravenous (IV) contrast, and 19 were CT of the abdomen with IV and oral contrast (table 1). One hundred sixteen had features of appendicitis, whereas 13 were reported as normal. The overall sensitivity and specificity of CT of the abdomen

for diagnosis of acute appendicitis in this setting were 93% and 28%, respectively.

Management

Of the 167 patients, 99 (59%) were in the open appendectomy group and 68 (41%) were in the laparoscopic appendectomy group. There was no statistically significant difference in age between the groups ($p=0.486$), with the laparoscopy and the open groups having a mean age of 36 and 34.4 years, respectively.

The open group had 69 (69.7%) male patients and 30 (30.3%) female patients. Meanwhile, the laparoscopy group had 42 (62%) male patients and 26 (38%) female patients. The results were not statistically significant ($\chi^2=0.28$, $p=0.710$).

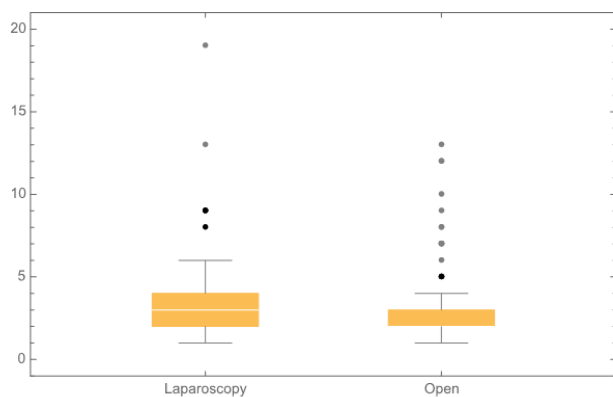


Figure 3. Box and whisker chart for length of stay in open and laparoscopy groups

The overall mean duration from arrival at emergency department to surgery was 6 hours. The time to surgery was longer in the laparoscopy group than in the open group, with a mean duration of 18.7 ± 34 and 9.4 ± 14.4 hours, respectively ($p=0.044$).

The time of surgery was more common at night (66%) than at daytime (34%). The number of laparoscopy cases was 50 at night and 18 during the day, whereas the number of open cases was 38 at night and 61 during the day, respectively.

The mean overall duration of surgery was 81 ± 38 minutes. The average duration of surgery was similar, with 81 ± 41 minutes for the open group and 82 ± 46.5 minutes for the laparoscopy group ($p=0.95$).

Table 2. Types and rates of complications

Complication	Rate
Overall complication rate	17/173 (10.9%)
Open appendectomy rate	12/99 (12%)
Intraabdominal	
abscess	2
Intra-abdominal hematoma	1
Surgical site infection	2
Persistent pain	7
Delayed wound closure	16/99 (16%)
Laparoscopic	
appendectomy rate	5/68 (7.3%)
Intra-abdominal	
abscess	1
Port site hernia	1
Persistent pain	3
Laparotomy rate	2/3 (66%)
Burst abdomen with	
reoperation	1
Surgical site	
infection	1

Outcomes

The length of hospital stay was a minimum of 1 day for both groups, with a mean of 3 ± 2.6 and 3.6 ± 3.0 days for the open and laparoscopy approach, respectively ($p=0.18$) (Figure 3). The overall complication rate was 10.9% (17/173), with a higher complication rate in the open than in the laparoscopic group (12%, 12/99, vs. 7.3%, 5/68) (Table 2). Sixteen (16%) patients who underwent open appendectomy had an open wound with delayed wound closure. The time of day, surgeon's level of experience, type of surgery, or sex was not associated with increased complication rate.

The negative appendectomy rate, calculated from the 167 patients who underwent an appendectomy, was 6% (10/167). Of the 10 patients, 6 had a normal appendix on histopathology, 1 had peri-appendicitis, and 3 had reactive lymphoid hyperplasia. The time of day, type of

surgery, sex, or duration of symptoms was not associated with an increase in negative appendectomy rate.

Discussion

Patient characteristics

In this study, the peak age at presentation was between 30 and 40 years, with a male-to-female ratio of 2:1, which is similar to those of studies in other countries, where young males make up to two-thirds of patients presenting with acute appendicitis (4). The delayed presentation seen in this study was not associated with increased incidence of complications, despite studies demonstrating a higher risk of complications in association with delayed patient presentation to hospital (9, 10).

Diagnosis assessment

Sensitive diagnostic workup is key in timely and appropriate decision making in patients with acute appendicitis. Leukocytosis demonstrated a low sensitivity (66%) in predicting acute appendicitis, and this emphasizes its limitation when used in isolation.

In this series, we observed a minimal use of ultrasound as a first-line modality for diagnosing acute appendicitis. Its low sensitivity, as demonstrated in this study, reflects the results of a systematic review by Giljaca et al., whereby the sensitivity and specificity of abdominal ultrasound for the diagnosis of acute appendicitis were 69% and 81%, respectively (7). The use of a modality that may raise more questions than answers is generally not acceptable in institutions with a low tolerance to delayed/missed diagnosis. An inconclusive ultrasound report will prompt further imaging, hence increasing total costs and delay treatment for the patient. This was the case in 30% of the patients who had initial ultrasound on arrival.

CT of the abdomen appears to be the most favored imaging modality in the diagnosis of acute appendicitis, despite concerns over radiation exposure and increasing medical costs. It demonstrated a reasonable sensitivity but extremely low specificity (28%). Studies have alluded that the sensitivity and specificity of CT of the abdomen may be modified by the level of experience of

the reporting radiologist (11). This could be the case in our setting, as it is an institution with trainees at different levels of experience and specialization reporting the scans.

Management

We observed a significant mean delay in time to surgery in the laparoscopic group, albeit not associated with increased complication rate, which may be explained by the difficulty in scheduling and setting up for laparoscopy surgery. This delay also translated to an increased overall duration of hospital stay. This suggests a need for further training of theater staff in laparoscopic surgery.

Three patients in this series underwent right hemicolectomy; two of whom had a pre-operative diagnosis of acute uncomplicated appendicitis; however, intra-operatively, a mass (phlegmon) was found. In these patients, laparoscopic appendectomy was converted to open right hemicolectomy. The histology report for all 3 patients was an inflammatory mass, which confirmed the diagnosis of an appendicular phlegmon. The recommendation of the European Association of Endoscopic Surgery is to discontinue with surgery in a case with an unexpected finding of an appendicular inflammatory mass, as it is associated with higher complication rates and unnecessary surgery (12).

Outcomes

The overall complication rate was 10.9%, with a clinically but not statistically significantly higher rate in the open group than in the laparoscopic group. Various studies have reported different complication rates in acute appendicitis, which are attributable to the different definition/classification of complications and prevalence of use of pre-operative imaging (13). The main factors associated with complications in literature are complicated appendicitis, age >70 years, and conversion from laparoscopic to open appendectomy. The multivariate analysis in this study did not demonstrate any statistically increased association of complication with duration of surgery, level of expertise, type of surgery, sex, or duration of symptoms.

Delayed wound closure, a common practice in this institution (16% in the open appendectomy group) has been purported to reduce surgical site infection rates. However, this practice is associated with extended hospital stay and increased hospital visits and overall cost of treatment (14).

There was no difference in the rate of intra-abdominal collections in the open and laparoscopic groups. A higher rate of intra-abdominal abscess post-laparoscopic appendectomy in earlier studies has been attributed to inappropriate intra-abdominal lavage (15, 16).

Laparoscopic appendectomy, the procedure of choice, has been shown have better patient outcomes such as reduced duration of hospital stay, lower pain intensity post-operatively, reduced surgical site infection, and better cosmetic outcome (16), as reflected in this study.

Negative appendectomy rate

Negative appendectomy rate varies greatly among centers. A recent study from Tanzania demonstrated a negative appendectomy rate of 38% (17). A negative appendectomy rate has economic, and health implications, with cost incurred for unnecessary surgery, persistent symptoms, longer duration of hospital stay, possible litigation, incisional hernia, adhesions, sepsis, bowel obstruction, and death (18). The negative appendectomy rate in this setting was low at 6%, but there is room for improvement.

Conclusion

There is a need for sensitive and specific diagnostic modalities to guide appropriate management of acute appendicitis. There is also constant need to re-educate and retrain clinicians in order to improve patient outcomes and reduce negative appendectomy rates. Laparoscopic appendectomy appears to be a safe procedure, with lower complication rates.

Recommendation

This study is limited by the short duration of follow-up and the use of medical records to determine long-term outcomes and complications. A prospective study would be ideal to identify long-term outcomes such as adhesive

small bowel obstruction and incisional hernia following management of acute appendicitis.

Conflict of interest

None to disclose

Author contributions

All authors contributed equally to writing and editing the original draft.

References

1. Rockson SG and Rivera KK. Estimating the population burden of lymphedema. *Ann N Y Acad Sci.* 2008;1131(1):147–154.
2. Hadamitzky C, Pabst R, Gordon K, et al. Surgical procedures in lymphedema management. *Journal of Vascular Surgery: Venous and Lymphatic Disorders.* 2014; 2(4), 461–468.
3. Allen RJ and Cheng MH. Lymphedema surgery: patient selection and an overview of surgical techniques. *J Surg Oncol.* 2016;113(8):923–931.
4. Avraham T, Yan A, Zampell JC, et al. Radiation therapy causes loss of dermal lymphatic vessels and interferes with lymphatic function by TGF-beta1-mediated tissue fibrosis. *Am J Physiol Cell Physiol.* 2010; 299:589–605.
5. Zampell JC, Yan A, Elhadad S, et al. CD4(b) cells regulate fibrosis and lymphangiogenesis in response to lymphatic fluid stasis. *PLoS ONE.* 2012; 7(11):e49940.
6. Cuzzone DA, Weitman ES, Albano NJ et al. IL-6 regulates adipose deposition and homeostasis in lymphedema. *Am J Physiol Heart Circ Physiol.* 2014; 306:1426–1434.
7. Tobin MB, Lacey HJ, Meyer L, et al. The psychological morbidity of breast cancer-related arm swelling. *Cancer.* 1993; 72(11):3248–3252.
8. De Godoy JMP, Braile DM, de Fatima GM, et al. Quality of life and peripheral lymphedema. *Lymphology.* 2002; 35:72–75.
9. McWayne J and Heiney SP. Psychologic and social sequelae of secondary lymphedema: a review. *Cancer.* 2005; 104(3):457–466.
10. Aurora M, Kareh MD, Kyle Xu, et al. Surgical Management of Lymphedema. *Mo Med.* 2020; 117(2): 143–148.
11. Grada A and Phillips T. Lymphedema. *Journal of the American Academy of Dermatology.* 2017; 77(6), 995–1006.
12. Salgado CJ, Sassu P, Gharb BB, et al. Radical reduction of upper extremity lymphedema with preservation of perforators. *Ann Plast Surg.* 2009; 63(3):302–6.
13. Pitcher A, Pagan C, Kelvin S, et al. Excision of Elephantiasis Nostras Verrucosa Lesions in a Patient

- With Hereditary Lymphedema: Case Report and Review of the Literature. *The Journal of Foot and Ankle Surgery*. 2015; 54(4), 747–750.
14. Fumiya I, Kazuko C, Sato-Matsumura, et al. Elephantiasis Nostras Verrucosa Successfully Treated by Surgical Debridement. 2014; 30(6), 939–941.
 15. Narushima M, Mihara M, Yamamoto Y, et al. The intravascular stenting method for treatment of extremity lymphedema with multiconfiguration lymphaticovenous anastomoses. *Plast Reconstr Surg*. 2010; 125(3):935-43.
 16. Patel KM, Lin CY, Cheng MH, et al. A Prospective Evaluation of Lymphedema-Specific Quality-of-Life Outcomes Following Vascularized Lymph Node Transfer. *Ann Surg Oncol*. 2015; 22, 2424–2430.
 17. Althubaiti GA, Crosby MA, Chang W, et al. Vascularized Supraclavicular Lymph Node Transfer for Lower Extremity Lymphedema Treatment. *Plastic and Reconstructive Surgery*. 2013; 131(1):133e-135e.
 18. Raju A and Chang DW. Vascularized Lymph Node Transfer for Treatment of Lymphedema. A Comprehensive Literature Review. *Annals of Surgery*. 2015; 261(5): 1013-1023.
 19. Van der Walt JC, Perks TJ, Zeeman BJ, et al. Modified Charles procedure using negative pressure dressings for primary lymphedema: a functional assessment. *Ann Plast Surg*. 2009; 62(6): 669-75.
 20. Chen SH, Cem Yildirim ME, Mousavi SA, Chen HC. Long-term functional outcomes upon application of split-thickness skin graft around major joints in HCC (Hung-Chi Chen)-modified Charles' procedure for advanced lymphedema. *Asian J Surg*. 2021; 44(1):169-173.