

# Perineal Repair of a Postoperative Perineal Hernia – Case Report

Seke Manase Ephraim Kazuma <sup>1</sup>, Kazi Mufaddal <sup>1</sup>, Vivek Sukumar <sup>1</sup>, Avanish Saklani <sup>1</sup>

<sup>1</sup>Department of Colorectal Surgical Oncology, Tata Memorial Hospital, Mumbai, Parel, India

**Correspondence to:** Prof. Avanish Saklani. Email: [asaklani@hotmail.com](mailto:asaklani@hotmail.com)

Received: 21 May 2021; Revised: 06 Dec 2021; Accepted: 14 Dec 2021; Available online: 5 Feb 2022

## Summary

Postoperative perineal hernia (PerH) following abdominoperineal resection is a rare complication of radical pelvic oncologic surgery performed with curative intent for rectal cancer, with a reported prevalence of 0.6–7%. PerH is clinically diagnosed as an occurrence of a swelling in the perineum caused by the herniation of abdominal or pelvic viscera through a defect in the pelvic floor. The definitive repair method of pelvic floor defect of PerH is not established but includes exclusion of tumor recurrence and repair of pelvic floor defect. We herein report the treatment of a PerH using a combination of biological mesh and a V-Y

gluteal fascio-cutaneous advancement flap, performed at Tata Memorial Hospital, in Parel, Mumbai, India.

**Keywords:** Perineal hernia, V-Y flap, Biological mesh, Extra levator abdominoperineal excision, ELAPE

Ann Afr Surg. 2022; 19(2): 116-120

**DOI:** <http://dx.doi.org/10.4314/aas.v19i2.9>

**Funding:** None

© 2022 Author. This work is licensed under the Creative Commons Attribution 4.0 International License.

## Introduction

Postoperative perineal hernia (PerH) following abdominoperineal resection (APR) was first reported by Yeomans in 1939 (1); it is a rare complication of radical pelvic oncologic surgery for rectal cancer, with a reported prevalence of 0.6–7% (2, 3). PerH is clinically diagnosed as an occurrence of a swelling in the perineum caused by the herniation of abdominal or pelvic viscera through a defect in the pelvic floor (2, 4, 5). The hernial sac may contain bowel (commonly small bowel), urinary bladder, uterus, or omentum. APR is performed for low rectal cancer involving the levator ani muscles and external anal sphincter (2). Low rectal cancer is locally advanced at presentation and is treated with neoadjuvant radiotherapy and radical surgery to achieve oncologically negative margins; hence, rectal cancer survivors have a chance at cure or a long disease-free survival or overall survival (3, 6).

Although the cause of PerH is unknown, it has been observed to occur after neoadjuvant radiotherapy, perineal wound complications, and damage and/or loss

of the pelvic floor (2). Symptomatic, reducible, and non-complicated perineal hernia requires surgical treatment, which can be performed with a perineal approach in which the hernia is repaired by placement of a composite mesh (2, 5, 7).

We report a case of uncomplicated PerH that was managed in the Department of Colorectal Surgical Oncology at Tata Memorial Hospital, in Parel, Mumbai, India.

## Case presentation

A 57-year-old woman with no comorbidities presented with non-metastatic rectal cancer on August 1, 2018. Biopsy revealed moderately differentiated adenocarcinoma of the rectum, and magnetic resonance imaging (MRI) showed that the tumor was in the lower rectum, involving the levator ani and external anal sphincter with suspicious right pelvic nodes. The patient received neoadjuvant chemoradiotherapy, and after completion, she was evaluated by a multidisciplinary

committee comprising surgical, medical, radiation oncologists, a radiologist, and an intervention radiologist.

An open extralevator abdominoperineal excision (ELAPE) with a right pelvic nodal excision was performed. Histopathology showed that the resection had negative margins and that all nodes were negative for metastasis.

The patient received five cycles of adjuvant chemotherapy (capecitabine and oxaliplatin).

The follow-up findings in 2019 (colonoscopy, carcinoembryonic antigen, and contrast-enhanced

computerized tomography scan) were normal. However, the patient presented with a perineal hernia and parastomal hernia during a follow-up visit with non-specific symptoms, and she wanted it operated on. Figure 1 shows the perineal hernia and MRI results. MRI confirmed perineal hernia without evidence of tumor recurrence.

The patient’s perineal hernia was repaired on November 26, 2020, as shown in Figures 2 and 3. Postoperative recovery was uneventful.

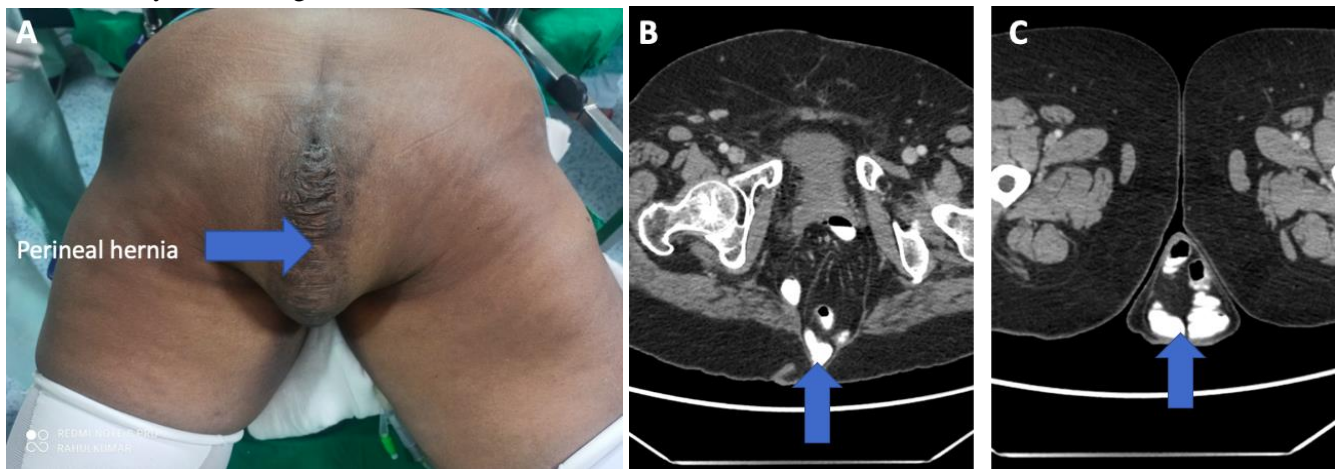


Figure 1. A) large perineal hernia, shown by arrow. B) MRI image showing herniation between gluteal maximus muscles, shown by arrow. C) Hernia sac at the level of upper femur, shown by arrow.

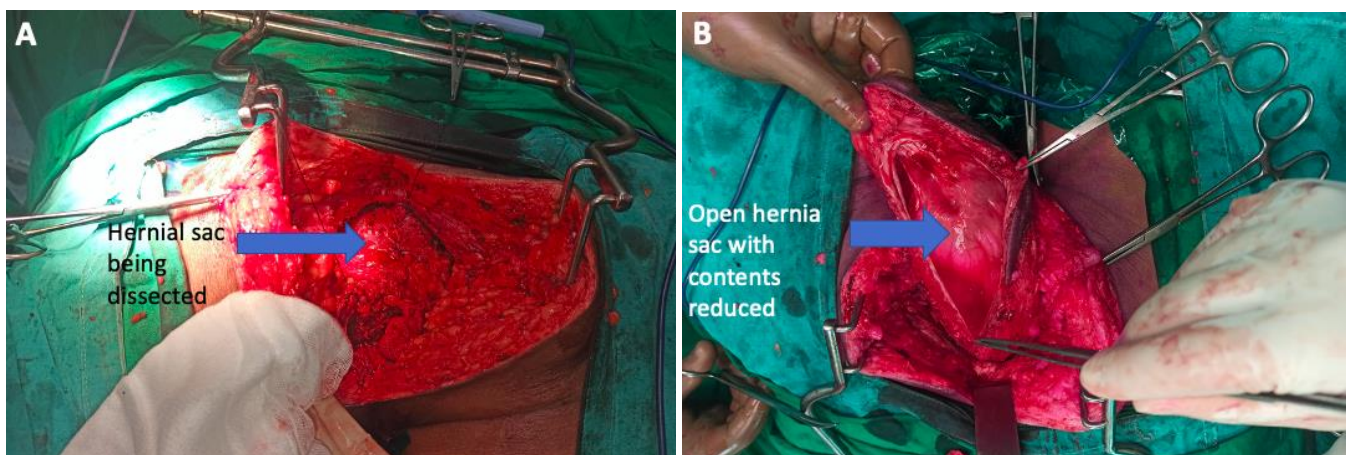


Figure 2. A) Mobilization of hernia sac after incising and excising excess skin B) Reduction of hernia content, inspection for recurrence and closure of hernia sac.

The following operative steps summarize the procedure.

1. The patient was placed on prone position, under general anesthesia, with endotracheal intubation as shown in Figure 4.
2. A perineal elliptical incision was made to include the previous perineal incision and redundant skin (Figure 5).
3. The perineal skin was dissected off the hernial sac.
4. The hernial sac was opened; it was non-adherent, and the herniated small bowel was carefully reduced.
5. The hernial sac was re-adjusted and closed.

6. Composite mesh was laid on and fixed around the pelvic bones and soft tissues.

7. A bilateral V-Y gluteal fascio-cutaneous advancement flap was sutured on to cover the defect and reinforce the mesh (Figure 3).

8. The skin was closed in layers.

9. Parastomal hernia was repaired in the same sitting.

The patient's recovery was uneventful, and she was discharged 7 days later. Histopathology of the specimen confirmed that specimen was free of tumor and that there was no tumor recurrence.

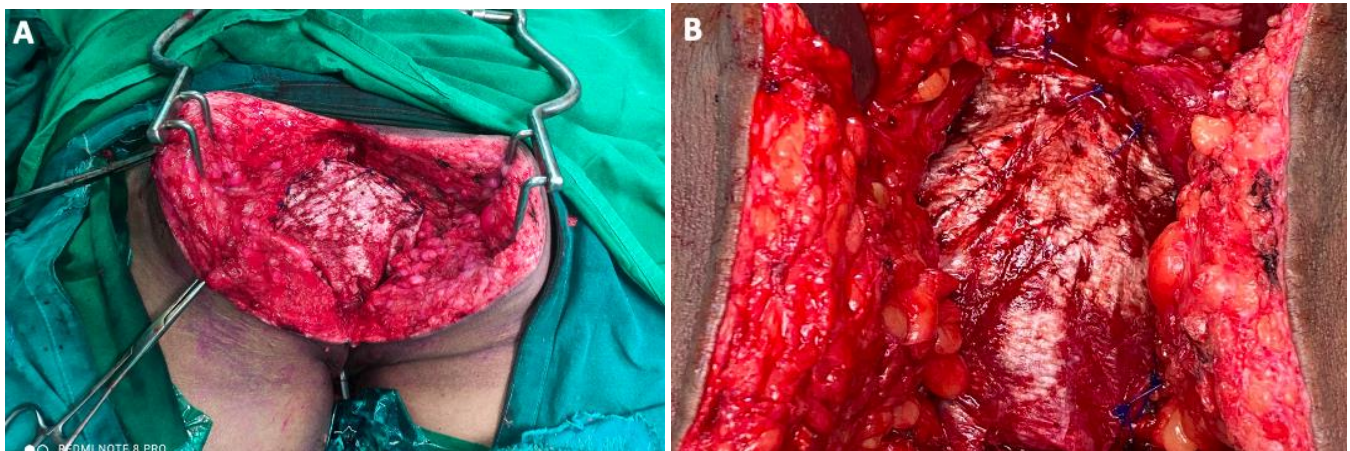


Figure 3. A) and B) Mesh fixed to pelvic bones laterally, posterior vagina anteriorly and sacrum posteriorly.

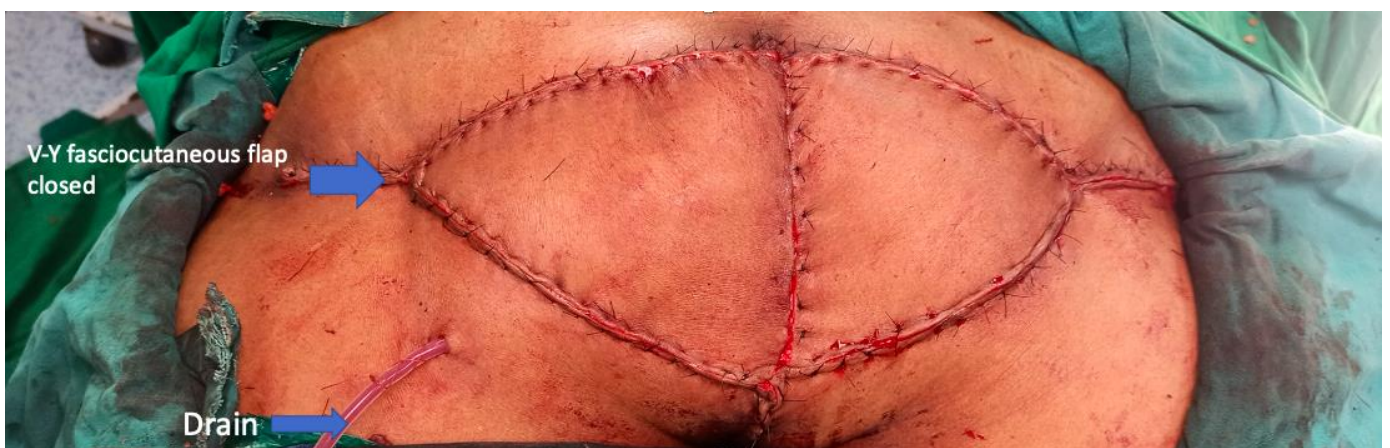

Figure 4: showing V-Y gluteal fasciocutaneous flap closure of a biological mesh repair. Drain left in situ.

The patient's 3-month follow-up was uneventful, without wound complications. The patient provided written informed consent for this case report.

### Discussion

There is no definitive repair method for perineal hernia; therefore, repair depends on the surgical techniques used in the repair of pelvic floor defects and exclusion of tumor recurrence (5, 8). Wide and radical oncologic resections are performed to achieve the benefit of improved oncologic outcomes and to avoid positive margins and tumor perforation (2). Risk factors for the development of PerH in our patient included female sex, ELAPE, and neoadjuvant radiotherapy (3). Female sex has been shown to be a risk for the development of PerH due to the presence of a wide pelvis (2, 5). ELAPE is also a recognized risk for the development of PerH due to the large pelvic defect that this surgery leaves behind (2).

The large pelvic floor defect that results from ELAPE may be a challenge to close; hence, several techniques have been described to close the pelvic defect and to reduce the occurrence of postoperative PerH (2, 9). Despite many techniques described to close the pelvic defect, none is more established than other pelvic floor reconstruction methods (2, 5). The approach to the reconstruction of the pelvic floor after PerH can be abdominal, perineal, or abdominoperineal, and none of these approaches has been established as a recommended repair method superior to others (2, 6, 7). In the perineal approach, the abdomen is not entered, and excluding a tumor recurrence can be performed with the help of imaging and monitoring of tumor trend through follow-up with clinical details, tumor markers, and imaging (10). The perineal approach is preferred for simple and uncomplicated PerH, as was the case with our patient (10).

Reconstruction of the pelvic floor can be performed with perineal repair, with or without mesh and use of myocutaneous flaps or gluteal fascio-cutaneous flaps (2, 5). The mesh that is used in perineal repair may be synthetic or biological (2).

Synthetic mesh promotes fibroblast activity and foreign body reaction in the reconstructed perineum, resulting in the formation of rich collagen tissue or scar tissue that supports the reconstructed pelvic floor (5, 10, 11). Biological mesh has an acellular collagen matrix that causes a migration of fibroblast into the mesh and neovascularization with recruitment of neighboring tissues; biological mesh can be used in the presence of infection, and it also reduces the risk of postoperative wound infection; hence, it has become more popular than synthetic mesh (2). Our patient had a combination of biological mesh and a V-Y gluteal fascio-cutaneous flap. This approach has been shown to reduce the recurrence of hernia repair (8, 12). The hernia repair in our patient was uneventful.

Biological PerH repair has gained popularity in the repair of complex perineal wounds due to its usefulness in infected fields; however, its cost can be prohibitive.

### Conclusion

VAGM is a rare condition which if left untreated has dismal survival rates. Early recognition, intensive medical treatment with timely endovascular embolization profoundly modifies the outcome in these children. These effective treatment options should be made available to selected patients.

### Declaration of interests

The authors declare no conflict of interest.

### Author contributions

SMEK authors contributed equally in writing and editing of the original draft.

### References

1. Yeomans FC. Levator hernia, perineal and pudendal. *Am Surg.* 1939; 43: 695-7.
2. Narang SK, Alam NN, Köckerling F, et al. Repair of perineal hernia following abdominoperineal excision with biological mesh: a systematic review. *Front Surg.* 2016; 3: 49.
3. Musters GD, Bemelman WA, Bosker RJI, et al. Randomized controlled multicentre study comparing biological mesh closure of the pelvic floor with primary perineal wound closure after extralevator

- abdominoperineal resection for rectal cancer (BIOPEX-study). *BMC Surg.* 2014; 14(1): 1-7.
4. Kunduz E, Bektasoglu H, Yigman S, et al. Transvaginal small bowel evisceration following abdominoperineal resection. *Case Rep Surg.* 2018; 39: 1-3.
  5. Lee TG, Lee SJ. Mesh-based transperineal repair of a perineal hernia after a laparoscopic abdominoperineal resection. *Ann Coloproctol.* 2014; 30(4): 197-200.
  6. Rajabaleyan P, Dorfelt A, Poornoroozy P, et al. Robot-assisted laparoscopic repair of perineal hernia after abdominoperineal resection: a case report and review of the literature. *Int J Surg Case Rep.* 2019; 55: 54-7.
  7. Mjoli M, Sloothaak DAM, Buskens CJ, et al. Perineal hernia repair after abdominoperineal resection: a pooled analysis. *Color Dis.* 2012; 14(7): 400-6.
  8. Blok RD, Brouwer TPA, Sharabiany S, et al. Further insights into the treatment of perineal hernia based on the experience of a single tertiary centre. *Color Dis.* 2020; 22(6): 694-702.
  9. Alobuia WM, Laryea JA. Perineal hernia repair with mesh and gluteal myocutaneous flap after abdominoperineal resection for rectal cancer: a case report. *Ann Case Rep.* 2018; 3: 1-3.
  10. Dulucq JL, Wintringer P, Mahajna A. Laparoscopic repair of postoperative perineal hernia. *Surg Endosc Other Interv Tech.* 2006; 20(3): 414-8.
  11. Martijnse IS, Holman F, Nieuwenhuijzen GAP, et al. Perineal hernia repair after abdominoperineal rectal excision. *Dis Colon Rectum.* 2012; 55(1): 90-5.
  12. Reports C, Edwards SB, Agnew J, et al. Clinical and medical repair of acquired perineal hernias in abdominoperineal excision: a hybrid technique and literature review. *Clin Med Case Rep.* 2016; 2(8): 1-9.