

Cecal Volvulus in Malrotation at 41 years

Kabongo Kizito Mulamba Changachanga¹ , Mbewe Charles², Lupasha Mwila^{3,4}

¹School of Medicine, University of Zambia, Lusaka, Zambia

²University Teaching Hospital, Lusaka, Zambia

³University Teaching Hospital, Lusaka, Zambia

⁴School of Medicine, University of Zambia, Lusaka, Zambia

Correspondence to: Dr. Kabongo Mulamba Kizito Changachanga; email: kizitomc@yahoo.co.uk

Received: 23 Mar 2021; Revised: 06 Jul 2021; Accepted: 12 Jun 2021; Available online: 07 Aug 2021

Summary

Cecal volvulus is rare, and its preoperative diagnosis poses a challenge. Because of its variable clinical features, the ultimate diagnosis of cecal volvulus is determined during surgery. We aim to demonstrate the rarity of cecal volvulus, the challenge in preoperative diagnosis of cecal volvulus, and the use of surgery in both diagnosis and treatment. We herein present a case of ischemic cecal volvulus in a 41-year-old man who presented within 5 hours of onset of symptoms of abdominal pain, vomiting, and lower abdominal distension. He had not passed flatus or opened bowels for a day. The available abdominal radiographs did not reveal preoperative cecal volvulus. An emergency laparotomy was performed, and it showed ischemic

anticlockwise cecal volvulus that was managed by right hemicolectomy plus ileo-transverse primary anastomosis and transverse colopexy. The post-operative recovery and follow-up were uneventful.

Keywords: Cecal volvulus, cecopexy, transverse colopexy

Ann Afr Surg. 2021; 18(4): 252-257

DOI: <http://dx.doi.org/10.4314/aas.v18i4.12>

Conflicts of Interest: None

Funding: None

© 2021 Author. This work is licensed under the Creative Commons Attribution 4.0 International License

Introduction

Cecal volvulus is relatively uncommon and involves rotation of the cecum, terminal ileum, or ascending colon around its mesenteric axis (1,2). It accounts for <2% of all intestinal obstructions (3) and approximately 10–60% of all colonic volvulus(4). Management of cecal volvulus includes non-operative colonoscopic reduction and operative approach via laparotomy or laparoscopy (1,2). Surgery is commonly performed as an emergency procedure and could involve detorsion plus cecopexy or bowel resection depending on the viability of the intestines (2,5). However, there is paucity of data on transverse colopexy after right hemicolectomy.

We herein report a case of acute cecal volvulus due to midgut malrotation that was treated with right hemicolectomy and transverse colopexy. With this case, we aimed to highlight the infrequency of cecal volvulus, the challenge in preoperative diagnosis of cecal volvulus, and the role of surgery in both diagnosis and treatment.

Case presentation

In February 2020, a 41-year-old man presented to the Surgery Department of the University Teaching Hospitals as a referral from Kafue Gorge Hospital for further management. He presented within 5 hours of onset of symptoms of abdominal pain, vomiting, and

lower abdominal distension. He had not passed flatus or opened bowels for a day. He did not have a fever or urinary symptoms. Nine years earlier, he was diagnosed with peptic ulcer disease, which was confirmed via upper endoscopy and managed uneventfully. He had no history of surgery since childhood.

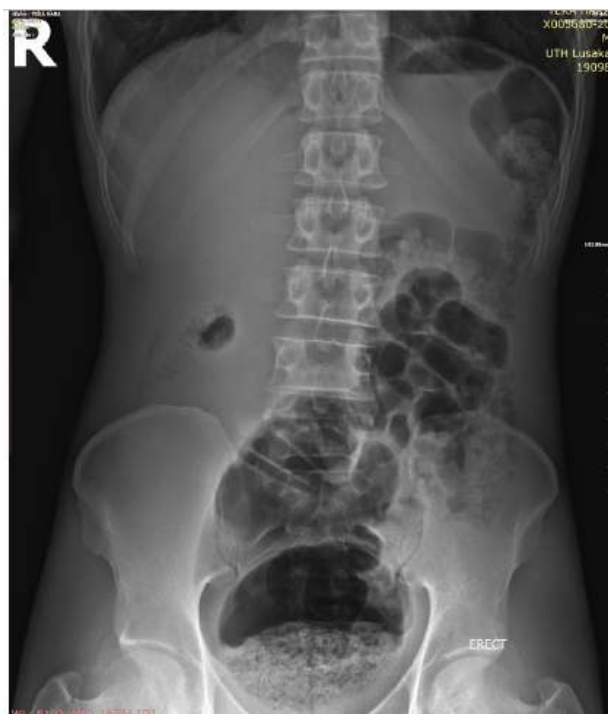

Figure 1. Erect abdominal x-ray showing distended loop of large bowel on the left and lower abdomen with no air-fluid levels.

On examination, the general condition was good. He was afebrile and hemodynamically stable. The abdomen was soft and mildly tender in the right iliac fossa. It was distended in the suprapubic region and had reduced bowel sounds. There was no evidence of peritonitis. The digital rectal examination revealed stool in the rectum and a tender anterior rectal wall bulge. The hemogram was normal, except for neutrophilia of 82.8%. The kidney and liver tests were essentially normal. The plain abdominal radiographs showed dilated gas-filled loops of the large intestine in the left upper quadrant and center of the abdomen with no air-fluid levels (Fig. 1).

His urinary bladder was catheterized, and a nasogastric tube was also placed. He was resuscitated with intravenous fluids aside from receiving intravenous

antibiotics and analgesia. He underwent an emergency exploratory laparotomy which revealed non-distended small bowels on the right side and large bowels on the left side of the abdomen. The appendix appeared abnormally long. The cecum was dilated, ischemic, and twisted in an anticlockwise fashion in the suprapubic region (Fig. 2).

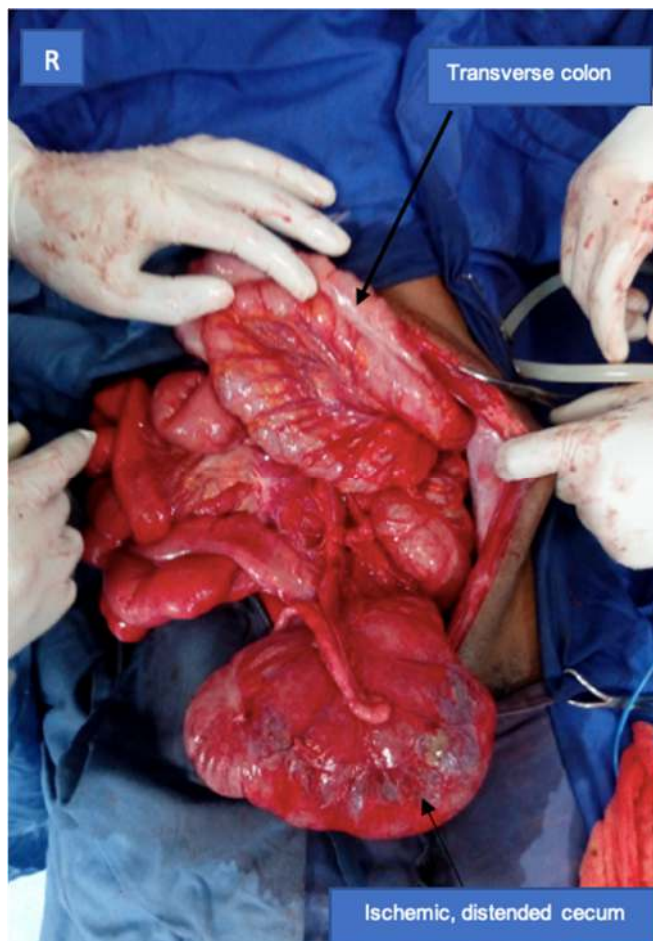


Figure 2. Ischemic and distended cecum.

The cecum and ascending colon were not in the right gutter and were freely mobile just like the transverse colon (Fig. 3). The duodenum did not cross the midline. There were bands over the duodenum and between the loops of the large bowel. The duodenum and pancreas were abnormally visible, and the stomach appeared elongated (Fig. 4).

The Ladd's bands were divided, and right hemicolectomy (included appendicectomy) plus an end-to-end primary ileo-transverse anastomosis with Vicryl

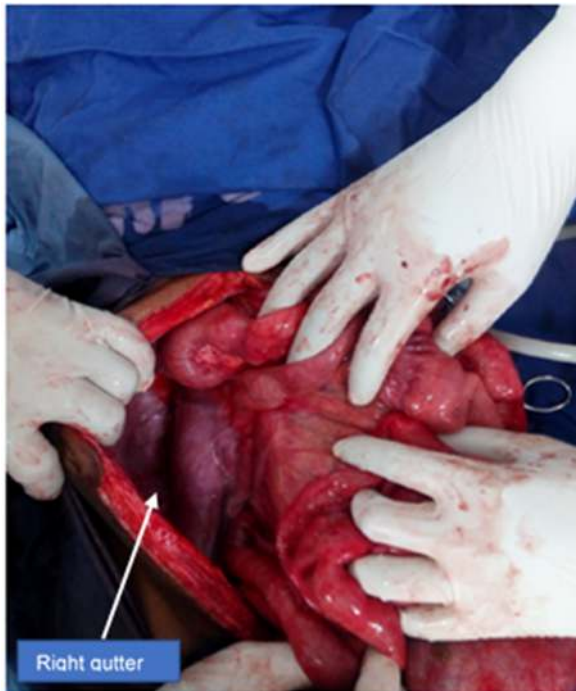

Figure 3. Cecum and ascending colon not fixed in the right gutter.

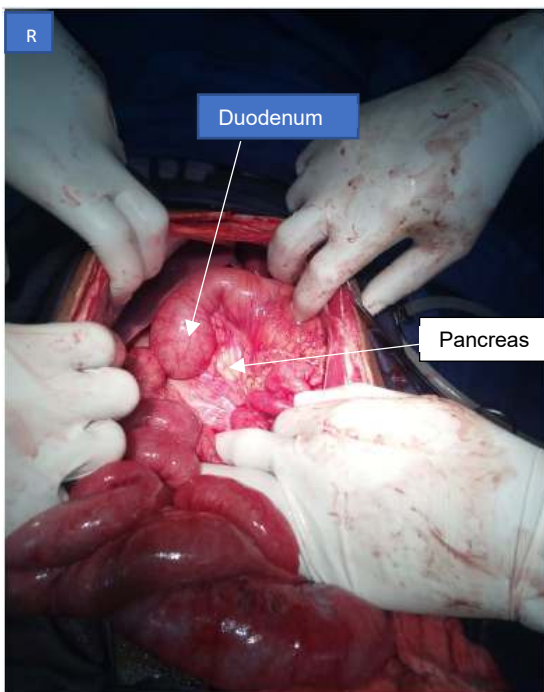


Figure 4. Visibly duodenum and pancreas.

2-0 in two layers was performed. Counterclockwise detorsion plus transverse colopexy to the right abdominal wall using Vicryl suture was also performed. The post-operative course was uneventful. The patient

was discharged home on the fifth day after surgery, and the follow-up at 11 months was uneventful.

Discussion

Cecal volvulus is an infrequent cause of intestinal obstruction. Although the patient presented with features of intestinal obstruction, it was difficult to make a preoperative conclusive diagnosis of cecal volvulus using the clinical picture and available investigations. Therefore, the ultimate diagnosis of cecal volvulus was made at laparotomy.

Cecal volvulus accounts for <2% of all intestinal obstructions (3). A review of 60 patients at St. Francis Hospital in Kampala, Uganda, revealed that ileocecal volvulus accounted for 1.6% of all intestinal volvulus (6). For colonic volvulus, cecal volvulus is second to sigmoid volvulus (7). A systematic review of cecal volvulus demonstrated the age range from 14 to 91 years (mean, 51.6 years) (8). It has been reported to be more common in young female patients, but some series show no sex predominance (3). Furthermore, our patient was male and within the age range. There are two major types of cecal volvulus: the classic loop ileocolic volvulus (~90%) and the cecal bascule (~10%) (4). The ileocolic volvulus is further described in terms of rotation of the cecum as clockwise or anticlockwise, which is the most common form.

Cecal volvulus requires a high index of suspicion, as the clinical features are vastly variable (4) (table 1). In adults, acute abdominal pain is the most common complaint (9,10). Other features include abdominal distension, nausea, vomiting, and obstipation (9,11,12). Adults with a chronic picture present with chronic intermittent abdominal pain, nausea, and vomiting over several days or months (5,10). The cecum spontaneously twists and untwists, making it difficult to establish a preoperative diagnosis of cecal volvulus. Patients with nonspecific clinical features and suspected to have cecal volvulus should undergo investigations such as colonoscopy, barium enema, abdominal computed tomography (CT) scan, or surgery (2,13).

The diagnosis of cecal volvulus can be established using radiological investigations. However, in our case, the challenge was the impaired ability to make the

preoperative diagnosis of cecal volvulus based on the clinical presentation and available investigations or radiographs. The plain erect abdominal radiograph did not show air-fluid levels. The plain abdominal radiographs are deficient in making a definitive diagnosis in cecal volvulus in 50–85% of cases (4,7). The investigation of choice is the abdominal CT scan, and it shows the presence and location of the volvulus (1,10). A multidetector CT scan can ascertain acute cecal pathologies (12,14). It can reveal potentially fatal complications such as bowel necrosis and perforation (12). In the present case, we had no access to the costly modality of choice, i.e., abdominal CT scan, and the diagnosis of ischemic cecal volvulus was made intraoperatively. Colonoscopy can be employed for both diagnostic and therapeutic purposes. Endoscopic reduction is influenced by the patient's stability and condition of the bowel wall. There is a risk of colonic perforation and unsuccessful reduction (1).

The causes and risk factors of cecal volvulus are multifactorial. Our patient had midgut malrotation that was asymptomatic since childhood, except for the associated peptic ulcer disease, which was treated. Adult presentation of midgut malrotation is uncommon and occurs in 0.2–0.5% of cases, as the majority present within the first year of life (15). The untreated congenital anomaly could have predisposed our patient to cecal volvulus. In patients with intestinal malrotation, the most common cause of intestinal obstruction is midgut volvulus (10). Cecal volvulus has also been documented secondary to carcinoma of the colon, adhesions, chronic constipation, previous surgery, spilled gallstones post laparoscopic cholecystectomy, incisional hernia, and endometriosis (1,12,13,16).

Surgery is the mainstay of the management of cecal volvulus and can be performed electively or during emergency (1,2,13,16). It can be performed either via an open or laparoscopic approach. However, non-operative options for cecal volvulus, include enema reduction and colonoscopic reduction, which has been associated with high recurrence and failure rate (4,13). In complicated cecal volvulus where there is ischemia, gangrene, or perforation, endoscopic reduction is abandoned, and operative intervention is performed.

For cecal volvulus with bowel necrosis/gangrene or perforation, surgical resection is undertaken (4,11). The surgical options at laparotomy include bowel resection plus primary anastomosis, cecopexy, and cecostomy, depending on the intraoperative findings and hemodynamic stability of the patient (13,17) (table 1). Cecopexy is recommended in cecal volvulus with viable bowel and is associated with a recurrence rate of 8.8% and a morbidity rate of 0–8% (8,18). Detorsion and cecopexy can be performed by either laparoscopic or open approach (8,19).

The Ladd's procedure is used to treat midgut malrotation. The procedure classically involves dividing the Ladd's bands overlying the duodenum, widening of the narrowed root of the small bowel mesentery, dividing the adhesions around the superior mesentery artery, counterclockwise detorsion of the midgut, and appendicectomy (10). Ladd described this procedure for pediatric patients, and not all components of the classic Ladd's procedure may be achieved in adults. In our patient who had cecal volvulus, the Ladd's bands were divided and right hemicolectomy plus an end-to-end primary ileo-transverse anastomosis (included appendicectomy) and counterclockwise detorsion plus transverse colopexy were performed. We did not perform a cecopexy, as the cecum was ischemic and there was a risk of colonic perforation, which has been associated with mortality and morbidity. After bowel resection and primary anastomosis, a transverse colopexy was performed to reduce the recurrence of colonic volvulus (4). Transverse colopexy has been documented as a treatment option in acute transverse colon volvulus (18).

We presented a rare case of ischemic cecal volvulus that was diagnosed at laparotomy and managed by bowel resection and transverse colopexy. The preoperative diagnosis of cecal volvulus is infrequently attained, and surgery is both diagnostic and therapeutic.

Acknowledgment

The authors thank the Surgery Department of the University Teaching Hospitals for the guidance and support.

Table 1. Publications on cecal volvulus

AUTHOR(S), YEAR, COUNTRY	PRESENTATION	PROCEDURE	COMMENT /RISK
Mwita C, Muthoka J, Kanina P, et al., 2014, Kenya	Male, 16 years old, presented with 6-hour right lower abdominal pain	Laparotomy: viable cecum Right hemicolectomy plus ileo-transverse anastomosis	No transverse colopexy No risk noted
Solis Rojas C, Vidrio Duarte R, García Vivanco DM, et al., 2020, Mexico	Female, 52 years old, 1-day diffuse abdominal pain, 3-day obstipation	Laparotomy: necrotic cecum Right hemicolectomy with a side-to-side ileo-transverse anastomosis	No colopexy Previous surgery
Morris MW, Barker AK, Harrison JM, et al., 2013, USA	Female, 71 years old, 1-day diffuse abdominal pain, nausea, and vomiting	Laparotomy: gangrenous cecum Ileocectomy damage control Anastomosis after 1 day	No colopexy Spilled gallstones during laparoscopic cholecystectomy
Ito D, Kaneko S, Morita K, et al., 2015, Japan	Female, 41 years old, 14-day intermittent right lower quadrant abdominal pain	Colonoscopic reduction plus elective laparoscopic ileocectomy of viable cecum	No colopexy Endometriosis
Alghamdi HM, AlShammary S, Lardhi H, et al., 2018, Saudi Arabia	Female, 36 years old, 6-hour severe abdominal pain	Laparotomy: viable cecum Right hemicolectomy, Roux-en-Y gastric bypass	No transverse colopexy Post-gastric bypass
Ting YY, Farfus A, Trochsler M, 2020, Australia	Female, 70 years old, 3-day colicky abdominal pain-associated obstipation and vomiting	Laparotomy: viable cecum Limited ileocectomy plus ileostomy	No colopexy Large ventral hernia Prior abdominal surgery
Pencle F, 2017, USA	Male, 71 years old, 5-day increasing abdominal girth, passed flatus intermittently	Laparotomy: viable cecum Cecopexy	No transverse colopexy No bowel resection
Pulvirenti E, Palmieri L, Toro A, et al., 2010, Italy	Female, 41 years old, 1-day abdominal pain, nausea, vomiting and constipation	Laparotomy: viable cecum Cecopexy	No transverse colopexy Adhesions
Sage MJ, Younis J, Schwab KE, et al., 2012, UK	Female, 25 years old, 3-day abdominal pain, distension, and absolute constipation	Laparotomy: viable transverse colon Transverse colopexy	Transverse colopexy Malfixation of mesentery /attachment
Ramírez-Ramírez MM, Villanueva-Sáenz E, Ramírez-Wiella-Schwuchow G, 2016, Mexico	Female, 54 years old, 4-hour abdominal distension, lower right quadrant pain, nausea, vomiting, constipation and obstipation	Colon enema reduction then 2-week selective laparoscopic right hemicolectomy (viable cecum)	No transverse colopexy Chronic constipation

References

1. Ito D, Kaneko S, Morita K, et al. Cecal volvulus caused by endometriosis in a young woman. *BMC Surg.* 2015;15(1):77.
2. Pulvirenti E, Palmieri L, Toro A, et al. Is laparotomy the unavoidable step to diagnose caecal volvulus? *Ann R Coll Surg Engl.* 2010;92(5):e27-9.
3. Le CK, Nahirniak P, Anand S, et al. Volvulus. In: *StatPearls* [Internet]. Treasure Island, FL: StatPearls Publishing; 2020. Available from: <http://www.ncbi.nlm.nih.gov/books/NBK441836/> [cited Feb 5, 2021].
4. Hasbahceci M, Basak F, Alimoglu O. Cecal volvulus. *Indian J Surg.* 2012;74(6):476-9.
5. Mwita C, Muthoka J, Kanina P et al. Caecal volvulus in an adolescent African male: a case report and brief review of the literature. *Pan Afr Med J.* 2014;17:92.
6. Kakande I, Ekwaro L, Obote et al. Intestinal volvulus at St Francis Hospital, Kampala. *East Cent Afr J Surg.* 2001;6. Available from: <https://www.ajol.info/index.php/ecaajs/article/view/136516> [cited Feb 7, 2021].
7. Swenson BR, Kwaan MR, Burkart NE, et al. Colonic volvulus: presentation and management in metropolitan Minnesota, United States. *Dis Colon Rectum.* 2012;55(4):444-9.
8. Pencle FJR, Katsichtis T, Schneider J, et al. Cecopexy, a reemerging treatment for cecal volvulus: case report and systematic review. *Clin Surg.* 2017;2: 1838.
9. Alghamdi HM, AlShammery S, Lardhi H, et al. Cecal volvulus following mini gastric bypass: a case report and review of literature. *Int J Surg Case Rep.* 2018;53:461-3.
10. EmanuwaOF, Ayantunde AA, DaviesTW. Midgut malrotation first presenting as acute bowel obstruction in adulthood: a case report and literature review. *World J Emerg Surg.* 2011;6. <https://wjeb.biomedcentral.com/articles/10.1186/1749-7922-6-22>.
11. SolisRojas C, VidrioDuarte R, GarcíaVivanco DM, et al. Cecal volvulus: a rare cause of intestinal obstruction. *Case Rep Gastroenterol.* 2020;14(1):206-11.
12. Morris MW, Barker AK, Harrison JM, et al. Cicatrical cecal volvulus following laparoscopic cholecystectomy. *JLS.* 2013;17(2):333-7.
13. Ramirez-Ramirez MM, Villanueva-Sáenz E, Ramírez-Wiella-Schwuchow G. [Elective laparoscopic right colectomy for caecal volvulus: case report and literature review]. *Cir.* 2017;85(1):87-92.
14. Heller MT, Bhargava P. MDCT of acute cecal conditions. *Emerg Radiol.* 2014;21(1):75-82.
15. Butterworth WA, Butterworth JW. An adult presentation of midgut volvulus secondary to intestinal malrotation: a case report and literature review. *Int J Surg Case Rep.* 2018;50:46-9.
16. Ting YY, Farfus A, Trochsler M. Caecal volvulus in an incisional hernia. *J Surg Case Rep.* 2020;2020(10):rjaa422.
17. Mazine K, Elbouhaddouti H, Toughrai I, et al. [Volvulus of the cecum: a rare cause of intestinal occlusion: about two cases]. *Pan Afr Med J.* 2017;28:162.
18. Sage MJ, Younis J, Schwab KE, et al. Colopexy as a treatment option for the management of acute transverse colon volvulus: a case report. *J Med Case Reports.* 2012;6(1):151.
19. Jones RG, Wayne EJ, Kehdy FJ. Laparoscopic detorsion and cecopexy for treatment of cecal volvulus. *Am Surg.* 2012;78(5):E251-2.