






# Prevalence of Os Acromiale in an Indigenous East African Population: A Computerized Tomography Scan-based Study

Mordicai Atinga<sup>1</sup> , Njalalle Baraza<sup>1</sup> , Sarah Wambui<sup>2</sup> , Wachira Joseph Thiong'o<sup>3</sup> , Angela Atinga<sup>4</sup> 

<sup>1</sup>Department of Orthopaedic Surgery, Aga Khan University Hospital, Nairobi, Kenya

<sup>2</sup>Department of Radiology, Aga Khan University Hospital, Nairobi, Kenya

<sup>3</sup>University of Nairobi, College of Health Sciences, Nairobi, Kenya

<sup>4</sup>Department of Interventional Radiology, Sunnybrook Hospital, Toronto, Ontario, Canada

**Correspondence to:** Dr. Wachira Joseph Thiong'o; Email: [joswachira@yahoo.com](mailto:joswachira@yahoo.com)

Received: 26 Feb 2021; Revised: 20 Aug 2021; Accepted: 1 Sep 2021; Available online: 7 Oct 2021

## Abstract

**Background:** Failure of fusion to any of the acromion physes at maturity may lead to an os acromiale. A radiological review into the prevalence of os acromiale in an indigenous East African population was performed using computer tomography (CT) imaging. The study aimed to demonstrate a lower prevalence of os acromiale in an urban population compared with cadaveric studies.

**Methods:** This was a cross-sectional study with consecutive sampling. CT scans of both shoulders obtained for non-shoulder pathology were used for the analysis. CT scanning was performed at a tertiary referral hospital from January 2019 to July 2020.

**Results:** Nine hundred eighty-two CT studies were eligible for the review. There were 148 os acromiale identified that were either pre-acromiale or meso-acromiale. The study found a 15% prevalence of os

acromiale among an ethnic East African population, of which almost 40% were meso-acromiale and 60% were pre-acromiale, with no meta-acromiale. **Conclusion:** The prevalence of os acromiale found in this study is similar to that observed in earlier cadaveric studies.

**Keywords:** Os acromiale, Acromion, Pre-acromiale, Meso-acromiale, Meta-acromiale, Cadaveric studies  
*Ann Afr Surg.* 2021; 19(1): 4-7

**DOI:** <http://dx.doi.org/10.4314/aas.v19i1.2>

**Conflict of interest:** None

**Funding:** None

© 2022 Author. This work is licensed under the Creative Commons Attribution 4.0 International License.

## Introduction

An os acromiale is an anatomical variant wherein there is failure of fusion of the acromion physes (1). The acromion fuses from three physes, a process that is normally complete by 18 years old (2). The failure of fusion can occur at any physis, and os acromiale may be classified based on the location as pre-, meso-, or a meta-acromiale (1).

Prevalence studies based on cadaveric or radiological assessment have shown a rate between 0.7% and 18%, with the higher rate in black African populations (3–5). The etiology of os acromiale has been predominantly hypothesized as being genetic, environmental, or possibly a combination of the two (3). Most cases of os acromiale are asymptomatic (6).

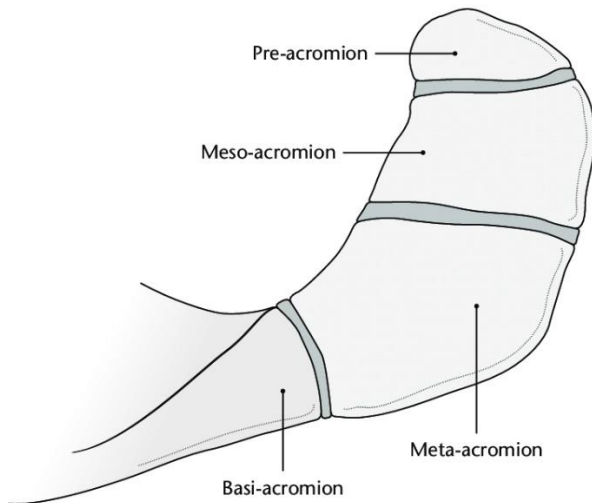


Figure 1. Image showing acromial physes and the resultant anatomical regions relevant to os acromiale (adopted from Antbits.com with permission)

However, the presence of an os acromiale in a patient with rotator cuff pathology increases surgical complexity in subacromial decompression, and separately, the unstable os acromiale may also require fixation (7–9). In clinical practice, an os acromiale is diagnosed radiologically with axial radiographs, computer tomography (CT), or magnetic resonance (MR) imaging. If missed, this can lead to suboptimal or failed surgical treatment for shoulder pathology.

Given the high prevalence reported in the literature (3,10), this study sought to elucidate the prevalence in an indigenous East African population as the surgical management of shoulder pathology accelerates. It was hypothesized that the etiology of os acromiale was environmental, and the incidence of os acromiale would be lower in our urban patient population, who are possibly exposed to less physical strains.

The study aimed to determine the prevalence of os acromiale in an asymptomatic black East African population based on CT imaging and to test the hypothesis that this would be lower than previously published results from cadaveric studies.

### Materials and methods

This cross-sectional study was performed in a tertiary referral hospital. Consecutive CT chest studies performed for non-shoulder pathology between January

2019 and September 2020 were identified from our local picture archiving and communication system. This was to allow at least 800 eligible scans for assessment similar to previous studies (4, 11). The studies were deemed eligible for inclusion if both shoulder girdles, including the acromion, were visible, if the investigated patients were older than 18 years, and if the imaged patients were of black African ethnicity. All CT imaging was performed on either a Somatom Definition flash 256 dual-slice CT scanner (Siemens, Munich, Germany) or a Discovery 64-slice scanner (GE, Boston, MA, USA). All the images were retrospectively reviewed by a single radiologist with a special interest in musculoskeletal radiology. The presence of an os acromiale was assessed on images reconstructed under a bone algorithm. Multiplanar reformats were utilized where necessary.

Demographic data collected included age and sex of the patients, presence or absence of an os acromiale, and, if present, the classification into pre-, meso-, or meta-acromiale (Figure 1). The prevalence was calculated based on the number of CT scans with an os acromiale (unilateral and/or bilateral) as percentage of the total number of CT scans reviewed. Institutional ethics review board approval with a waiver of consent was obtained for this retrospective imaging review.

### Results

A total of 1760 consecutive chest CT studies were performed over the study period. Of these, 982 studies were eligible for inclusion based on our criteria. The average age of the patients who underwent CT scans was 51 years (range, 18–102 years).

A total of 148 CT scans with an os acromiale were identified, indicating a prevalence of 15%. The mean age of patients with os acromiale was 51 years (range, 21–83 years); 82 patients (55%) were female. Bilateral os acromiale was observed in 37% of the patients (n=56).

There were 90 (60.8%) patients with pre-acromiale and 58 patients (39.2%) with meso-acromiale. There were no meta-acromiale identified in this study (Figures 2 and 3; Table 1).

Table 1. Classification of os acromiale in our study population

(n=148)	
Pre-acromiale	
Left	23.6%
Right	16.9%
Bilateral	21%
Meso-acromiale	
Right	6.7%
Left	14.9%
Bilateral	14.2%
Combined	
Left meso, right pre	0.007%
Left meso, bilateral pre	0.007%
Bilateral meso, right pre	0.007%
Right meso, left pre	0.007%
Right meso, right pre	0.007%

Meso, meso-acromiale; Pre, pre-acromiale.

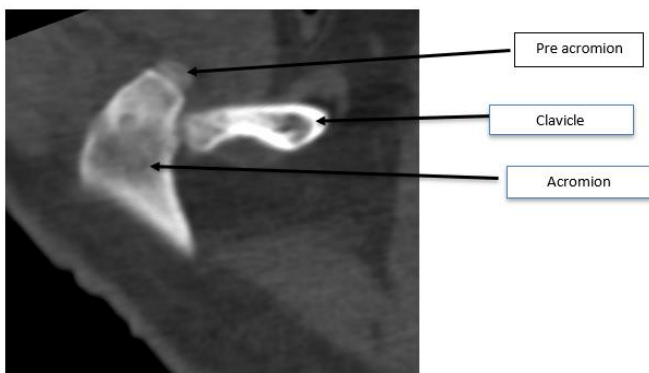


Figure 2. Pre-acromion

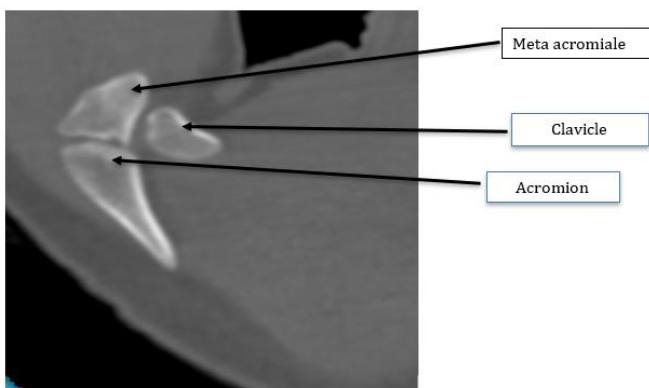


Figure 3. Meta-acromion

**Discussion**

To our knowledge, this is the first large study to use CT scanning to assess the prevalence of os acromiale in a

homogeneous population. It was hypothesized that there would be a lower incidence of os acromiale in a modern urban population due to reduced physical rigors than in the cadaveric specimen in previous studies. However, our calculated prevalence rate of 15% is consistent with rates of 13–18% previously seen in African/African-American populations, nullifying this hypothesis and suggesting a greater impact of other factors, which may include genetic factors as noted in other studies (3, 4, 10).

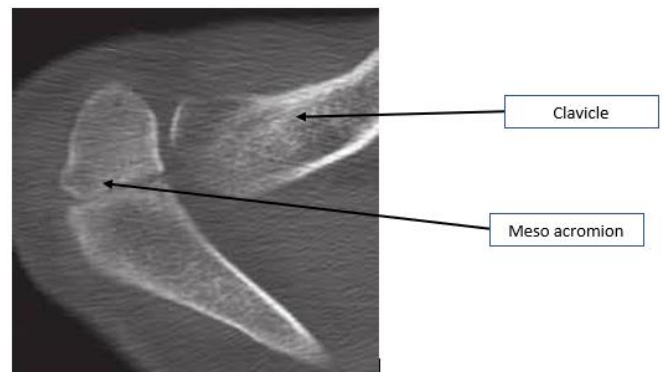


Figure 4. Meso-acromion

No study done on a purely black population and studying the prevalence of os acromiale subtypes was found for a direct comparison with our study. This study’s finding of a higher prevalence of pre-acromiale (60.8%) as compared to meso-acromiale (39.2%) is in contrast to a study by Rovesta et al. (11), which found a higher prevalence of meso-acromiale (88%) over pre-acromiale (12%). The latter study, however, was done on a Euro-Caucasian population.

The knowledge of os acromiale prevalence will increase awareness among orthopedic and emergency doctors reviewing patients with shoulder pathology, particularly when dealing with black patients of African descent. One in seven patients is likely to have an os acromiale, which may influence the approach to surgical treatment when there is surgical pathology.

In this study, the prevalence of pre-acromiale was found to be 60%, which was higher than that of meso-acromiale. This may be an additional important consideration in surgical planning, particularly when considering subacromial decompression surgery in symptomatic patients(13).

Despite a higher prevalence of os acromiale in women with 55%, a systematic review and meta-analysis of os acromiale papers found no significant interaction between sex and prevalence (10).

The strength of this study lies in the fact that we used a large continuous sample of patients investigated for non-shoulder pathology. To our knowledge, this is the largest study to demonstrate os acromiale prevalence using CT scans.

This study has a limitation. Although this study has a large number of samples, our patient cohort could be argued to be representative only of a small demographic of the population with private insurance and does not reflect the population at large.

### Conclusion

The study found an os acromiale prevalence rate of 15% in an indigenous East African population studied via CT. The findings match previous cadaveric studies that have studied os acromiale in both African and African-American populations.

### References

1. Macalister A. Notes on acromion. *J Anat Physiol.* 1893; 27:244.1–51.
2. Kothary P, Rosenberg ZS. Skeletal developmental patterns in the acromial process and distal clavicle as observed by MRI. *SkelRadiol.* 2015;44(deleted2):207–15.
3. Case DT, Burnett SE, Nielsen T. Os acromiale: population differences and their etiological significance. *Homo.* 2006; 57:1–18.
4. Sammarco VJ. Os acromiale: frequency, anatomy, and clinical implications. *J Bone Joint Surg Am.* 2000; 82:394–400.
5. Kumar J, Park WH, Kim SH, et al. The prevalence of os acromiale in Korean patients visiting shoulder clinic. *Clin Orthop Surg.* 2013; 5:202–8.
6. Boehm TD, Rolf O, Martetschlaeger F, et al. Rotator cuff tears associated with os acromiale. *Acta Orthop.* 2005; 76:241–4.
7. Warner JJ, Beim GM, Higgins L. The treatment of symptomatic os acromiale. *J Bone Joint Surg Am.* 1998; 80:1320–6.
8. You T, Frostick S, Zhang WT, et al. Os acromiale: reviews and current perspectives. *Orthop Surg.* 2019; 11:738–44.
9. Hurst SA, Gregory TM, Reilly P. Os acromiale: a review of its incidence, pathophysiology, and clinical management. *EFORT Open Rev.* 2019; 4:525–32.
10. Yammine K. The prevalence of os acromiale: a systematic review and meta-analysis. *Clin Anat.* 2014; 27:610–21.
11. Rovesta C, Marongiu MC, Corradini A, et al. Os acromiale: frequency and a review of 726 shoulder MRI. *Musculoskelet Surg.* 2017; 101:201–5.
12. Rovesta C, Marongiu MC, Corradini A, et al. Os acromiale: frequency and a review of 726 shoulder MRI. *Musculoskelet Surg.* 2017;101(deleted 3):201–5.
13. Spiegl UJ, Millett PJ, Josten C, et al. Optimal management of symptomatic os acromiale: current perspectives. *Orthop Res Rev.* 2018; 10:1–7.