

The Role of Scarless Procedures in Urology: A Review of Literature

Kahie AA

Aga Khan University Hospital, Nairobi

Correspondence to: Dr. Aideed A Kahie, P.O Box 15301-00100 Nairobi, Nairobi. Email: aideed@kaatun.com

Abstract

The popularity of natural orifice transluminal endoscopic surgery (NOTES) or ‘scarless’ surgery has been steadily increasing in the recent urological literature, as a new surgical intervention to access intra-peritoneal organs. NOTES comes with the promise of both scar less and painless postoperative procedures. It utilizes one or more patent natural body orifices with the intention to penetrate a hollow viscous to access the abdomen. It is believed to be the natural progression of laparoscopy, although currently available tools or instruments do not permit a holistic NOTES procedure. There are considerable limitations to the retraction of organs, bleeding control, and

handling of instruments with this method. For this reason, the ‘hybrid’ technique, where a luminal approach is combined with abdominal ports is currently gaining ground. This technique may be the preferred choice for living donor nephrectomy in high volume centers. As a relatively novel procedure, not many studies exist comparing the relative advantages of NOTES over conventional laparoscopy. An assessment of the existing literature on this technique, as pertains to urology, has been undertaken in this article.

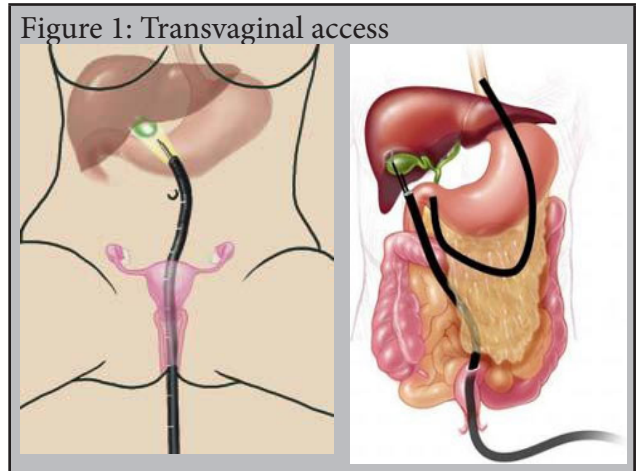
Keywords: Natural Orifices Transluminal Endoscopic Surgery, NOTES, Scarless Surgery, Urology

Ann Afr Surg. 2016;13(1):24-28

Introduction

The development of minimal access surgery (MAS) over the past two decades has eclipsed many traditional open operations. MAS has reduced morbidity, enabled early return to normal activities and has improved scar appearance (1,2). In a bid to optimize these gains, further reduce the impact of surgical trauma and to enhance cosmesis, a scarless intervention has emerged. In this technique, the peritoneal cavity is entered without abdominal wall violation, and the procedure completed with no appreciable abdominal scar (3). This marked the birth of natural orifice transluminal endoscopic surgery (NOTES).

NOTES utilizes the natural openings of the body and the luminal viscous. Piercing the viscous allow access to the target organ in the abdominal cavity. The patient entry points include the mouth, anus, vagina, nares and urethra. The luminal viscera punctured are the esophagus, stomach, colon/rectum, bladder and vagina (Figure 1) (5). The lack of surgical incision potentially translates into reduced wound infection and postoperative pain (6). This intervention has been demonstrated to be effective, reliable and reproducible (7).



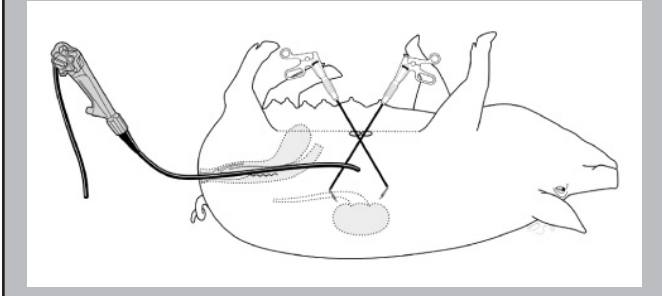
With the initial execution of laparoscopic radical nephrectomy in 1993, MAS has found a fertile specialty in which major urological operations like radical prostatectomy, partial nephrectomy, radical and partial cytectomies have been demystified laparoscopically (11-14). In urology, NOTES has been completed experimentally through trans-gastric, trans-colonic, trans-vesical and trans-vaginal routes.

Lima and co-workers described the trans-luminal vesical route in a porcine model in 2011 while Gettman et al. using porcine model, were able to

perform a trans-vaginal nephrectomy in 2001 (Figure 2) (6,15). Pai et al. demonstrated the use of a trans-colonic port, whose applicability was however limited by its inherent bacterial load (16). Bazzi et al. described the possibility of a trans-rectal NOTES nephrectomy in porcine and cadaveric models (17,18).

This review evaluates the role of NOTES, its history and application and the platforms currently available for its practice in the field of urology.

Figure 2: Transvaginal nephrectomy in a porcine model



Methods

A detailed literature review using Medline/Pubmed data base search was done to identify published peer-reviewed articles, which describe NOTES from a urological perspective. The search was limited to the articles published in the last 10 years in the English literature. Search terms NOTES and urology, NOTES in urology were used. Search results were screened for studies with particular emphasis on clinical studies and reviews.

Results

NOTES Progression: From Concept to Application

Since the first description of NOTES by Kalloo and co-workers in 2004 in porcine experiments, it has carved out a niche for itself in the ever-expanding field of minimal access surgery (3). The Society of American Gastrointestinal and Endoscopic Surgeons (SAGES) and the American Society for Gastrointestinal Endoscopy (ASGE) put together a working group on NOTES to define its nomenclature, surgical description and potential role in surgery advancement (19). The SAGES/ASGE consensus paper emphasized the need for a team approach and the awareness of current interventions presented by NOTES (19).

The major advantage of NOTES for the urologist is the use of a flexible endoscope which urologists are quite familiar with in their daily practice (Figure 3). This potentially enhances its acceptability and training amongst this group of surgeons (17,20-22). In clinical practice Sotelo et al. and Kaouk et al. reported the first successful trans-vaginal NOTES radical nephrectomy

in a human being (23-25). Breda et al. retrieved a non-functional kidney through the vagina, while Gill and co-workers reported vaginal kidney extractions following laparoscopic nephrectomy with comparable morbidity to conventional port extraction (10,26,27).

Figure 3: Endoscope used during NOTES

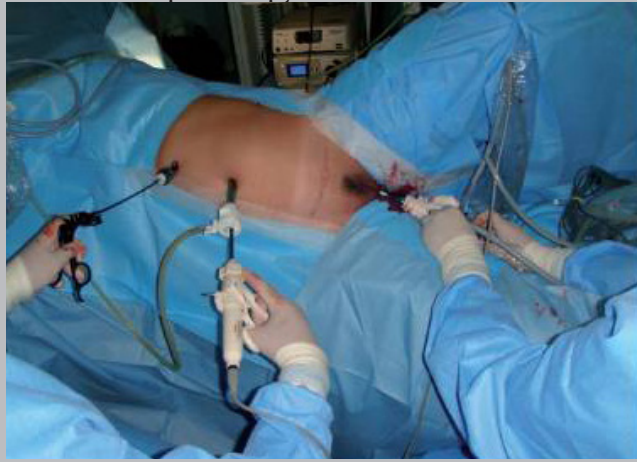

NOTES: The Approach

The steps taken to access the viscera are universal and include: a) luminal access through a patent orifice with an endoscope; b) viscerotomy with a needle knife; c) placement of a guide wire using the Seldinger technique; d) dilating the tract with a balloon over the wire; e) placement of catheter, overtube over the wire and CO2 insufflation; f) scope advancement; g) completion of procedure; h) closure of viscerotomy (28). When a NOTES procedure is combined with the advanced endoscopy, it presents an exciting mode of management of urologic disease. However, sole use of NOTES instruments has been criticized due to their excessive flexibility, and the impossibility of retracting solid organs. There is also limited port access for the use of hemostatic devices, frequent displacement of the surgical field from the visual space with every rotation of the scope and the need to close the internal organ that was punctured to contain potential intra-peritoneal contamination (29-31).

To overcome these technical hurdles, many authors have coupled NOTES with conventional laparoscopy (Figure 4). This necessitated change of nomenclature and the emergence of 'hybrid' NOTES and NOTES-assisted surgery in 2008 (5). When ports are passed trans-abdominally, but the bulk of the procedure (over 75%) is executed with the luminal scope it's designated as 'hybrid' procedure. Conversely when most of the procedure is done laparoscopically and tissue extracted through an orifice or an orifice used as an additional port site it's referred to as NOTES-assisted (5).

Figure 4 Hybrid NOTES combining trans-vaginal route with laparoscopy



This combination affords spatial orientation through camera vision (laparoscopically), instrument triangulation, tissue retraction and dissection (32). Nowadays a range of surgical procedures are carried out using a myriad of different entry points. For instance, the trans-vaginal nephrectomy with a peri-umbilical port for controlled visualization is termed the 'hybrid' transgastric-transvaginal nephrectomy (15,33). Using the transvesical route to access both thoracic and intraabdominal organs when the thoracoscope or umbilical ports are added is also possible (34-36). Porcine experiments on the feasibility of a transureteric 'hybrid' NOTES nephrectomy have also been documented by Baldwin et al (37).

NOTES: The Training

Universal acceptance of newer interventions is always a challenge, and the European and American NOTES working groups recommended a research-oriented team approach (22). This team includes surgeons, urologists, gynecologists and gastroenterologists with endoscopic expertise. A standardized training program focusing on research, instrument familiarization, simulators and dry lab before attempting procedures involving humans must be developed (22,38). NOTES training should also incorporate the new robotic instruments and nanotechnology devices, which give the surgeon flexibility and the stability of instruments to carry out retraction, dissection and suturing (39). Surgical training for NOTES shall be limited by its potential steep learning curve pertaining instrumentation through orifices and lack of long term clinical data concerning safety and efficacy. Multidisciplinary close coordination with other surgical subspecialties and gynecologists will help establish safe access and in developing training program.

NOTES: The Urological Application

Since hybrid NOTES nephrectomy was described by Branco et al other investigators have documented their experience with this procedure (23,24,34,40). At the Cleveland clinic, Kaouk et al. have successfully done the first transvaginal 'pure' NOTES nephrectomy in a female patient with an atrophic right kidney (25). Castillo and others, subsequently followed with two transvaginal 'hybrid' NOTES simple nephrectomies (40). The vagina has been accepted as a viable retrieval route for laparoscopic nephrectomies since its description by Breda et al (26). Colpotomy closure is superior to transgastric or transcolonic with a load of large gynecological literature supporting its use for intraperitoneal access with minimal complication rate. The vagina also allows easier retrieval of large specimen, enables use of rigid instruments for working and camera ports.

Apart from transvaginal non-oncological kidney retrieval, a team in Hospital Clinic in Spain reported transvaginal NOTES-assisted laparoscopic nephrectomies for a T1-T3a,N0M0 renal cancer (17,41). The limitations to the vaginal route is in its potential peritoneal contamination, possible previous gynecological pelvic surgery and the unavailability to the male sex; approximately more than 50% of the population (41).

Another potentially successful NOTES utilization in urology is the living donor nephrectomy and instrumentation/retrieval through the transvaginal port (42,43). Although this is intended to reduce trauma of living donation, it is unfortunately limited to only the female population. Allaf et al. described a vaginal extraction of laparoscopic living donor nephrectomy in 2009 while the Spanish Hospital Clinic team have done over fifty transvaginal **NOTES**-assisted living donor nephrectomies to date (42,44,45). They reported no effect on warm ischemia and graft function compared to conventional laparoscopic nephrectomy (45).

NOTES: Its Future in Urology

The European Association for Endoscopic Surgery and the European Society of Gastrointestinal Endoscopy, together with their counterpart American Urology Working Group have illustrated their targeted goals and their vision for NOTES as; a) to increase NOTES awareness in urology, b) to provide a platform where discoveries related to urological NOTES is shared, c) to guide scientific evaluation and implementation of urological NOTES, and d) to define nomenclature of urological NOTES. Their determination is to safely and progressively enable utilization of NOTES in urology (19,35). Being a new modality, its safety and efficacy has not been proven in randomized trials. Even while

living donor nephrectomy is gaining popularity, there are misgivings about potential dyspareunia, vaginal cuff hematoma and infection (local and peritoneal). Specific limitations that may pose challenges to the growth of NOTES as expressed earlier include lack of purpose built instruments, safety concern of transluminal access, suboptimal optical visualization, poor tissue grasping and manipulation and significant surgeon's fatigue.

Conclusion

While NOTES lays claim to be the most minimal access surgery, it still remains investigational in urology. The current available tools do not allow the safe execution of a procedure by a pure NOTES approach. The new concept of hybrid approach may be the valid alternative to improve morbidity and enhance cosmesis. Prospective randomized trials are awaited to evaluate its benefits and cost-effectiveness. Use of robotic tools and customized instruments may improve ergonomics and facilitate training with a shorter learning curve.

References

- Allan JD, Tolley DA, Kaouk JH, et al. Laparoscopic Radical Nephrectomy. *Eur Urol.* 2001;40:17-23
- Dunker MS, Stiggelbout AM, van Hogezaand RA, et al. Cosmesis and Body Image after Laparoscopic-Assisted and Open Ileocolic Resection for Crohn's Disease. *Surg Endosc.* 1998;12:1334-40
- Kaloo AN, Singh VK, Jagannath SB, et al. Flexible Transgastric Peritoneoscopy: A Novel Approach to Diagnostic and Therapeutic Interventions in the Peritoneal Cavity. *Gastrointest Endosc.* 2004;60:114-7
- Lima E, Rolanda C, Pêgo JM, et al. Third Generation Nephrectomy by Natural Orifice Transluminal Endoscopic Surgery. *J Urol.* 2007;178:2648-54
- Box G, Averch T, Cadeddu J. Nomenclature of Natural Orifice Transluminal Endoscopic Surgery (NOTES) and Laparoendoscopic Single-Site Surgery (LESS) Procedures in Urology. *J Endourol.* 2008;22:2575-81
- Lima E, Branco F, Parente J, et al. Transvesical Natural Orifice Transluminal Endoscopic Surgery (NOTES) Nephrectomy With Kidney Morcellation: A Proof of Concept Study. *BJU Int.* 2012; 109: 1533-7
- Pearl JP, Ponsky JL. Natural Orifice Transluminal Endoscopic Surgery: A Critical Review. *J Gastrointest Surg.* 2008;12:1293-300
- Gettman MT, White WM, Aron M, et al. Where Do We Really Stand With LESS and NOTES? *Eur Urol.* 2011;59:231-4
- Autorino R, Cadeddu JA, Desai MM, et al. Laparoendoscopic Single-Site and Natural Orifice Transluminal Endoscopic Surgery in Urology: A Critical Analysis of the Literature. *Eur Urol.* 2011;59:26-45
- Lima E, Rolanda C, Autorino R, et al. Experimental Foundation for Natural Orifice Transluminal Endoscopic Surgery and Hybrid Natural Orifice Transluminal Endoscopic Surgery. *BJU Int.* 2010;106:913-8
- Clayman RV, Kavoussi LR, Soper NJ, et al. Laparoscopic Nephrectomy. *N Engl J Med.* 1991;324:1370-1
- Gill IS, Desai MM, Kaouk JH, et al. Laparoscopic Partial Nephrectomy for Renal Tumor: Duplicating Open Surgical Techniques. *J Urol.* 2002;167:469-7
- Guillonneau B, Vallancien G. Laparoscopic Radical Prostatectomy: Initial Experience and Preliminary Assessment After 65 Operations. *Prostate.* 1999;39:71-5
- Gillion N, Xylinas E, Durand X, et al. Mid-Term Oncological Control After Laparoscopic Radical Cystectomy in Men: A Single Centre Experience. *BJU Int.* 2011;108(7):1180-4.
- Gettman MT, Lotan Y, Napper CA, et al. Transvaginal Laparoscopic Nephrectomy: Development and Feasibility in the Porcine Model. *Urology.* 2002;59:446-50
- Pai RD, Fong DG, Bundga ME, et al. Transcolonic Endoscopic Cholecystectomy: A NOTES Survival Study in a Porcine Model. *Gastrointest Endosc.* 2006;64:428-34
- Bazzi WM, Wagner O, Stroup SP, et al. Transrectal Hybrid Natural Orifice Transluminal Endoscopic Surgery (NOTES) Nephrectomy in a Porcine Model. *Urology.* 2011;77:518-23
- Bazzi WM, Stroup SP, Cohen SA, et al. Feasibility of Transrectal Hybrid Natural Orifice Transluminal Endoscopic Surgery (NOTES) Nephrectomy in the Cadaveric Model. *Urology.* 2012;80:590-5
- ASGE/SAGES Working Group on Natural Orifice Transluminal Endoscopic Surgery White Paper October 2005. *Gastrointest Endosc.* 2006;63:199-203
- Wagner OJ, Hagen M, Morel P, et al. Who Should do NOTES? Initial Endoscopic Performance of Laparoscopic Surgeons Compared to Gastroenterologists and Untrained Individuals. *J Gastrointest Surg.* 2008;12:1724-9
- Stroup SP, Bazzi W, Derweesh IH. Training for Laparoendoscopic Single-Site Surgery and Natural Orifice Transluminal Endoscopic Surgery. *BJU Int.* 2010;106:934-40

22. Jagannath SB, Kantsevov SV, Vaughn CA, et al. Peroral Transgastric Endoscopic Ligation of Fallopian Tubes With Long Time Survival in a Porcine Model. *Gastrointest Endosc.* 2005;61:449-53
23. Sotelo R, de Andrade R, Fernandez G, et al. NOTES Hybrid Transvaginal Radical Nephrectomy for Tumor: Stepwise Progression Towards First Successful Clinical Case. *Eur Urol.* 2010;57:138-44
24. Kaouk JH, White WM, Goel RK, et al. NOTES Transvaginal Nephrectomy: First Human Experience. *Urology.* 2009;74:5-8
25. Kaouk JH, Haber GP, Goel RK, et al. Pure Natural Orifice Transluminal Endoscopic Surgery (NOTES) Transvaginal Nephrectomy. *Eur Urol.* 2010;57:723-6
26. Breda G, Silvestre P, Giunta A, et al. Laparoscopic Nephrectomy With Vaginal Delivery of the Intact Kidney. *Eur Urol.* 1993;24:116-7
27. Gill IS, Cherullo EE, Meraney AM, et al. Vaginal Extraction of the Intact Specimen Following Laparoscopic Radical Nephrectomy. *J Urol.* 2002;167:238-41
28. White MM, Haber GP, Doerr MJ, et al. Natural Orifice Transluminal Endoscopic Surgery. *Urol Clin North Am.* 2009;36:147-55
29. Ribal Caparros MJ, Peri CL, Molina CA, et al. First Report on Hybrid Transvaginal Nephrectomy for Renal Cancer. *Actas Urol Esp.* 2009;33:280-3
30. Diana M, Leroy J, Wall J, et al. Prospective Experimental Study of Transrectal Viscerotomy Closure Using Transanal Endoscopic Suture vs. Circular Stapler: A Step Towards NOTES. *Endoscopy.* 2012;44:605-11
31. Sherwinter DA, Gupta A, Cummings L, et al. Evaluation of a Modified Circular Stapler for Use as a Viscerotomy Formation and Closure Device in Natural Orifice Surgery. *Surg Endosc.* 2010;24:1456-61
32. Shih SP, Kantsevov SV, Kalloo AN, et al. Hybrid Minimally Invasive Surgery- A Bridge Between Laparoscopic and Transluminal Surgery. *Surg Endosc.* 2007;21:1450-3
33. Branco AW, Branco FAJ, Kondo W, et al. Hybrid transvaginal nephrectomy. *Eur Urol* 2008;53:1290-4
34. Gettman MT, Blute ML. Transvesical Peritoneoscopy: Initial Clinical Evaluation of the Bladder as a Portal for Natural Orifice Transluminal Endoscopic Surgery. *Mayo Clin Proc* 2007;82:843-5
35. Gettman MT, Box G, Averch T, et al. Consensus Statement on Natural Orifice Transluminal Endoscopic Surgery: Heralding a New Era in Urology? *Eur Urol.* 2008;53:1117-20
36. Lima E, Henriques-Coelho T, Rolando C, et al. Transvesical Thoracoscopy: A Natural Orifice Transluminal Endoscopic Approach for Thoracic Surgery. *Surg Endosc.* 2007;21:854-8
37. Baldwin DD, Tenggardjaja C, Bowman R, et al. Hybrid Transureteral Natural Orifice Transluminal Endoscopic Nephrectomy: A Feasibility Study in the Porcine Model. *J Endourol.* 2011;25:245-50
38. Mintz Y, Horgan S, Cullen J, et al. NOTES: A Review of the Technical Problems Encountered and their Solutions. *J Laparoendosc Adv Surg Tech A.* 2008;18:583-7.
39. Baldwin DD, Greene D, Krupp N, et al. Scarless Microport Augmented Restoration of Triangulation (SMART) Surgery: A New Surgical Paradigm. *J Endourol.* 2009;23(Suppl1):A292
40. Castillo OA, Vidal-Mora I, Campos R, et al. Laparoscopic Simple Nephrectomy With Transvaginal Notes Assistance and the Use of Standard Laparoscopic Instruments. *Acta Urol Esp.* 2009;33:767-70
41. Alcaraz A, Peri L, Molina A, et al. Feasibility of Transvaginal NOTES-Assisted Laparoscopic Nephrectomy. *Eur Urol.* 2010;57:233-7
42. Allaf ME, Singer A, Shen W, et al. Laparoscopic Live Donor Nephrectomy with Vaginal Extraction: Initial Report. *Am J Transplant.* 2010;10:1473-7
43. Pietrabissa A, Abelli M, Spinillo A, et al. Robotic-Assisted Laparoscopic Donor Nephrectomy with Transvaginal Extraction of the Kidney. *Am J Transplant* 2010;10:2708-11
44. Laura L, Lluís P, Eduardo G, et al. Recent Advances of Natural Orifice Transluminal Endoscopic Surgery in Urological Surgery. *Int J Urol.* 2013;20(5):462-6.