



Case report

Diagnosed cerebral cortical venous thrombosis after initiation of chemotherapy for Burkitt's lymphoma: a case report

Thrombose veineuse cérébrale corticale diagnostiquée après initiation de la chimiothérapie pour un lymphome de Burkitt : à propos d'un cas

Mohamed Siboub

Correspondence

Mohamed Siboub

Department of Clinical Hematology and Marrow Transplantation, Center Hospitalier Universitaire Mohammed VI, Faculty of Medicine and Pharmacy, Cadi Ayyad University, Marrakech, Morocco

Marrakech, Avenue Ibn Sina, BP 2360, Marrakesh, Morocco

Courriel : simohamedsiboub@hotmail.com

Téléphone : +212645764320

Résumé

La thrombose veineuse cérébrale (TVC) dans le contexte du lymphome constitue un événement rare pouvant être grave et mettre en jeu le pronostic vital. L'évaluation des facteurs de risque pour une bonne stratification des patients est nécessaire avant tout traitement antitumoral. A travers cette observation rare et inhabituelle de TVC survenue après le début du traitement, nous attirons l'attention des praticiens sur l'intérêt d'une prophylaxie primaire des patients diagnostiqués avec lymphome à haut risque de maladie thrombo-embolique veineuse.

Mots-clés : facteurs de risque, lymphome de Burkitt, thrombose veineuse cérébrale

Reçu le 18 décembre 2022

Accepté le 1 février 2023

<https://dx.doi.org/10.4314/aamed.v16i2.15>

Summary

Cerebral venous thrombosis in lymphoma is rare and can be serious and potentially fatal. Evaluation of risk factors for correct stratification is required before antitumor treatment. Initiation of chemotherapy for bulky tumors can induce thrombosis in unusual localizations, which can be a serious diagnostic and therapeutic problem.

Through an unusual and rare observation, we insist on the importance of primary prophylaxis of patients diagnosed with lymphoma with high risk of venous thrombo-embolic disease.

Keywords: Cerebral venous thrombosis, Burkitt's lymphoma, Risk factors

Received: December 18th, 2022

Accepted: February 1st, 2023

<https://dx.doi.org/10.4314/aamed.v16i2.15>

Introduction

Development of thromboembolic complications in patients with solid malignancies is well recognized and studied. This condition was explained by hypercoagulability secondary to excessive production of pro-coagulants in addition to inadequate interaction of tumor cells with the organism's cells, especially platelets (1). Several studies have evaluated risks in lymphomatous pathology according to subtypes, permitting stratification of patients into groups (2). Burkitt's lymphoma, being one of aggressive lymphomas, has not been well included in most of these studies (Burkitt's lymphoma is rare in adults, usually less than 1 % of NHLs).

We report the case of patient with Bulky Burkitt's lymphoma who developed cerebral venous thrombosis after starting chemotherapy.

Patient and observation

A 31-year-old male patient with no prior clinically pathological history developed a rapidly growing cervical mass in the absence of general symptoms. The clinical examination found a performance status of 0, a basic-cervical mass of 3cm/4cm with no inflammatory signs and no other associated abnormalities.

Ultrasonography revealed a cervicomediastinal mass that was biopsied to confirm diagnosis of Burkitt's lymphoma. Extension evaluation did not find any meningeal or spinal cord involvement and Positron emission tomography scanning (Pet-scan) helped to characterize cervical mass with no other lesions (Figure 1).

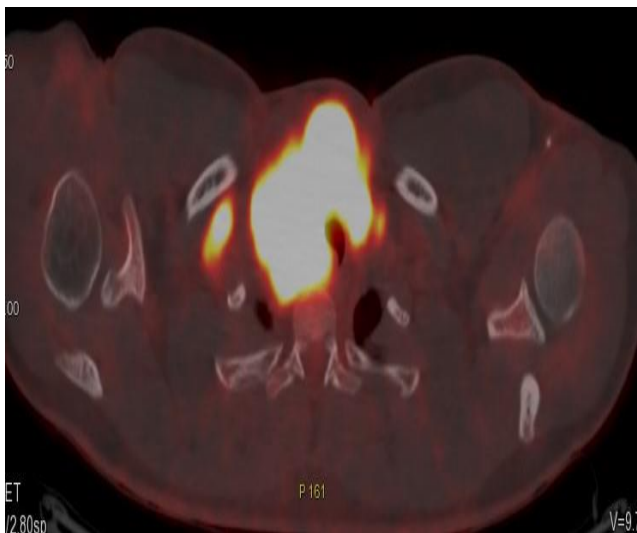


Figure 1: **Pet-CT** showing bulky hypermetabolic mass of the superior mediastinum with tracheal compression.

Patient was classified as group I (no neurological or spinal cord involvement) and stage III of Murphy. Prophylactic anticoagulation was initiated with low-molecular-weight heparin (MWH) and treatment with LMB02 protocol was initiated:

Cyclophosphamide (first day: 300mg/m²), Vincristine (first day: 1mg/m²) and Prednisolone (60 mg/m² D1 to D7). Five days after chemotherapy began, we observed a clear decrease of cervical mass, but unusual headaches appeared. Brain magnetic resonance

imaging (MRI) showed a left parietal cortical venous thrombosis with minor venous infarction (Figure 2).

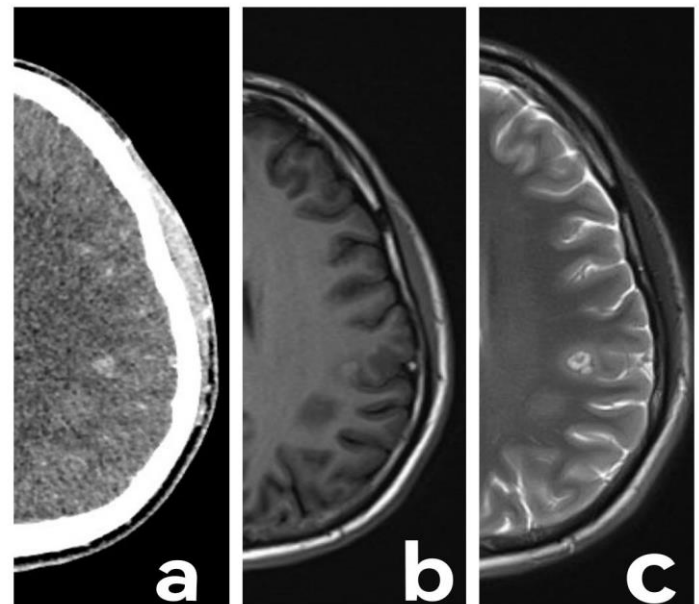


Figure 2: Brain imaging highlighting left parietal cortical venous thrombosis.

(a) **Injected brain scan** (b) **Cerebral MRI in T1** (c) **Cerebral MRI in T2**

Investigations of thrombophilia and systemic disease were normal. Curative anti-coagulation was applied.

Evolution was characterized by improvement of headache and no neurological deficits were previously described.

Patient was satisfied with good evolution: decrease in cervical mass and disappearance of headaches.

Discussion

It is evident that lymphoma represent a risk factor for venous thrombosis development. Several scores have been developed to stratify patients and propose primary prophylaxis regimens (2).

Prevalence of thrombosis is highly variable: 4.7% of Hodgkin lymphomas rising to 6.5% in non-Hodgkin lymphoma. Cerebral venous thrombosis represents 0.5 to 1% of unplanned admissions to neurology, and is more common in young subjects with median age at 33 years, particularly women, most probably due to



hormonal variations (pregnancy and use of estrogen-progesterone contraceptives) (3).

This isolated localization is very rarely associated with lymphoma. It is most often asymptomatic, sometimes leads to focal deficit signs depending on the territory and rarely to convulsions (4).

In the group of patients with NHL, several situations have been identified as high risk with a prevalence exceeding 50 %: aggressive histological forms (in particular diffuse large B-cell lymphoma), bulky involvement (more than 10 cm) and initial localizations in central nervous system and mediastinum (5).

Other known risk factors for solid cancers may increase morbidity and mortality: advanced age, female gender, immobility or prolonged confinement to bed, and association with other comorbidities (such as liver failure, renal disease and history of thrombosis) (2).

Biologically, elevated LDH, hypoalbuminemia, presence of paroxysmal nocturnal hemoglobinuria (HPN) clone and very recently white blood cell count above 11,000 are considered as risk factors for thrombosis. Thrombophilia testing should be encouraged because the risk increases from 5 to 12 in cancer patients. Detection of JAK2 V617F mutation has been reported in several studies (6).

Treatment of venous thrombosis is imperative even if asymptomatic and affecting small veins. This treatment must be started as soon as the diagnosis is made and it is based on an effective anticoagulation associated with control of patient's context (sepsis; usage of pro-thrombotic drugs etc...). LMWH is the gold standard treatment for CVT, generally administered in fractionated doses (two doses over 24 hours), which helps to avoid hemorrhagic transformation. Post-chemotherapy thrombocytopenia generally requires dosage adjustment, change or sometimes temporary discontinuation of anticoagulant therapy. When signs of intracranial tension are present, associated treatment may be proposed depending on the patient's context: Mannitol, hyperventilation, very rarely therapeutic lumbar punctures (7).

Regarding the treatment of lymphoma, the use of granulocyte growth factor and protocols containing Doxorubicin may increase the risk of thrombosis (8).

Currently, there are no specific recommendations for primary prophylaxis in lymphoma setting, and decision remains with clinician after appropriate assessment of risk and feasibility of such prophylaxis.

Conclusion

Risk of thromboembolic complications in lymphomatous pathology is very heterogeneous, which makes it difficult to set up systematic recommendations for prophylaxis and therapeutic management.

Competing interests

The author declares that he had no competing interests.

Authors' contributions

MS was responsible for the diagnosis and treatment. He analyzed and interpreted the patient data. MS approved the final manuscript.

Consent for publication

Written informed consent was obtained from the patient for publication of this case report and any accompanying images.

References

1. Xian Z, Chen Y, Chen L, Lu Q, Huang G, Qin Q, *et al.* A clinical research on the potential pathogenesis of somatic cancer related cerebral venous sinus thrombosis. *Medicine* (Baltimore). 2019 May;**98** (19):e15134.
2. Hohaus S, Bartolomei F, Cuccaro A, Maiolo E, Alma E, D'Alò F, *et al.* Venous Thromboembolism in Lymphoma: Risk Stratification and Antithrombotic Prophylaxis. *Cancers* (Basel). 2020 May 20;**12** (5):1291.
3. Ulivi L, Squitieri M, Cohen H, Cowley P, Werring D. Cerebral venous



thrombosis: a practical guide. *Pract Neurol.* 2020 Oct;**20** (5):356-367.

4. Gagneja A, Birinder S, Kumar V, Saxena A, Paul G. Neurological Predictors of Functional Outcome in Cortical Venous Sinus Thrombosis. *J Neurosci Rural Pract.* 2022 Mar 10;**13** (2):290-294.
5. Sanfilippo KM, Wang TF, Gage BF, Luo S, Riedell P, Carson KR. Incidence of venous thromboembolism in patients with non-Hodgkin lymphoma. *Thromb. Res.* 2016; **143**:86–90.
6. Dharmavaram G, Cao S, Sundaram S. Aggressive lymphoma subtype is a risk factor for venous thrombosis. Development of lymphoma - specific venous thrombosis prediction models. *Am J Hematol.* 2020; **95**: 918–926.
7. Einhaupl KM, Villringer A, Meister W. Heparin treatment in sinus venous thrombosis. *Lancet* 1991; **338**:597–600.
8. Hohaus S, Tisi MC, Bartolomei F, Cuccaro A, Maiolo E, Alma E, *et al.* Risk factors for venous thromboembolism in patients with lymphoma requiring hospitalization. *Blood Cancer J.* 2018 Jun 7;**8** (6):54.

Cite this paper as: Siboub M. Diagnosed cerebral venous cortical thrombosis after initiation of chemotherapy for Burkitt's lymphoma: a case report. *Ann Afr Med* 2023; **16** (2): e5132-e5137. <https://dx.doi.org/10.4314/aamed.v16i2.15>