

Hemorrhagic valsalva retinopathy in a pregnant woman

Rétinopathie hémorragique de valsalva chez une femme enceinte

Charles Geraud Fredy Nganga Ngabou^{1,2},
Chantal Makita¹, Bénédicte Diatewa²

Correspondence

Charles Geraud fredy Nganga Ngabou
Email : fredygeraud@gmail.com
Phone : (+242)069389902

Résumé

La rétinopathie de Valsalva est causée par une augmentation soudaine de la pression intrathoracique ou abdominale, suite à une expiration forcée, avec la bouche et le nez fermés (manœuvre de Valsalva). Cette augmentation de la pression veineuse peut entraîner une rupture des capillaires superficiels de la rétine, entraînant un décollement hémorragique de la membrane interne de la rétine et, éventuellement, une hémorragie du vitré. La perte visuelle associée peut être profonde si une hémorragie survient dans la région prémaculaire. Nous rapportons un cas de rétinopathie de Valsalva chez une parturiente de 36 ans à 24 semaines d'amenorrhée, ayant consulté pour une diminution brutale de l'acuité visuelle de l'œil gauche, évoluant depuis 24 heures après les exercices de gymnastique. La réfraction a démontré une diminution de l'acuité visuelle dans l'œil gauche pour permettre à la main de bouger », alors que l'acuité visuelle est restée normale dans l'œil droit.

Mots-clés: rétinopathie de Valsalva, femme enceinte, hémorragie rétinienne macula

Historique de l'article

Reçu le 12 janvier 2017

Accepté le 3 décembre 2018

1 Teaching University Hospital of Brazzaville, Congo

2 Ophthalmology Clinics, Brazzaville-Congo

Summary

Valsalva retinopathy is caused by a sudden increase in intra-thoracic or abdominal pressure, following forced expiration, with mouth and nose closed (Valsalva maneuver). Increased venous pressure may result in rupture of the superficial retinal capillaries, causing haemorrhagic detachment of the retinal inner limit membrane and, eventually, vitreous haemorrhage. The associated visual loss can be profound if hemorrhage occurs in the pre-macular region. We report a case of Valsalva retinopathy in a pregnant woman at 24 weeks of amenorrhea. A 36 years old patient, who consulted for brutal visual acuity decrease of the left eye, evolving since 24 hours, following the exercises of gymnastics. The refraction has showed a decrease of visual acuity in the left eye to the point the patient can "see the hand moving", while the visual acuity remained normal in the right eye.

Keywords: Valsalva retinopathy, pregnant woman, Retinal hemorrhage macula.

Article information

Received date: 12 January 2017

Accepted date: 3 December 2018

Introduction

Valsalva retinopathy is a rare disease characterized by a sudden visual loss due to pre-retinal hemorrhage, caused by a rapid increase in intraocular venous pressure (1). It often occurs in healthy young adults, following various clinical contexts: intense aerobic exercise, defecation effort, vomiting... The associated visual loss can be profound if hemorrhage occurs in the pre-macular region. We report a case of Valsalva retinopathy in a pregnant woman. This study highlight the place of pregnancy in this pathology, and to show the therapeutic modalities

Case report

A 36-year-old patient who consulted for sudden occurrence of visual acuity decrease that had been evolving for 24 hours in the left eye. Pregnant of 24 weeks, she startled after being frightened, then she performed Valsalva maneuvers to calm down her panic and control her breathing.

The refraction showed a collapse of visual acuity in the left eye to “see the hand moving”, while visual acuity in the right eye was 10/10th. Fundus examination revealed a massive macular pre-retinal hemorrhage in the left eye. We see a bud facing a temporal vessel of the lesion (Figure 1). The fundus of the right eye was normal.

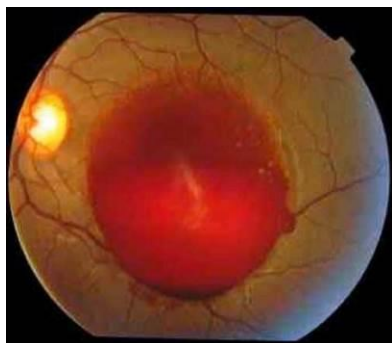


Figure 1. Massive pre-retinal hemorrhage

The biological assessment performed by her obstetrician had found a normal platelet rate, there was no blood-clotting trouble. Fluorescein angiography (FGA) performed two months later showed no leakage. A slower venous return to the arteriovenous time especially on the lower temporal vein, facing the bud (Figure 2a). Late-time dilatation of the same vein (Figure 2b) suggesting a venous lesion.

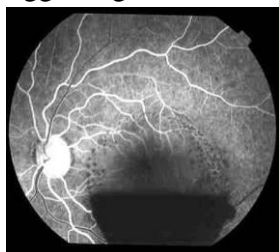

Figure 2a. Slow venous return

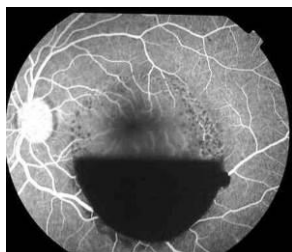


Figure 2b. Venous dilatation next the temporal bud

Spontaneous evolution was marked by a fast and progressive decline of hemorrhage and progressive recovery of vision in the left eye. At one month, the haemorrhage had reduced by almost a quarter (Figure 3a), and by two months by almost two-thirds (Figure 3b).

The patient gave birth vaginally at 37 weeks of amenorrhea, without anesthesia, and without complications. Reviewed 2 months after vaginal delivery, that is 5 months after diagnosis, there

was a complete anatomical and functional restoration, with a visual acuity of 10/10 in the left eye.

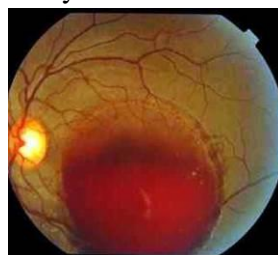


Figure 3a. Regression of hemorrhage at 1 month

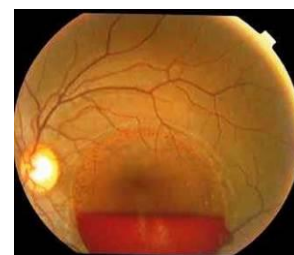


Figure 3b. Regression of 2/3 of the hemorrhage at 2 months

Commentaire

Valsalva retinopathy was described for the first time by Duane in Philadelphia in 1972 (2) on a series of 3 patients composed of two women and one man. No one of both women was pregnant. However, several authors have then described this pathology in pregnant women (1-6). Pre-retinal hemorrhage is related to cephalic hyperpressure (7- 8).

The mechanism of this venous cephalic hyperpressure is explained by the Valsalva maneuver. There are anatomical adhesions of the vitreous to the retinal vessels. The thoracic hyperpressure by blocking in inspiration has repercussions on the cephalic venous circulation and then on the retinal venous one. Under the effect of retinal venous hyperpressure, the adhesions pull the vessel that breaks. It is the vitreous traction on a vein that causes its rupture (8- 9). Kadrmas (10) shows the rupture of a large superior temporal vein that is responsible for Valsalva hemorrhage.

During pregnancy, there is an increase in intra-abdominal pressure. With the Valsalva maneuvers, the pressure becomes considerable to cause the venous rupture (3-4).

In our case, this maneuver was initially reflexed, because frightened the patient blocked her breathing in inspiration in a start, then voluntary by alternating breathing exercises to calm the panic.

Cas clinique

In the case of Nghiem-Buffet, Tara F, Sanjeeva S and García-Fernández (1,3-4,6), the maneuver was related to vomiting. However, El-Khayat (5) has found Yoga apnea exercises.

Aside from pregnant women, Valsalva hemorrhagic retinopathy has also been found regardless of sex, in other circumstances, such as: a) after a sneeze crisis (8); b) in post coital (11); c) after general anesthesia associated with vomiting (1,12); d) after traumatic thoracic compression (1); e) in the practice of weightlifting (1).

Expectancy is often recommended. The usual resorption of haemorrhage without sequelae is common (1,4, 8,11). The timing of spontaneous resorption is very variable. In our case, it was 5 months, as for El-Khayat (5). But, Guignon Souquet (8) noticed resorption after 8 months without treatment. Physical or surgical interventions are likely to bring visual recovery more quickly.

In a series of 6 cases, García-Fernández (1) has performed for a case firstly a derivation of blood in the vitreous with Yag laser, but the maneuver failed. Finally she undertaken a vitrectomy, and the patient completely recovered his vision 10 days after operation. For 4 following patients, vitrectomy was performed as first-intention with total visual recovery. For the last patient who had a small hemorrhage less embarrassing, she had recourse to a conservative treatment and the haemorrhage resorbed spontaneously after one month.

In a series of 12 cases, Khan (13) performed Yag laser treatment on 11 patients without any complication, the 12th who preferred a conservative treatment recovered more slowly. Bypareddy (14) has noted an iatrogenic macular hole with Yag laser in the treatment of a case of pre-retinal hemorrhage, which proves that these interventions are associated with some degree of risk.

Despite the great potential of vaginal delivery to replicate the Valsalva maneuver (15), Wickremasinghe (6), who analyzed these deliveries in pregnant women with Valsalva

hemorrhage, thinks that vaginal delivery without epidural or other intervention is the method that presents the least risk of hemorrhage aggravation.

Conclusion

Valsalva hemorrhagic retinopathy is a rare pathology that is often responsible for sudden unilateral blindness associated with pre-macular retinal hemorrhage. Visual recovery usually occurs after one semester without treatment. Yag laser treatment can quickly help to clear the posterior pole by dispersing the blood in the vitreous. Vitrectomy makes it possible to clean up all the haemorrhage more quickly. It should be noted that these two interventions may lead to complications.

Conflict of interests

The authors claim they have not any conflict of interest in link with this article.

Contributors for authors

All authors contributed equally to this paper

References

1. García-Fernández M, Castro-Navarro J, Gonzalez-Castano, C. Long-term evolution of Valsalva retinopathy: a case series. *Journal of Medical Case Reports* 2012, **6**: 346.
2. Duane, T.D. Valsalva hemorrhagic retinopathy. *Trans Am Ophthalmol Soc* 1972, **70**, 298-313.
3. Nghiem-Buffet S., Guiberteau B. Rétinopathie de Valsalva et grossesse. *Images en Ophthalmologie*, 2009, **3** : 86-87.
4. Tara F, Sharifi M, Hoseini E. Valsalva retinopathy in pregnancy: a case report. *BMC Research* 2015, **8**: 67.
5. El-Khayat AR. Valsalva haemorrhagic retinopathy in pregnancy after yoga. *BMJ Case Rep.* 2017; **11**. doi: 10.1136/bcr-2017-221099.
6. Wickremasinghe SS., Tranos PG, Davey C. Valsalva haemorrhagic retinopathy in a pregnant woman: implications for delivery. *Acta Ophthalmol Scand* 2003, **81**, 420-422.
7. Matonti F, Donadieu V, Hoffart L, Dornadin A, Nadeau S, Roux S, Denis D. Traitement précoce par laser Nd: YAG de la rétinopathie de Valsalva: resultants à propos de cinq cas et revue

- de la littérature. *J Fr Ophtalmol* 2013, **36**, 604-609.
8. Guigon-Souquet B, Salaun L, Macarez R., Bazin S, De La Manierre E, Mazdou M. Hemorragie rétrohyaloïdienne secondaire à une manœuvre de Valsalva. *J Fr Ophtalmol* 2004, **27**, 1159-1162.
 9. Takano M., Sugiura N, Yonemoto J, Ohno S. Vitreous hemorrhage associated with acute posterior vitreous detachment--a case report. *Jpn J Ophtalmol* 1993, **37**:199-203
 10. Kadrmas EF, Pach JM. Vitreous Hemorrhage and Retinal Vein Rupture. *Am J Ophtalmol* 1995, **120**, 114-115
 11. Michaels L, Tint NL Alexander P. Postcoital visual loss due to valsalva retinopathy. *BMJ Case Rep* 2014. 1136 bcr doi: 10.1136/bcr-2014-207130
 12. Patane PS, Krummenacher TK, Rao RC. Valsalva hemorrhagic retinopathy presenting as a rare cause of impaired vision after a general anesthetic-a case report and review of the literature. *J Clin Anesth* 2015; **27** (4), 341-346.
 13. Khan MT, Saeed MU, Shehzad MS, Qazi ZA Nd:YAG laser treatment for Valsalva premacular hemorrhages: 6 month follow up: alternative management options for preretinal premacular hemorrhages in Valsalva retinopathy. *Int Ophtalmol* 2008, **28** (5):325-327
 14. Bypareddy R, Chawla R, Azad SV, Takkar B. Iatrogenic parafoveal macular hole following Nd-l: YAG posterior hyaloidotomy for premacular haemorrhage. *BMJ Case Rep* 2016, doi: 10.1136/bcr-2016-217234.
 15. Eneh, A., Almeida, D. Valsalva hemorrhagic retinopathy during labour: a case report and literature review. *Can J Ophtalmol* 2013,;**48**:145-147