

COLOSTOMY COMPLICATIONS IN CHILDREN

A. F. Uba and L. B. Chirdan

Paediatric Surgery Unit, Department of Surgery, Jos University Teaching Hospital, Jos, Nigeria
Reprint requests: DR A.F. Uba, Paediatric Surgery Unit, Department of Surgery, Jos University Teaching Hospital, Jos, Nigeria. E-mail: afranu@yahoo.com or ubaa@unijos.edu.ng

Abstract

Background: Colostomy is a common procedure in children and may be attended by significant morbidity.
Method: This is a retrospective study of morbidity and mortality associated with the formation and closure of colostomy in children between 1991 and 2001, at the Jos University Teaching Hospital (JUTH), Jos, Nigeria.

Results: There were 116 children with a median age of 3 weeks (range: one day 14 years). The male: female ratio was 2:1. The indications for colostomy were Hirschsprung's disease 68 (58.6%), anorectal malformations 44 (37.9%) and trauma to the rectum 4(3.5%). A total of 122 complications occurred in 62(53%) patients after colostomy formation. The commonest complication was excoriative dermatitis 46(74.2%), followed by prolapse 24(38.7%) and wound infection. Difference in complications between transverse and sigmoid colostomies was statistically significant ($P < 0.05$). One hundred and eight (93.1%) children had intraperitoneal closure of colostomy, 21 (19.4%) of who developed surgical site sepsis. The overall mortality was 16 (13.8%), exclusively from colostomy closure.

Conclusion: Colostomy-related procedures in children are associated with high morbidity and mortality in our environment. Improved health care delivery may improve the present outcome. Colostomy-related operations should not be relegated to minor importance.

Key words: Colostomy, complications, children

Introduction

Colostomy is frequently employed in the management of children with congenital/acquired conditions of the colon or the ano-rectum. In developed countries, primary pull-through operations are increasingly performed to treat Hirschsprung's disease and anorectal malformations.¹ This is not so in many parts of Africa, and colostomy has continued to be a life-saving procedure in the management of these children. Since colostomy in children is usually done for the treatment of a non-malignant condition and is temporary, there is tendency to relegate colostomy-related procedures to minor importance. However, serious complications may result from the procedure.²⁻⁸ This is a report of our experience with colostomy in children and aims to identify the problems associated with it in the environment. Preventive measures of the complications are presented.

Patients and method

All the cases of colostomy performed in children at the Jos University Teaching Hospital (JUTH) between October, 1991 and September 2001 were

retrospectively reviewed. Data extracted from patients' case files, ward registers and operation notes were analysed for age, indications, types and sites of the colostomy and outcome, using the EPI Info and Excel software. The stoma-related complication rates were compared using the Chi-square. The level of significance was taken as $p < 0.05$.

Results

One hundred and twenty-eight colostomies were done, but adequate records were available in 116 patients. Seventy-eight were boys while 38 were girls, with a male-to-female ratio of 2.1. Their ages at colostomy formation ranged from 1 day to 14 years (median: 3 weeks). Figure 1 shows the age distribution of the children. Seventy-seven (66.4%) patients were aged one year or below. The modal age range was >28 days \leq year.

Indications for colostomy

Colostomy was constructed for Hirschsprung's disease in 68 (58.6%) children, while anorectal malformation was the indication in 44 (37.9%). In 4 (3.5%) others colostomy was constructed to divert faeces from rectal injuries.

Figure 1: Age of 116 children who had colostomy

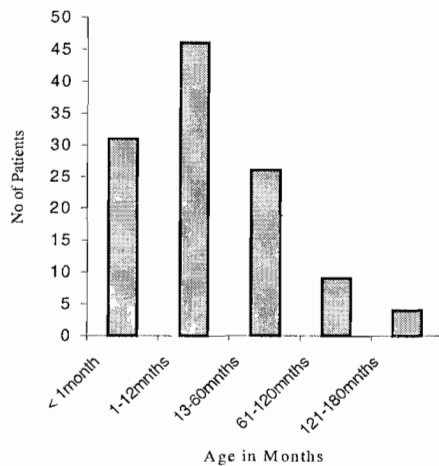


Table 1: Site and type of colostomy in 116 children

Site	Loop (%)	Divided (%)	Total (%)
Transverse colon	47(40.5)	11(9.5)	58(50.0)
Descending colon	4(3.5)	7(6.0)	11(9.5)
Sigmoid colon	7(6.0)	40(34.5)	47(40.5)
Total (%)	58(50.0)	58(50.0)	116(100)

Table 2: Complications in 62 children undergoing colostomy

Complication	TC		DC		SC	
	L (%)	D (%)	L (%)	D (%)	L (%)	D (%)
	n=47	n=11	n=4	n=7	n=7	n=40
Wound	-	3(27.3)	1(25)	2(28.6)	-	2(5)
Bleeding+	-	-	-	-	3(42.9)	1(2.5)
Bowel evisceration+	-	-	-	-	-	-
Infection+	1(2.1)	4(36.4)	-	2(28.6)	-	4(10.0)
Stoma						
Oedema/obstruction+	-	3(27.3)	-	1(14.3)	-	4(10.0)
Strangulation/necrosis+	-	1(9.1)	-	2(28.6)	-	3(7.5)
Dermatitis	17(36.2)	9(81.)	-	-	3(42.9)	5(2.5)
Prolapse	12(25.5)	4(36.4)	-	-	6(85.7)	2(5.0)
Diarrhoea	5(10.6)	1(9.1)	-	-	-	2(5.0)
Stenosis	-	1(9.1)	-	-	-	3(7.5)
Retraction	-	-	-	-	-	3(7.5)
Hernia	1(2.1)	-	-	-	1(14.3)	-

TC vs SC : $X^2 = 8.39$, $P = 0.003868$, $d^0 = 1$

+ Early complications (< 1 month).

Some children had more than one complication

All others = Late complications (>1 month post operative)

TC = Transverse colostomy, DC = descending colostomy, SC = Sigmoid colostomy, L = loop, D = Divided

Sites/types of colostomy

Table 1 shows the sites and the types of colostomy. In 58(50.0%) children, the colostomies were cited on the transverse colon. Forty-seven (40.5%) of the transverse colostomy were loop, while 11(9.5%) were divided. Forty-seven children had sigmoid colostomy, with 40(34.5%) divided and 7(6.0%) loop. The remaining 11(9.5%) patients had their colostomy on the descending colon, with 4(3.5%) loop and 7(6.0%) divided.

Colostomy closure

The duration of the colostomy before closure ranged from 3 to 9 months. Colostomy closure was preceded by routine colonic and rectal wash outs for at least 2 days. All the patients had intraperitoneal closure of the colostomy. The colostomies were closed in 108(93.1%) patients, while 8(6.9%) children were lost to follow-up before their colostomy closure could be effected.

Complications

Table 2 shows the distribution of the various complications following the colostomy formation. Sixty-two (53.0%) children had complications. Transverse colostomy (TC) had a total of 62 complications, while 14 and 42 complications occurred following the descending colostomy (DC) and sigmoid colostomy (SC), respectively. Wound-related complications occurred in 23(37.1%) children, which included bleeding, infection and wound dehiscence with bowel evisceration. Thirty-nine (62.9%) children had stoma-related complications, comprising escoriative dermatitis, bowel prolapse, stoma retraction, colostomy diarrhoea and parastomal hernia. Twenty-one (19.4%) of the patients who had colostomy closure, developed wound infections (divided sigmoid colostomy 37%, transverse loop colostomy 19%, divided descending colostomy 19%, divided transverse colostomy 10%, sigmoid loop colostomy 10%, loop descending colostomy 5%).

Mortality

The overall mortality rate after the formation of the colostomy was 13.8%(16) involving 10 neonates and 6 infants. Two of the neonates died on the operation table, while 8 died within 24 hours after the operation from overwhelming sepsis in 5 and fluid overload in 3. Two of the infants died from severe diarrhoea, 3 from sepsis and 1 from fluid overload.

Discussion

Colostomy remains a life-saving procedure in the management of colonic and anorectal pathology in children, especially where late presentation and lack of necessary facilities preclude a primary repair.¹ Colostomy in the paediatric age group should be regarded as a major procedure that demands meticulous attention to details.

Indications for colostomy in children are invariably benign, unlike in adults. Hirschsprung's disease (HD) was the leading indication for colostomy in this study followed by anorectal malformations (ARM). This finding is similar to the reports from elsewhere.^{5,8-10} Our preference has been for loop colostomy for Hirschsprung's disease, hence the predominance of this type of colostomy in the present series. The use of divided colostomy was largely reserved for ARM and injury to the rectum, where total faecal diversion was a necessity. On occasions, however, divided and loop colostomies were offered for HD and ARM, respectively. Citing the stoma in the right transverse colon spared the entire left colon for reconstruction, but the stoma-related problems were high in this series. A similar observation has been reported elsewhere.^{3,4,11} Descending and sigmoid colon stomas were relatively trouble free, and yet left enough bowel length for reconstruction.

The pattern and the complication rate of 53% in

this report compares favorably with previous reports.^{3,4,11,12} Early complications included wound infection and skin excoriation, other early complications were invariably mechanical in nature, like wound dehiscence and bowel evisceration, stoma obstruction, strangulation and necrosis. All the 4 cases of bowel evisceration required urgent revision. The low incidence of revision surgery in the present series is similar to the report by Sowande, but contrasts with the 16.4 – 18.6% reported by other authors.⁵⁻⁸ This low incidence implies that the commoner complications of colostomy do not necessarily require a revision operation. Bowel evisceration (and parastomal hernia) results either from failure to fix the colostomy to the fascia or from the breakdown in fixation of the colostomy. Proper fixation of the stoma to the fascia, using non-absorbable or delayed absorbable suture should avert this problem. To avoid excessive narrowing of the stoma, and hence stoma oedema and early obstruction/strangulation, an appropriately sized Hegar dilator or catheter should be inserted into the intestinal lumen at the time of colostomy formation. Early postoperative inspection of the mucosa at the stoma is imperative for early detection of stoma strangulation (blue-black discoloration) and necrosis. The late consequence of such strangulation includes stoma stricture and retraction.

In this study, complications were significantly less frequent in sigmoid loop colostomies when compared to transverse loop colostomies (41.9%vs 58.1%, $P < 0.05$). This finding is not different from other studies.¹³ This difference relates to a lower incidence of skin complications in the sigmoid group. This observation may be due to the fact that most divided colostomies were sited in the sigmoid where faeces is more formed, with little or no skin contamination.

Excoriative dermatitis was the highest complication in this report as in others,^{11,15,14} and occurred more in the colostomies cited in the transverse colon. It is possible that when the enzyme-rich liquid faeces of the right colon makes contact with the skin, the protein structures in the skin are digested resulting in the excoriation and inflammation of the skin result. To prevent this complication, colostomies should be sited on the left or sigmoid colon, whenever feasible. The application of colostomy bags to collect the faecal matter prevents the skin excoriation but, in our environment these appliances are either not readily available or are too costly. Instead cellophane bags are commonly applied as alternatives, with the faeces still leaking on the skin around the poorly fitted bag. Application of a non-adhesive oily solution (e.g. Vaseline) around the stoma to act as an interface between the faeces and the skin would prevent the skin excoriation. Where the excoriation had already occurred, applying zinc oxide paste was curative.

Colostomy prolapse was the second commonest complication, occurring in 24 (20.7%) children. This

is in concordance with other reports.⁵⁻⁸ Prolapse was three times as common in loop as in divided colostomy. Previous authors reported a similar finding.^{11,16} Intentionally narrowing the distal stoma in loop colostomy may prevent distal prolapse.¹⁶ A flush colostomy, without bringing the whole transverse loop out beyond the skin level,¹⁴ has been reported to have a similar preventive effect. None of the prolapse in this series required a revision surgery.

Colostomy diarrhoea occurred in 3 patients with transverse colostomy and 5 patients with sigmoid colostomy in our series. This finding is similar to the report by Sowande.¹ The diarrhoea was responsible for the death in 2 infants who also had Hirschsprung's disease.

Colostomy closure also requires diligence to technical details and postoperative care, though it is frequently an underrated procedure.⁵ All our patients had the intraperitoneal closure, resecting the exteriorized colon with careful end-to-end anastomosis. Twenty-one (19.4%) of our patients developed surgical site sepsis after colostomy closure. This is quite low compared to other series.¹ Colostomy-related surgical site sepsis results from faecal contamination of the wound at surgery. Pre-operative preparation of the bowel and careful attention to technical details would prevent such contamination. Mollitt et al⁵ had suggested that delayed primary closure would prevent such surgical site sepsis. No faecal fistula, anastomotic leaks and intestinal obstruction reported elsewhere^{1, 3, 4} occurred in our study.

Sixteen (13.8%) of our patients died. This mortality rate is quite high compared to the reports from the developed countries.^{5, 6, 8} Most of the deaths were related to fluid management, occurring in neonates and infants. This underscores the importance of diligence in the post-operative management of these patients.

Colostomy in children is associated with significant morbidity and mortality in our environment. Good outcome demands careful attention to technical details and good postoperative and stoma care. More frequent use of sigmoid (or left) colon (when feasible) should be encouraged as it appears to be associated with fewer complications. Colostomy operations should not be underrated or relegated to the lowest member of the team.

References

1. Sowande OA, Adejuyigbe O, Ogundoyin O et al. Colostomy complications in infants and children.

- Nigerian Journal of Surgery 1999; 6: 19-22.
2. Bishop HC. Colostomy in the newborn. *Am J Surg* 1961; 101:642 - 648.
3. MacMahon RA, Cohen SJ, Eckstein HB. Colostomies in infancy and childhood. *Arch Dis Child* 1963; 38:114-117.
4. Brenner RW, Swenson O. Colostomy in infants and children. *Surg Gynecol Obstet* 1967; 124:1239-1244.
5. Mollitt DL, Malangoni MA, Ballantine TVN, Grosfeld JL. Colostomy complications in children: an Analysis of 146 cases. *Arch Surg* 1980; 115:455-458.
6. Lister J, Wabser PJ, Mirza S. Colostomy complications in children. *Practitioner* 1988; 227: 229-237.
7. Al-Salem AH, Grant C, Khawayo S. Colostomy complications in infants and children. *Int Surg* 1983; 77: 164-166.
8. Nour S, Beck J, Stringer MD. Colostomy complications in infants and children. *Ann R Coll Surg Engl* 1996; 78: 526-530.
9. Adotey JM, Colostomy – the Port Harcourt experience. *West Afr J Med* 1998; 3: 179-183.
10. Egbuomwan EA. Colostomy in paediatric practice: observation at the University of Benin Teaching Hospital, Benin City. *Nigerian Journal of Paediatrics* 1990; 142: 33-36.
11. Park JJ, Del Pino A, Orsay CP et al. Stoma complications: the Cook County Hospital experience. *Dis Colon Rectum* 1999; 42: 1575-1580.
12. Hut'an M, Salapa M, Balaz P, Sokol R. Complications of colostomy-how to avoid them. *Rozhledy V Chirurgii* 1999; 78: 593-596.
13. Edwards DP, Leppington-Clarke A, Sexton R, Heald RJ, Moran BJ. Stomal-related complications are more frequent after transverse colostomy than loop ileostomy: a prospective randomized clinical trial. *Br J Surg* 2001; 88: 360-363.
14. Law WL, Chu KW, Choi HK. Randomized clinical trial comparing loop ileostomy and transverse colostomy for faecal diversion following total mesorectal excision. *Br J Surg* 2002; 89:704-708.
15. Cooney DE, Grosfeld JL. Care of the child with a colostomy. *Pediatrics* 1977; 59:469-472.
16. Gauder WLM. Stomas of the small and large intestine. In: O'Neill Jr, Rowe MI, Grosfeld JL et al (Eds) *Pediatric Surgery*, Mosby, Philadelphia. 1998; 1349-1359.