

Access this article online	
Quick Response Code:	Website: www.annalsafrmed.org
	DOI: 10.4103/1596-3519.93531

Ultrasound-guided wire localization of lesions detected on screening mammography in Osogbo, Nigeria and its impact on breast conservative surgery

Sulaiman O. Agodirin, Oluyemisi M. Ojemakinde¹, Temitope O. Bello¹, Adetunji S. Oguntola, Ademola A. Aremu¹, Kunle O. Ojemakinde², Moses L. Adeoti, Emmanuel A. Agbakwuru³

Departments of Surgery, ¹Radiology and ²Histopathology, LAUTECH Teaching Hospital Osogbo, Osun State, ³Department of Surgery, Obafemi Awolowo University Teaching Hospital Complex, Ile-Ife, Osun State, Nigeria

Correspondence to: Dr. T. O. Bello, Department of Radiology, LAUTECH College of Health Sciences, PMB 4400, Osogbo, Osun State, Nigeria. E-mail: topebello@gmail.com

Abstract

Background: Wire localization for planned surgical treatment in the management of breast cancer is underutilized in our environment. The objective of this study is to assess the role of ultrasound-guided wire localization of breast masses detected on screening mammography and its impact on biopsy and breast conservative surgery in our environment

Materials and Methods: A prospective study of 189 women who presented for screening mammography following a health campaign on breast cancer within a six-month period. Wire localization for mammographic detected lesions was done under ultrasound guidance. The lesions excised were sent for specimen radiography and histology.

Results: Ten women had wire localization of breast lesions and subsequent excision. Three lesions were on the right and 7 on the left; out of which 3 were malignant. The mean volume of excised tissue was 74.27 ± 30.16 cm³.

Conclusion: Early detection of breast cancer is possible and practicable in our environment. Wire localization of detectable lesions on mammography will assist in better surgical management and improve prognosis.

Keywords: Breast cancer, breast conserving surgery, screening mammography, wire localization

Résumé

Fond: Localisation de fil pour le traitement chirurgical prévue dans la gestion du cancer du sein est sous-utilisé dans notre environnement. L'objectif de cette étude est d'évaluer le rôle de localisation de fil guidée par l'échographie des masses du sein détecté sur le dépistage de la mammographie et son impact sur la chirurgie conservatrice biopsie et la poitrine dans notre environnement

Des matériaux et des procédés: Une étude prospective de 189 femmes qui a présenté à la suite d'une campagne de santé sur le cancer du sein dans un délai de six mois de mammographie de dépistage. Fil localisation pour les lésions détectées mammographiques a été effectuée sous la guidance de l'échographie. Les lésions excisées ont été envoyées pour l'histologie et radiographie de spécimen.

Résultats: Dix femmes avaient fil la localisation des lésions de la poitrine et l'excision subséquente. Trois lésions étaient à droite et 7 sur la gauche; dont 3 ont été malin. Le volume moyen de tissu excisée était cm 74.27 ± 30.16 .

Conclusion: La détection précoce du cancer du sein est possible et si possible dans notre environnement. Localisation de fil de lésions détectables sur la mammographie aidera à améliorer la gestion de chirurgie et améliorer le pronostic.

Mots clés: Le cancer du sein, conservation de la chirurgie, mammographie de dépistage de la poitrine, la localisation de fil

Introduction

Breast cancer management has improved over the last two decades, with new innovations and specialization of multidisciplinary breast units.^[1] In the management of breast cancer, conservative and selective surgical approaches for breast and axilla have become standard therapy, when appropriate.^[1,2]

Screening has increased the diagnosis of suspicious, non-palpable lesions at earlier stages and substantially decreased the incidence of lymph node involvement.^[3] In Western Europe and North America, about 50% of breast cancer is diagnosed in non-palpable stage and the improved localization for planned surgical treatment allows one-step precise and directed excision.^[4] Wire localization is the most common technique used to identify small nodules, microcalcifications or parenchymal distortions.^[1] Localization methods include mammography (MG), pre- and intra-operative ultrasound (US) and magnetic resonance imaging (MRI).

Breast conserving approaches have been developed in the last three decades with the objective of maintaining the natural appearance of the breast and preserve the overlying skin; while making efforts to avert local recurrence. Breast conserving surgeries (BCS) have similar results to mastectomy in selected patients in terms of local recurrences or local failures and survival.^[4]

Despite the world's interest in BCS, wire localized breast biopsy (WLBB) and BCS for early carcinoma of the breast are rarely done in our environment due to many reasons. These includes late presentation, ignorance, lack of screening facilities, difficulty with follow-up, non-availability of radiotherapy and lack of facilities.^[5-12]

This is a preliminary report of US-guided wire localized biopsy and excision for screen detected non-palpable breast lesions.

Materials and Methods

This study was carried out between June 2009 and May 2010 in the surgery and radiology department of our institution

We obtained approval from the hospital ethical committee and informed consent from the enrolled patients. Enlightenment programs were held independently and in collaboration with a nongovernmental organization, Tumor Suppressor Maternal, an organization that offers free and subsidized services to women with breast and cervical

cancer.

The subjects were selected from patients who presented for screening mammography. The inclusion criteria were the following: patients above 35 years willing to perform a screening mammography and undergo incisional or excisional biopsy if indicated. Those with non-palpable mass demonstrated on mammography and ultrasound in which US-guided fine needle aspiration biopsy was inconclusive. Exclusion criteria are palpable lesions and in cases of non-palpable masses in which fine needle aspiration biopsy results were conclusive.

Wire localization

This was carried out by radiologists (BTO, OM) in the ultrasound unit, a SONOACE X4 ultrasound machine (Medison, South Korea) 7.5-10 MHZ probe frequency was utilized for the procedure. After US localization of the lesion, the point of insertion was cleansed with alcohol and numbed with xylocaine. Antiseptic lotion was used to reduce contamination and also as an acoustic coupling agent. Dedicated wire localization needles are not available in our environment; therefore, we improvised by using a malleable slender steel wire, similar in consistency to dental suture. The main criterion is the ability of the wire to pass through the hollow of an 18G needle. The wire was sterilized by a steam sterilizer and then introduced via ultrasound guide through the hollow of the 18G intravenous or spinal needle. The tip of the wire was placed just above or inside the lesion with the tip slightly beyond the lesion. The tip of the wire was dented to produce a self-retaining tip in order to reduce migration by a gentle jab of the needle before the latter was completely removed. The cut end of the wire projecting out of the skin was held in place with tape.

Surgical excision

All excisions were performed by the same surgeon under local anesthesia with conscious sedation, the wire was held in place to the skin at the point of insertion with a pair of forceps. An incision from 1 cm behind the insertion point of the wire and 2 cm in excess of the estimated length of the inserted wire was made radially in the plane of insertion of the wire leaving an island of skin around the wire held by the mosquito forceps. Skin flaps were then raised 2-3 cm in all directions away from the line of incision and a block/cube of tissue was excised by sharp dissection down to the retromammary space ensuring that no part of the inserted wire is exposed in an attempt to achieve clear margins. The excised tissue with the wire *in-situ* is orientated and immediately sent in saline for specimen radiograph to confirm the inclusion of the lesion before closure

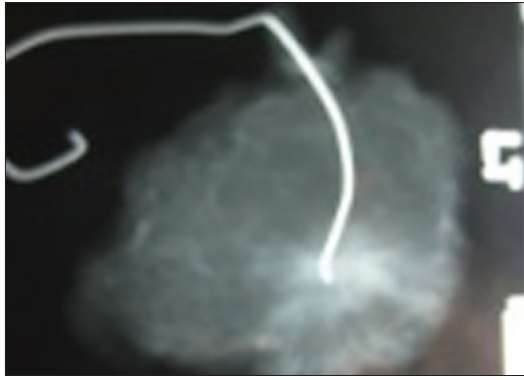


Figure 1: Specimen mammography showing the wire localized within a breast mass

of the wound. The specimen was sent for histology after specimen radiography [Figure 1]. The volume of the excised tissue was estimated by using the formula [length x breadth x height]. An attempt was made to reconstruct the normal contour of the breast in all cases. Maintaining the breast contour was given preference over complete dead space obliteration and silk 2 sutures were used as drains in all patients. All patients were observed for 2 h before discharge and subsequently seen at the outpatient clinic weekly for four weeks and then monthly for six months.

All cases were performed as day case under local anesthesia within 2 h of wire insertion. All patients had single dose prophylactic antibiotic preoperatively and pressure bandaging after the procedure.

Results

One hundred and eighty nine women presented for screening within 6 months of the campaign. This is an average of 32 per month compared to an average of 9 per month before the campaign.

Only 10 patients fit the inclusion criterion of a non palpable mass detectable on mammography and ultrasound. The age range was 36-57 years. None of them had clinically evident breast lesion, but two patients had axillary adenopathy detected at physical examination. A patient had both hypertension and diabetics.

Three lesions were on the right and 7 on the left. The lesions were in upper outer quadrant (UOQ) in 6 patients, central (CEN) in 2 patients, and in the lower outer quadrant (LOQ) and lower inner quadrant (LIQ) in one patient each. The localizing wire was optimally placed i.e. either inside the lesion or within 1 cm around the target lesion in all cases; in 3 patients the wire was placed inside the lesion while in the remaining it was above the lesion.

The incision extended into the areola in five procedures. The deep end of localizing wire was exposed inadvertently intra-operatively in two cases, none of those two required re-excision after specimen radiography. In one patient, even though the tip of the wire was not exposed, it was obvious intra-operatively that the lesion had been incompletely excised and hence immediate re-excision was done.

The mean volume of tissue removed was $74.27 \pm 30.16 \text{ cm}^3$ and the mean longest diameter was $8.2 \pm 1.7 \text{ cm}$. The specimen radiograph showed that the localizing wire or needle had migrated more than 1 cm from the lesion in 3 specimens. Also, in 3 specimens the lesion was eccentrically placed toward one periphery while in the latter 4 specimens, the lesions were centrally located within the specimens.

Histology revealed that three of the lesions were malignant. All three subsequently had mastectomy [Table 1]. Patients with benign lesion had no further treatment.

Bruising was the most common complication of the procedure, other complications were reactionary and secondary hemorrhage, hematoma collection, surgical site infection (SSI), breast distortion (BD) and hypertrophic scar (HS) [Table 1]. The hypertensive and diabetic patient had more complications. She was also the only one who had secondary hemorrhage. Three patients had BD; all three had their procedures extending into the areola region. One of them had easily obvious nipple asymmetry with flattening and distortion of the ipsilateral breast. The other two patients with BD had just slight flattening of the central area visible only on close observation. Only one patient, the hypertensive and diabetic patient, was readmitted for observation. There was no wire-associated injury.

Discussion

Approximately, 30–50% of breast cancers in modern surgical practices are non-palpable.^[1] Earlier detection and more effective treatment result in decline in mortality. Screening has dramatically increased the diagnosis of suspicious, non-palpable lesions, and therefore there is a need to localize them in order to plan surgical removal. In the six months following the enlightenment programs, there was a remarkable increase in the number of women who presented for screening mammogram, a similar trend has been reported in northern Nigeria;^[13] this suggests that there may be no inherent prejudice against screening for breast lesions apart from ignorance and also probably poverty as insinuated by Adeoti *et al.*^[5] To sustain the positive effect of the

Table 1: Age, site, complications and Histological features in 10 patients with nonpalpable breast lesions

Age	Site	Histological diagnosis	Complications	Management
51	R/LOQ	Intramammary lymphoid tissue	Bruises	None
47	L/CEN	Fibroadenoma	B, SSI, BD	None
38	L/UOQ	Invasive lobular carcinoma	RXH, SSI	MRM node positive
45	L/UOQ	Invasive ductal carcinoma	None	MRM node negative
57	L/CEN	Adenosis	SSI, BD	None
39	L/LOQ	Ductal carcinoma in situ	Bruises	SM
48	R/LIQ	Fibroadenoma	RXH, B, SSI, SH	None
45	R/UOQ	Intramammary lymphoid tissue	H, HS, BD	None
44	L/UOQ	Fibrocystic changes	None	None
48	L/UOQ	Fibrocystic changes	B, H	None

B= bruise, BD= breast distortion, H=hematoma, HS= hypertrophic scar, L= left, MRM= modified radical mastectomy, R= right, RXH= reactionary hemorrhage, SM=simple mastectomy, SSI= surgical site infection.

breast enlightening campaign, it will require further efforts and maintenance of available facilities. Health education has been proposed as a method to aid early clinical presentation,^[14,15] but in Africa health education is usually not backed with access to imaging facilities and the necessary medical experts to make early diagnosis and institute treatment if needed. This factor may be responsible for the failure of health education to promote early breast cancer diagnosis in Ghana.^[8]

Mammography is the gold standard for breast screening currently. However, studies have shown the importance of supplemental effect of ultrasound and its ability to detect some lesions missed at screening mammography.^[16,17] The procedure of wire localization was achieved with the aid of ultrasound, as it provides complementary roles to mammography in the detection of breast masses.^[18] The use of ultrasound for diagnosis of breast masses should be given serious attention especially in resource poor countries where mammography and stereotactic facility are very rare. At the time of this study, mammography was available in only about 10 centers in Nigerian, and the nearest functioning stereotactic facility was about 250 km away. With the aid of ultrasound, we have demonstrated that it is possible to diagnose certain breast lesion earlier to achieve better treatment for patients in terms of cure and cosmesis. The availability of breast conservative surgery as an option of treatment will help compliance with surgical treatment especially in an environment where females are happier keeping their breasts and they consider it non-feminine and unacceptable to lose one or both breasts.^[6-8] Also we did not use a dedicated wire localization or placement needle; instead we used a malleable steel wire, sterilized it, and inserted it into the mass under ultrasound guide using the commonly available 18G intravenous needle. It is not as efficient as the manufactured dedicated specialized needles, but these are not available in the country and usually very expensive.

Cancer was identified in 3 of the 10 lesions excised in this study; this constitutes 30% of non palpable lesions detected by both ultrasound and mammography.

The technique of excision improved over a course of less than 10 patients. The surgeon was able to centralize the target lesions after about 6 excisions. This is in contrast to 25 excisions suggested by another study.^[19] The complication rate in this study is rather high but this could be due to the learning curve. Cosmesis particularly BD or flattening was noticed to be a problem particularly when the surgery involves the central area of the breast. A major limitation of this study is the small sample size.

This study shows that a multidisciplinary approach is imperative in the fight against breast cancer. We have presented a method of wire localization of breast mass, that is practicable in resource poor center and we have also demonstrated that within our limited resources, detection of non-palpable lesion is possible.

This implies that breast conservative surgeries can be done under appropriate circumstances. In conclusion, intensification and sustenance of enlightenment programs and training of personnel are the starting points if we are to move into the "era of modern surgical practice in breast cancer management" which began more than three decades ago.

References

1. Mascaro A, Farina M, Gigli R, Vitelli C, Fortunato L. Recent advances in the surgical care of breast cancer patients. *World J Surg Oncol* 2010;8:23-45.
2. Pleijhuis RG, Graafland M, de Vries J, Bart J, de Jong JS, van Dam G. Obtaining adequate surgical margins in breast-conserving therapy for patients with early-stage breast cancer: Current modalities and future directions. *Ann Surg Oncol* 2009;16:2717-30.

3. Kopans DB. The 2009 U.S. Preventive services task force guidelines ignore important scientific evidence and should be revised or withdrawn. *Radiology* 2010;1:15-20.
4. Povoski SP, Jimenez RD, Wang WP, Xu RX. Standardized and reproducible methodology for the comprehensive and systematic assessment of surgical resection margins during breast-conserving surgery for invasive breast cancer. *BMC Cancer* 2009;9:254.
5. Adeoti ML, Oguntola SA, Aderounmu AO, Agodirin SO. Influence of socio-cultural, political, economic status and environment on the outcome of surgical practice in a developing tropical country-using breast cancer as case study. *Surg J* 2008;3:21-3.
6. Adesunkanmi AR, Lawal OO, Adelusola, Durosimi MA. The severity, outcome and challenges of breast cancer in Nigeria. *Breast* 2006;15:399-409.
7. Adisa OA, Lawal OO, Adesunkanmi AR. Paradox of wellness and nonadherence among Nigerian women on breast cancer chemotherapy. *J Cancer Res Ther* 2008;4:107-10.
8. Clegg-Lamprey JN, Hodasi WM. A study of breast cancer in Korle Bu Teaching Hospital: Assessing the impact of Health Education. *Ghana Med J* 2007;41:72-7.
9. Odusanya OO. Breast cancer: Knowledge, attitudes, and practices of female schoolteachers in Lagos, Nigeria. *Breast J* 2001;7:171-5.
10. Odusanya OO, Tayo OO. Breast cancer knowledge, attitudes and practice among nurses in Lagos, Nigeria. *Acta Oncol* 2001;40:844-8.
11. Okobia MN, Bunker CH, Okonofua FE, Osime U. Knowledge, attitude and practice of Nigerian women towards breast cancer: A cross-sectional study. *World J Surg Oncol* 2006;4:11-5.
12. Osime OC, Okojie O, Aigbekaen ET, Aigbekaen IJ. Knowledge attitude and practice about breast cancer among civil servants in Benin City, Nigeria. *Ann Afr Med* 2008;7:192-7.
13. Adeniji KA. Pathological appraisal of carcinoma of the female breast in Ilorin Nigeria. *Niger Postgrad Med J* 1999;6:56-9.
14. Gwarzo UN, Sabitu K, Idris SH. Knowledge and practice of breast-self examination among female undergraduate students of Ahmadu Bello University Zaria, Northwestern Nigeria. *Ann Afr Med* 2009;8:55-8.
15. Jebbin NJ, Adotey JM. Attitudes to Knowledge and practice of breast self-examination (BSE) in Port Harcourt. *Niger J Med* 2004;13:166-70.
16. Bajomo AA. Current views on breast cancer imaging. *Niger J Surg Res* 2004;6:73-5.
17. Berg WA, Blume JD, Cormack JB, Mendelson EB, Lehrer D, Böhm-Vélez M, *et al.* Combined screening with ultrasound and mammography compared to mammography alone in women at elevated risk of breast cancer. Result of the first year screen in ACRIN 6666. *JAMA* 2008;299:2151-63.
18. Nothacker M, Duda V, Hahn M, Warm M, Degenhardt F, Madjar H, *et al.* Early detection of breast cancer: Benefits and risks of supplemental breast ultrasound in asymptomatic women with mammographically dense breast tissue. A systematic review. *BMC Cancer* 2009;9:335.
19. Cleffken B, Postelmans J, Damink SO, Nap M, Schreutelkamp I, van der Bijl J. breast conserving therapy for palpable and nonpalpable breast cancer- can surgical residents do the job irrespective of experience. *World J Surg* 2007;31:1731-6.

Cite this article as: Agodirin SO, Ojemakinde OM, Bello TO, Oguntola AS, Aremu AA, Ojemakinde KO, Adeoti ML, Agbakwuru EA. Ultrasound-guided wire localization of lesions detected on screening mammography in Osogbo, Nigeria and its impact on breast conservative surgery. *Ann Afr Med* 2012;11:91-5.

Source of Support: Nil, **Conflict of Interest:** None declared.