

Access this article online	
Quick Response Code:	Website: www.annalsafmed.org
	DOI: 10.4103/1596-3519.87046

# Should non acute and recurrent headaches have neuroimaging before review by a Neurologist?- A review in a Southern Nigerian Tertiary Hospital

Frank Aiwansoba Imarhiagbe, Ehi Ogbeide<sup>1</sup>

Departments of Medicine and <sup>1</sup>Radiology, University of Benin, Benin City, Nigeria

**Correspondence to:** Dr. F. A. Imarhiagbe, Department of Medicine, University of Benin Teaching Hospital, P.O. BOX 7184, G.P.O, Benin City, Nigeria. E-mail: dnimei@yahoo.com

## Abstract

**Background:** Headache is a common complaint in general practice and it is known that most headaches are primary and that the yield of neuroimaging like cranial computed tomography (CT) in headache is generally low. In this study, we were able to demonstrate that the yield of neuroimaging in non-acute and recurrent headache could be higher if cases are reviewed first by a specialist Neurologist before cranial CT.

**Method:** Seventy-four cases that were referred to the specialist neurology clinic with complaints of chronic and recurrent headaches without focal neurological deficit that had CT scan were reviewed consecutively using the short form of the International Classification of Headache Disorders second edition (ICHD 2) criteria after their demographics of age, sex were captured, to find out the proportion and characteristics of study cases that had identifiable cranial lesions on cranial CT scan. All cases were reviewed by a specialist Neurologist before CT scan and all CT films were reviewed by a specialist Radiologist. Age, sex and the distribution of CT findings were described from a frequency table and mean age of study cases with and without identifiable lesions on CT were compared with t-test for any significant difference and the effect of gender on the presence of identifiable lesions was tested with chi square and the agreement between clinical and CT diagnoses were tested on kappa statistics.

**Results:** (1) Mean age of cases was 37.55 (22.06) years. (2) No significant effect of gender was found on intracranial lesions ( $P = 0.345$ ). (3) Intracranial lesions were found in 47.3% of cases and the mean age was higher compared to cases with normal findings on cranial CT ( $P = 0.019$ ). (4) Clinical and CT diagnoses agreed in 56.2% of the cases ( $P = 0.000$ ).

**Conclusion:** The high yield of intracranial lesions may be accounted for by the method of selection of cases for cranial CT.

**Keywords:** Headaches, neurologist, tomography

## Résumé

**Arrière-plan:** Maux de tête est une plainte courante en pratique générale et on sait que la plupart des maux de tête est primaire et que le rendement de la neuro-imagerie comme crânienne calculée tomodensitométrie (CT) en mal de tête est généralement faible. Dans cette étude, nous avons pu démontrer que le rendement de la neuro-imagerie dans les maux de tête non aiguë et récurrente puisse être plus élevé si les cas sont examinés par un spécialiste neurologue première crânienne CT avant.

**Méthode:** Soixante-quatorze des cas qui ont été renvoyés à la clinique de neurologie de spécialiste des plaintes pour des maux de tête chroniques et récurrentes sans déficit neurologique focale qui avait tomodensitométrie ont été examinées consécutivement à l'aide de la forme abrégée les critères de l'édition (CIDH 2) second International Classification des troubles de maux de tête après leur démographie de l'âge, le sexe ont été capturés, à savoir la proportion et les caractéristiques des cas d'étude qui avaient des lésions crâniennes identifiables sur tomodensitométrie crânienne. Tous les cas ont été examinés par un spécialiste neurologue avant la tomodensitométrie et tous les films de TC ont

été examinées par un spécialiste radiologue. L'âge, le sexe et la répartition des conclusions CT ont été décrits par un tableau des fréquences et l'âge moyen de l'étude de cas avec et sans lésions identifiables sur CT ont été comparées avec t-test pour toute différence significative et l'effet du sexe sur la présence de lésions identifiables a été testé avec carré de chi et l'accord entre les cliniques et les diagnostics de CT ont été testés sur les statistiques de kappa.

**Résultats:** (1) l'âge moyen des cas était 37.55 (22.06) ans. (2) Sans effet significatif du genre a été trouvé sur les lésions intracrâniennes ( $P = 0,345$ ). (3) Lésions intracrâniennes ont été trouvées dans 47,3% des cas et l'âge moyen était plus élevée comparativement à cas normal conclusions sur CT crânienne ( $P = 0,019$ ). Les diagnostics cliniques et CT (4) a accepté de 56,2% des cas ( $P = 0.000$ ).

**Conclusion:** Le rendement élevé de lésions intracrâniennes peut être expliqué par la méthode de sélection des cas pour CT crânienne.

**Mots clés:** Maux de tête, neurologue, tomographie

## Introduction

Headache is the commonest complaint in medical practice and it is known that most headaches are primary, but the fear of missing a potentially sinister secondary cause of headache among other reasons prompts the investigation of headaches with neuroimaging modalities like computerized tomography (CT) scan. The yield of neuroimaging in headaches is generally low particularly in cases of non traumatic, non focal, chronic headaches without neurological deficit. It is pertinent to note, however, that more often than not, the referrals for neuroimaging have been at the primary level of care. While it is standard practice to investigate acute and severe headaches promptly with neuroimaging to exclude potentially sinister causes, it is our opinion that less emergent, non acute, and recurrent headaches without clear cut diagnostic consideration by the International classification of Headache Disorders (ICHD) guidelines should be evaluated first by a specialist Neurologist before requests for neuroimaging. This may considerably increase the yield and also whittle down such requests with its corresponding cost implications particularly in resource-constrained settings. In this study, we were able to demonstrate that the yield for secondary causes of chronic headaches with cranial CT was considerably high after evaluation by a Neurologist.

## Materials and Methods

Seventy-four (74) cases that were referred to the specialist Neurology clinic with complaints of chronic and recurrent headaches without focal neurological deficit that had CT scan were reviewed consecutively after their demographics of age, sex, and domiciliary were captured, to find out the proportion and characteristics of study cases that had identifiable cranial lesions on cranial CT scan.

All cases were reviewed first by a specialist Neurologist using the short form of the ICHD 2 classification criteria for headaches before CT scan and CT was done with a two slice Siemens® 1994

third generation CT machine in the Radiology department of the hospital and all CT films were reviewed by a Specialist Radiologist.

**Exclusion -** Cases with manifest focal neurological signs or manifest cognitive decline and established cases of headache following traumatic head injury.

Study was approved by the Institutional Review Board (Ethics committee) of the hospital.

**Statistics -** Demographic data of age and sex and the distribution of CT findings were described from a frequency table and mean age of study cases with and without identifiable lesions on CT were compared with an independent *t*-test for any significant difference and the effect of gender on the presence of identifiable lesions was also tested with chi square, clinical, and CT diagnoses were compared with Cohen's kappa statistics for symmetric measure of agreement;  $P \leq 0.05$  was taken as significant for all tests. Analyses were done with SPSS® version 16.

## Results

The age range of study participants was 5-98 years with a mean age of 37.55(22.06) years. The female male ratio was 1:1.05 as shown in Table 1.

The effect of gender on the presence of identifiable lesions was not significant on a chi square test ( $\chi^2 = 892$ ,  $P = 0.345$ ) and identifiable intracranial lesions were found in 47.3% of cases while cases with normal CT findings accounted for 52.7%. as shown in Table 2 and Figure 1. Intracranial lesions were more frequent in study participants with higher age range as shown in Table 3. Clinical diagnoses and CT findings agreed in 56.2% of cases on kappa statistics as shown in Table 4 and Figure 2.

## Discussion

Headache is one of the commonest symptoms in general medical practice and it virtually affects all

persons at some point.<sup>[1,2]</sup> Primary headaches are by far commoner than secondary headaches.<sup>[3]</sup> The differential diagnoses of secondary headaches could be a legion and are very likely more numerous than for any other symptom.<sup>[3]</sup> The fear of missing a potentially sinister but treatable cause of headaches, coupled with patients' anxiety and medicolegal reasons are usually what prompts the investigation of headaches with neuroimaging modalities like computerized tomography scan (CT).<sup>[4]</sup> Though neuroimaging has revolutionized the investigation of headache and headache syndromes in general, the low yield in non traumatic, non focal, chronic and recurrent headaches and the cost implication particularly in resource poor settings are well known.<sup>[5-7]</sup> Similar trends of low yield have also been reported in the emergency evaluation of acute non focal headaches in the emergency department and in one large series only 1.02% had clinically significant findings requiring a change of management on neuroimaging.<sup>[8]</sup> Criteria in headaches that are associated with intracranial pathology and serve as red flags for neuroimaging include presence of focal neurological symptoms or findings, abrupt onset, alteration of headache characteristics, increasing

intensity and frequency, persistence despite analgesics and headaches that never alternates sides, among others.<sup>[9-11]</sup> The United States headache consortium- a group of acknowledged expert Neurologists and the European Federation of Neurological Societies' (EFNS) Task Force on use of instrumentation in the diagnosis of headaches recommend neuroimaging in ambulatory (non emergency) patients with migraine only in the presence of persistent focal neurological findings or a history of seizures.<sup>[12-14]</sup> While cases of severe acute headaches should expectedly have emergency CT scan to exclude sinister causes like subarachnoid hemorrhage and space occupying lesions, in chronic and recurrent headaches and where the clinical signs are not clearly defined or are difficult to elucidate, the opinion of a Neurologist should advisedly be sought.<sup>[15]</sup>

In this review, the mean age of cases was 37.55 (22.06) years, with a slight male sex preponderance and there was no significant effect of gender on the presence of identifiable cranial lesions [Table 1].

We noted the preponderance of cases with normal CT findings (52.7%), and the mean age was significantly lower compared to cases with identifiable cranial lesions, ( $P=0.019$ ) [Tables 2, 3 and Figure 1], suggesting that advancing age may be an indication for neuroimaging in chronic headaches. A related study found that identifiable lesions were commoner in those above 40 years of age.<sup>[16]</sup> Of the cases with demonstrable cranial lesions (47.3%), relatively benign conditions like mastoiditis, sinusitis, nasal polyps, and cerebral atrophy accounted for 21.7% while surgically correctable causes of headaches like space occupying lesions, subdural hematoma, and hydrocephalus accounted for 25.6% [Figure 1].

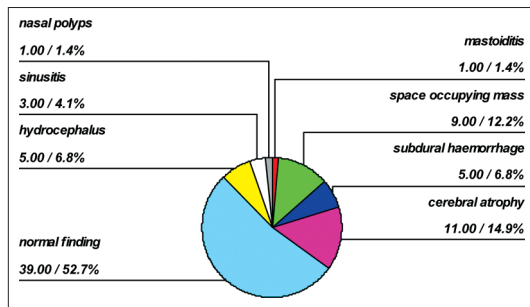


Figure 1: Intracranial lesions were found in a total of 47.3% of cases

Table 1: Demographic characteristics of the study cases

Age range	5-98 years
Sex (f/m)*	36/38
Mean age (SD) <sup>†</sup>	37.55 (22.06) years
N	74

\*f = female, m = male, female:male ratio = 1:1.05,

<sup>†</sup>SD = standard deviation

Table 2: Showing characteristics of cases with and without identifiable lesions on cranial computerised tomography

	No identifiable cranial lesions	With identifiable cranial lesions	P
Mean age (SD)*	31.92 (18.99) years	43.82 (23.76) years	0.019
Sex (f/m)	15/20	21/18	0.345
n	39	35	-

\*SD = standard deviation

Table 3: Showing the distribution of cranial C computerised tomography findings across the different age ranges of the study cases

Age range in years	CT findings n (%)								Total N (%)
	NOR	HYD	CAT	SDH	SOL	SIN	MAS	NAS	
0-30	20(64.52)	5(16.12)	-	1(3.23)	2(6.45)	2(6.45)	1(3.23)	-	31(100)
31-60	17(58.62)	-	3(10.35)	2(6.89)	6(20.69)	-	-	1(3.45)	29(100)
61-90	1(7.69)	-	8(61.54)	2(15.39)	1(7.69)	1(7.69)	-	-	13(100)
Above 90	1(100)	-	-	-	-	-	-	-	1(100)

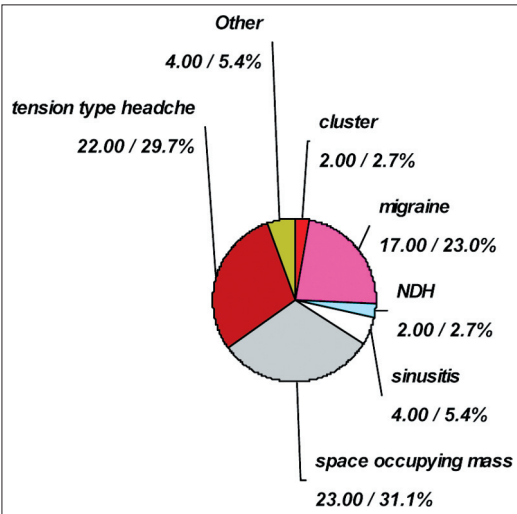
NOR = normal, HYD = hydrocephalus, CAT = cerebral atrophy, SDH = subdural haemorrhage, SOL = space occupying lesion,

SIN = sinusitis, MAS = mastoiditis, NAS = nasal polyp

**Table 4: Showing the symmetric measure of agreement between clinical diagnoses and computerised tomography (CT) diagnoses (Kappa statistics)**

	Value	P
Kappa	0.562	0.000
N	74	

Kappa statistics value shows the significant level of agreement between clinical and CT diagnoses in Table 4



**Figure 2: NDH-New daily onset persistent headache Other- orgasmic (1), trigeminal neuralgia (1), giant cell arteritis (1), mastoiditis (1) Primary headaches- tension type, migraine, cluster, NDH and orgasmic headaches together accounted for 44 (59.45%)**

We consider the proportion of cases with cerebral atrophy alone (14.9%) as the only finding on cranial CT remarkably high in a subset of cases without manifest cognitive decline. Though this has been reported previously, its clinical significance in chronic non traumatic headaches remains to be determined.<sup>[16]</sup> The relatively high yield of cases with identifiable cranial lesions (47.3%) may have been influenced by the method of selection, in which all the cases reviewed were referred for CT after assessment by a specialist Neurologist. The cases with normal CT findings were dominantly cases of primary headaches-migraine, tension type, new onset daily persistent headaches and trigeminal autonomic cephalgias like cluster headaches that either became more severe in intensity or less responsive to previous medications which prompted neuroimaging. Clinical diagnoses agreed with cranial CT findings significantly in 56.2% of cases,  $P=0.000$  [Table 4 and Figure 2], this again may largely derive from the method of selection of cases for CT.

We therefore conclude that in chronic and recurrent headaches without focal neurological deficit, normal cranial CT findings predominate and more importantly the yield for identifiable intracranial lesions may be higher if cases without clear cut diagnoses are reviewed first by a specialist Neurologist before

cranial CT scan is requested. It is our opinion that this may considerably whittle down the request for neuroimaging and the corresponding cost implication particularly in resource-constrained settings.<sup>[17]</sup>

### Acknowledgement

We appreciate the contributions of supporting staff of the department of Radiology, University of Benin Teaching Hospital, Benin City, Nigeria.

### References

1. Medina LS, D'Souza B, Vasconcellos E. Adults and children with headache. *Neuroimaging Clin N Am* 2003;13:225-35.
2. Moriarty-Sheehan M. Headache evaluation and management. *Lippincotts Prim Care Pract* 2000;4:580-94.
3. Evans RW. Diagnostic testing for the evaluation of headaches. *Neurol Clin* 1996;14:1-26.
4. Evans RW. Diagnostic testing for migraine and other primary headaches. *Neurol Clin* 2009;27:393-415.
5. Akpek S, Arac M, Ayilla S, Ohal B, Ucel C, Isik S. Cost effectiveness of computed tomography in the evaluation of patients with headache. *Headache* 1995;35:228-30.
6. Lewis DW, Dorbad D. The utility of neuroimaging in the evaluation of children with migraine or chronic daily headache who have normal neurological examination. *Headache* 2000;40:629-52.
7. Schwedt TJ, Guo Y, Rothner AD. "Benign" imaging abnormalities in children and adolescents with headache. *Headache* 2006;46:387-98.
8. Jordan YJ, Lightfoote JB, Jordan JE. Computed tomography imaging in the management of headache in the emergency department: Cost efficacy and policy implications. *J Natl Med Assoc* 2009;101:331-5.
9. Aygun D, Bildik F. Clinical warning criteria in evaluation by computed tomography of the secondary neurological headaches in adults. *Eur J Neurol* 2003;10:437-42.
10. Treatment guidelines subcommittee of the Taiwan Headache Society. Neuroimaging guidelines in non acute headaches. *Acta Neurol Taiwan* 2010;19:137-44.
11. Detsky ME, McDonald DR, Baelocher MO, Tomlinson GA, McCrory DC, Booth CM. Does this patient with headache have a migraine or need neuroimaging? *JAMA* 2006;296:1274-83.
12. Morey SS. Headache consortium releases guidelines for use of CT and MRI in migraine work up. *Am Fam Physician* 2000;62:1699-701.
13. Lewis DW. New practice parameters: What does the evidence say? *Curr pain Headache Rep* 2005;9:351-7.
14. Sandrini G, Friberg L, Jänig W, Jensen R, Russell D, Sanchez del Rio M, et al. Neurophysiological tests and neuroimaging procedures in non-acute headache: Guidelines and recommendations. *Eur J Neurol* 2004;11:217-24.
15. Clinch CR. Evaluation of acute headaches in adults. *Am Fam Physician* 2001;63:685-92.
16. Kahn CE Jr, Sanders GD, Lyons EA, Kostelic JK, McEwan DW, Gordon WL. Computed tomography for non traumatic headache: Current utilization and cost effectiveness. *Can Assoc Radiol J* 1993;44:189-93.
17. Onwuchekwa CR, Onwuchekwa AC. The role of computed tomography in the diagnostic work-up of headache patients in Nigeria. *Headache* 2010;50:1346-52.

**Cite this article as:** Imarhiagbe FA, Ogbeide E. Should non acute and recurrent headaches have neuroimaging before review by a Neurologist?- A review in a Southern Nigerian Tertiary Hospital. *Ann Afr Med* 2011;10:290-3. **Source of Support:** Nil, **Conflict of Interest:** None declared.