

## Case Report

### Access this article online

Quick Response Code:



Website:

www.annalsafmed.org

DOI:

10.4103/1596-3519.84701

# Perforated appendicitis in a septuagenarian

Robert B. Sanda, Salah I. Seliem, Elrasheed Omar, Syed Ashraf

Department of Surgery, Drumheller Hospital, Drumheller AB, ToJ oY1, Canada

Page | 249

**Correspondence to:** Dr. Robert B. Sanda, Department of Surgery, Drumheller Hospital, Drumheller AB, ToJ oY1, Canada. E-mail: robeesanda@yahoo.com

## Abstract

Appendicitis in the elderly is becoming an increasingly frequent clinical encounter due to the increased life expectancy in the human race over the last half-century. Appendicitis in this age group has, therefore, become relatively more common with an atypical presentation that incurs delay in diagnosis with attendant morbidity and mortality. We present a septuagenarian who presented atypically with a rapidly progressing feature of appendicitis that emphasizes the need for early operative intervention. In addition, the patient presented with other comorbidities that could detract from a diagnosis of appendicitis to the unwary.

**Keywords:** Appendectomy, appendicitis, elderly, peritonitis

## Résumé

Appendicite chez les personnes âgées devient une rencontre clinique de plus en plus fréquente en raison de l'espérance de vie accrue dans la race humaine au cours de la dernière moitié du siècle. Appendicite dans ce groupe d'âge est donc devenue relativement plus fréquente avec une présentation atypique qui subit un retard dans le diagnostic avec la mortalité et la morbidité qui s'y rattachent. Nous présentons une septuagénaire qui a présenté atypique avec une fonctionnalité rapidement progressif de l'appendicite qui met l'accent sur la nécessité d'une intervention précoce du dispositif. En outre, le patient a présenté avec les autres maladies concomitantes qui pourraient lui enlève un diagnostic de l'appendicite à l'imprudent.

**Mots clés:** Appendicectomie, péritonite âgées, appendicite

## Introduction

The increased life expectancy that came about during the late 20<sup>th</sup> and the first decade of the 21<sup>st</sup> centuries has compelled surgeons and physicians to undertake medical procedures in increasingly older patients. The most common emergent surgical operation, appendicitis, previously regarded as a pediatric operation, is increasingly being seen in older patients. The geriatric patient with appendicitis, however, presents remarkably differently from his pediatric counterpart, largely due to the changes in the body's physiologic reserves and disease manifestation. Thus, stereotyping of the presentations of appendicitis could put elderly patients presenting with it at risk of morbidity and

delayed implementation of treatment due to delay in making the diagnosis.

## Aim

We present a case of appendicitis in a patient in his eight decade, which illustrates the atypical presentation and the rapid evolution of the disease in this age group.

## Case Report

A 75-years-old man presented to our hospital complaining of abdominal pain and fever all of 12-hour duration. The pain began suddenly around the right iliac fossa and was nonmigratory and constant.

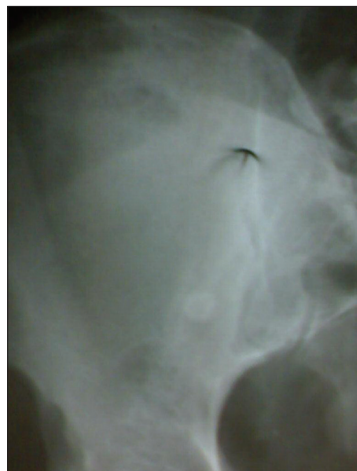Within four hours, he developed fever with chills and rigors. There was no history of nausea, vomiting, or altered bowel habits. He had Parkinson's disease for two years and was on Trihexyphenidyl (Artane®) and Propranolol (Inderal®).

On examination, the patient was lying still and was mildly febrile ( $T = 37.8^{\circ}\text{C}$ ). Other vital signs were: Pulse = 93/min; BP = 134/68 mmHg; and RR = 16/minute. There was tenderness over a wide area of the right lower abdominal quadrant with guarding, rebound tenderness and a positive Rovsing's sign. The bowel sounds were subdued. Examination of the central nervous system revealed intact sensorium and cognition. Resting tremor of the hands and cog-wheel rigidity at the wrists was noted. There were joint stiffness involving the hips, the knees, and the ankle joints.

A provisional diagnosis of localized peritonitis due to bowel perforation in the vicinity of the cecum, appendix, and terminal ileum with Parkinson's disease and multi-joint osteoarthritis was made.

Laboratory examination revealed a total leukocyte count of  $10.4 \times 10^9/\text{l}$  with elevated neutrophils (85%). X-ray of the abdomen showed a normal gas pattern, bone, and soft tissues. A rounded radio-opaque shadow was evident in the right iliac fossa that was suggestive of an appendicular fecalith [Figure 1]. There was no free air under the diaphragm. Electrocardiography showed evidence of mild left ventricular hypertrophy. Within one hour of presentation to the hospital general anaesthesia was induced to commence the operation.

At operation, the findings were a markedly inflamed appendix with involvement of the wall of the cecum. The appendix was perforated at the base with contamination of the peritoneum over a wide

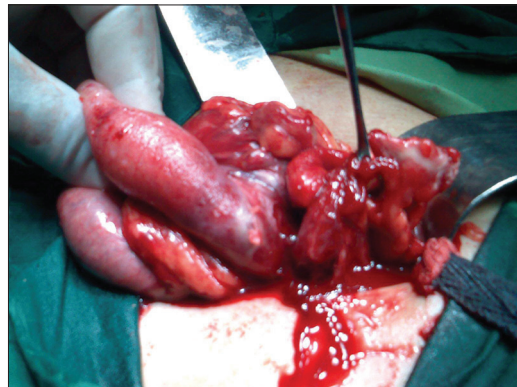


**Figure 1:** Abdominal x-ray showing a radio-opaque shadow in the right iliac fossa consistent with an appendicular fecalith

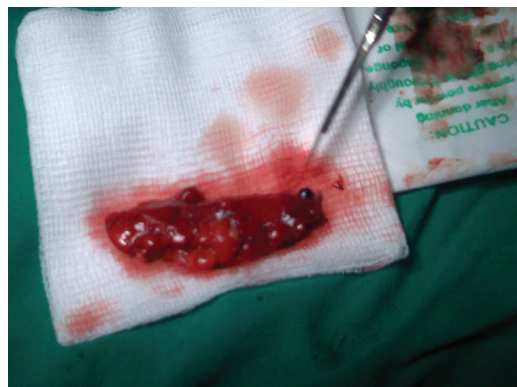area [Figure 2]. Appendectomy was done and the fecalith was identified [Figure 3]. A peritoneal swab subsequently tested positive to *Escherichia coli*, sensitive to all the 21 antibiotics against which it was tested including the three the patient was taking. Wound closure was by a delayed primary closure over a closed drainage system. Recovery was uncomplicated.

## Discussion

Increased life-expectancy in the late 20<sup>th</sup> century has brought with it an increased demand for abdominal operations among the elderly, including appendectomy.<sup>[1]</sup> Appendicitis is a difficult diagnosis to make with certainty in this age group and carries unacceptably high complication and mortality rates.<sup>[2]</sup> In an observational study from Finland of operative interventions for nonvascular acute abdomen among 201 elderly patients aged 65 years and over between 1986 and 1989, Kettunen *et al.* found appendectomy accounting for 20% of their operations.<sup>[3]</sup> These authors also observed a 44% mortality rate following appendectomy among the patients that were older than 80 years. In these patients, 64% were risk-categorized into American Society of Anaesthesiologists class IV



**Figure 2:** Intraoperative photograph showing the perforated appendix held by a pair of Babcock's forceps while the gloved hand of the surgeon held the inflamed cecum



**Figure 3:** Photograph of the operative specimen with the scalpel pointing to the fecalith protruding from the lumen of the appendix

or V at admission. The morbidity and mortality rate in another elderly population from the USA were estimated at 31% and 20%, respectively.<sup>[4]</sup>

The difficulty in establishing the diagnosis early can be attributed to several factors. Elderly patients tend to seek help relatively late from the onset of symptoms.<sup>[5,6]</sup> When they do, in a sizable proportion, the presenting features are atypical.<sup>[7-9]</sup> Clinical and laboratory features of inflammation like pain, vomiting, and leukocytosis may be greatly attenuated, presumably due to an ageing immune and neural systems. Our patient presented with nonmigratory pain without vomiting and with just borderline leukocytosis, despite having a perforated appendicitis with localized peritonitis. Even though our patient presented early (and there was no delay in carrying out the operation), the appendix was already perforated by the time of operation. It has been suggested that due to the atrophy of the wall of the appendix and due to the involution of the gut-associated lymphoid systems, the appendix tends to perforate relatively early in this age group.<sup>[10]</sup> For this reason, appendectomy should not be delayed in the elderly.<sup>[11]</sup> Comorbid conditions often vie for consideration in the differential diagnosis and may be a factor for consideration in general anesthesia.<sup>[3]</sup>

We had no doubt about the diagnosis of appendicitis in this patient when he presented because the clinical findings were strongly supported by the presence of a radio-opaque shadow in the abdominal x-ray that suggested an appendicular fecalith. When in doubt, Ultrasonography and Computerized Tomographic (CT) scans are helpful in establishing the diagnosis or in ruling it out.<sup>[12]</sup> Laparoscopic appendectomy has been found to have several advantages in a large study population in the USA.<sup>[13]</sup> In this nationwide large sample, elderly patients who underwent laparoscopic or open appendectomy between 1998 and 2000 were compared in terms of length of hospital stay, rate of routine discharge, and in-hospital morbidity and mortality rates. The results revealed a significant outcome benefit for the laparoscopic group as compared with the open appendectomy group. Similar observations were made in a prospective study from Taiwan but admittedly with a smaller patient population.<sup>[14]</sup> On the contrary, others have observed no statistically significant differences among a population of elderly patients who underwent appendectomy by laparoscopy aided by preoperative CT scan in terms of measurable outcomes like morbidity and

mortality.<sup>[15]</sup> It would be rational to recommend that although CT and laparoscopy remain useful diagnostic tools, good clinical acumen and a low threshold for operative intervention should be the goal all in elderly patients presenting with features suggestive of appendicitis.

## Acknowledgement

The authors hereby acknowledge, with gratitude, the contribution of Dr. Narcisse Ndoumbe for providing the French translation of the abstract.

## References

- Gurleyik G, Gurleyik E, Unalmiser S. Abdominal surgical emergency in the elderly. *Turk J Gastroenterol* 2002;13:47-52.
- Gurleyik G, Gurleyik E. Age-related clinical features in older patients with acute appendicitis. *Eur J Emerg Med* 2003;10:200-3.
- Kettunen J, Paaajanen H, Kostianen S. Emergency abdominal surgery in the elderly. *Hepatogastroenterology* 1995;42:106-8.
- Keller SM, Markovitz LJ, Wilder JR, Aufses AH Jr. Emergency and elective surgery in patients over age 70. *Am Surg* 1987;53:636-40.
- Sherlock DJ. Acute Appendicitis in the over-sixty age group. *Br J Surg* 1985;72:245-6.
- Styrud J, Eriksson S. Acute appendicitis in the elderly. An analysis of 47 patients over 80 years of age. *Int J Surg Investig* 1999;1:297-300.
- Lau WY, Fan ST, Yiu TF, Chu KW, Lee JM. Acute appendicitis in the elderly. *Surg Gynecol Obstet* 1985;161:157-60.
- Phillips SL, Burns GP. Acute abdominal disease in the aged. *Med Clin North Am* 1988;72:1213-24.
- Burns RP, Cochran JL, Russell WL, Bard RM. Appendicitis in mature patients. *Ann Surg* 1985;201:695-704.
- Amboldi A, Veneroni F. Acute Appendicitis in patients under 5 and over 60 years of age. *G Chir* 1990;11:481-6.
- Vermeulen MI, van Vroonhoven TJ, Lequit P. Acute Appendicitis: A serious disease in the elderly. *Ned Tijdschr Geneesk* 1995;139:1635-8.
- Sfairi A, Farah A, Patel JC. Acute appendicitis in patients over 70 years of age. *Presse Med* 1996;25:707-10.
- Guller U, Jain N, Peterson ED, Muhlbaier LH, Eubanks S, Pietrobon R. Laparoscopic appendectomy in the elderly. *Surgery* 2004;135:479-88.
- Wang YC, Yang HR, Chung PK, Jeng LB, Chen RJ. Laparoscopic appendectomy in the elderly. *Surg Endosc* 2006;20:887-9.
- Hui TT, Major KM, Avital I, Hiatt JR, Margulies DR. Outcome of elderly patients with appendicitis: Effect of computed tomography and laparoscopy. *Arch Surg* 2002;137:995-1000.

**Cite this article as:** Sanda RB, Seliem SI, Omar E, Ashraf S. Perforated appendicitis in a septuagenarian. *Ann Afr Med* 2011;10:249-51.

**Source of Support:** Nil, **Conflict of Interest:** None declared.