

## Review Article

# Oral mucosa grafts for urethral reconstruction

I. A. Mungadi, V. I. Ugboko<sup>1</sup>

Department of Surgery, Usmanu Danfodiyo University Teaching Hospital, Sokoto; <sup>1</sup>Department of Oral and Maxillofacial Surgery, Obafemi Awolowo University Teaching Hospital, Ile-Ife, Nigeria

Page | 203

**Correspondence to:** Dr. I. A. Mungadi, Department of Surgery, Usmanu Danfodiyo University Teaching Hospital, Sokoto, Nigeria. E-mail: [imungadi@yahoo.com](mailto:imungadi@yahoo.com)

### Abstract

**Background:** Urethral reconstruction has continued to present formidable and enormous challenges for urologic, paediatric and plastic surgeons as diverse opinions have been expressed on the quality and type of ideal substitution material. This literature review is aimed at drawing attention of surgeons to the versatile nature of oral mucosal grafts.

**Methods:** A review of the utilization of oral mucosa in urethral reconstruction was made. Structured Medline search was performed looking at all aspects of utilization of oral mucosa including mucosal harvest, donor site morbidity and outcome.

**Results:** The unique demands of the urethra set a high standard for autogenous graft substitutes; hence literature reports reveal that split and full thickness skin grafts from the scrotum, penis, extragenital sites (ureter, saphenous vein, appendix, colon, medial upper arm, neck, lateral chest, abdomen, bladder mucosa) and more recently oral mucosa have been used. Unlike other tissues, oral mucosa grafts are flexible, easy to harvest and trim and have an excellent microvasculature favorable for graft-taking. Furthermore, the natural moist location of the oral mucosa in the oral environment favours its easy adaptability in the urethral passage thus giving good long-term results. However, there are reports of complications at the donor site with the commonest being anaesthesia or paraesthesia of the cheek or lips. Regional variations of the oral mucosa, length of the graft required, the decision to close or leave donor site open and harvesting technique are some of the factors suggested to account for differences in donor site morbidity.

**Conclusion:** Oral mucosal graft is a versatile urethral substitute with excellent outcome. It is becoming the gold standard for urethral substitution.

**Keywords:** Oral mucosa, graft, urethroplasty

### Résumé

**Contexte:** La reconstruction urethrale representes des challenges continuelns enormes et formidables aux urologistes ainsi qu'aux chirurgien paediatre et esthetique. Çela est due aux opinions diverses qui ont été exprimées par rapport à la qualité et le type de materiel de substitution ideal. Cette revue de literature a pour but de tirer l'attention des chirurgiens versatile de la greffe de la muqueuse buccale.

**Methode:** Nous avons revu l'utilisation de la muqueuse buccale dans la reconstruction urethrale. Une recherche internet structure a été conduite en regardant sur tous les aspects sur l'application de cette muqueuse considerant le prelevement, le site de prelevement et le resultat.

**Resultats:** Les peculiarités uniques de l'urêthre exigent un standard élevé de greffe autogeneuse remplaçante. La revue de la literature a montré que les greffes epidermiques fines et epaisses du scrotum, penis, sites extra genital (uretère, veine de saphène, appendice, gros intestin, le bras, la poitrine, le cou, l'abdomen, la muqueuse de la vessie urinaire) et tout recemment la muqueuse buccale ont été utilises. Contrairement aux autre tissus les greffes de la muqueuse buccale sont flexibles, facile à prelever et confectionner, et ont une micro vasculature excellente favorable à la reussite de la greffe. Plus encore l'humidité naturelle de la bouche favorise l'adaptation de cette greffe dans l'urêtre permettant de bon resultats en long term. Neanmoins des complications surgissent au site de prelevant, les plus frequent étant l'anæsthesie ou la paræsthesie de la joue ou les lèvres. Ces dernières sont influencées par des facteurs tel que les variations regionales de la muqueuse, la longueur requise de la greffe, la decision de fermer ou lesser ouvert le site de prelevant et la technique de prelevement de la greffe.

**Conclusion:** Les greffes de la muqueuse buccale (ou lèvre) sont des remplacements de l'urètre avec des résultats excellents. Elles deviennent de plus en plus le standard de référence pour les substitutions uréthrales.

**Mots clés:** Muqueuse buccale, greffe, urethroplastie

**DOI:** 10.4103/1596-3519.59572

## Introduction

Worldwide and over the years, reconstruction of the urethra has continued to present formidable and enormous challenges for urologic, pediatric and plastic surgeons as diverse opinions have been expressed on the quality and type of ideal substitution material. The unique demands of the urethra set a high standard for autogenous graft substitutes.<sup>[1]</sup> Reports show that split and full-thickness skin grafts from the scrotum, penis and extragenital sites (ureter, saphenous vein, appendix, colonic mucosa, medial upper arm, neck, lateral chest and abdomen), bladder mucosa and, more recently, oral mucosa have been used.<sup>[2-6]</sup> Skin provides abundant material that is easy to harvest, but its keratinized epithelium and split-thickness depth increase susceptibility to postoperative contracture, stricture formation and graft thickening when tabularized.<sup>[6]</sup> The skin hair also constitutes a major problem when hairy skin is used as a graft for urethral reconstruction. Bladder mucosa is more difficult to harvest, especially in patients who have had previous bladder surgery, exstrophy, chronic cystitis or neurogenic dysfunction. Furthermore, increased morbidity, meatal prolapse, stenosis and ectropion formation have been associated with the use of bladder mucosa.<sup>[1]</sup> Unlike bladder mucosa and skin, buccal mucosa has a thick nonkeratinized epithelial layer and a well-vascularized and thin lamina propria, favoring early inosculation.<sup>[7]</sup> Buccal mucosal grafts have emerged as reliable substitutes with long-term results comparable to those of penile skin flaps.<sup>[8,9]</sup> Some authors have recommended buccal mucosa over flaps for patch urethroplasty.<sup>[10,11]</sup> Buccal mucosa takes shorter time to harvest compared with penile flaps and spares the penis from potential complications of scarring (donor site), torsion and cordee. The chances of failure and recurrence are reduced in patients with balanitis xerotica obliterans as buccal mucosa is not involved in this process.<sup>[12]</sup>

## Historical Perspective

Oral mucosa has been used as a free graft in reconstructive plastic surgery for over a hundred years, since Stellwag von Carion used the lip mucosa to repair conjunctival defects in 1873.<sup>[3]</sup> As early as 1941, Humby combined oral mucosa

with a full-thickness graft for penoscrotal fistula closure and observed success with only the buccal mucosa.<sup>[13]</sup> El-Kasaby *et al.*, have described their experience with 20 patients undergoing 1-stage correction of an anterior urethral stricture using a buccal mucosa patch graft; they obtained excellent results in 18 patients.<sup>[14]</sup> Similarly, Monfort *et al.*, managed strictures in pediatric patients and noted a comparable success rate of 90% for bladder mucosa and oral mucosa.<sup>[15]</sup> After these initial publications, 1994 onwards several clinical accounts have been published on the use of oral mucosa, especially for small populations of patients.<sup>[16,17]</sup> The first large heterogeneous patient sample ( $n = 18$ ) was presented by Duchett *et al.*, where after 27 months of follow-up, 17% of the patients required corrective surgery.<sup>[18]</sup> Their report also contained the first histological and immunohistochemical investigations of the oral mucosa compared with penile skin and bladder mucosa, and it is noteworthy that their findings explained the quick acceptance of this free graft. Dessanti *et al.*, also reported their findings from 12 cases after the first long follow-up of 3 years with encouraging results.<sup>[19]</sup> Since 1995, buccal mucosa graft (BMG) has been used more often than penile skin for urethral reconstruction.<sup>[20]</sup> Table 1 summarizes the historical perspective of oral mucosa grafts for urethroplasty.

The year 1996 saw the publication of the largest clinical series (100 cases), where after a follow-up of 23 months, only 12% had complications.<sup>[21]</sup> Subsequently, other publications focused on techniques of harvesting the graft, as well as the available sites that could avoid or minimize donor site morbidity.<sup>[1,20-27]</sup> This led Filipas *et al.*, to attest to the long-term suitability of mucosal grafts after exposure to urine.<sup>[3]</sup> The period from the late 1990s to the present times has seen more articles focusing on donor site morbidity in cases of oral mucosal grafts and its implications. The higher prevalence of donor site complications seen in recent reports<sup>[5,28-32]</sup> contrasts with the findings of earlier workers<sup>[1]</sup> probably due to greater attention on the complications following urethroplasty than on the potential complications associated with harvesting oral mucosal graft. There are also studies comparing postoperative morbidities at different intraoral sites, the latest site studied being the lateral surface of the tongue.<sup>[31-33]</sup>

**Table 1: Summary of the history of oral mucosa grafts for urethroplasty**

Year	Author/s	Focus of article
1941	Humby <sup>[13]</sup>	Perioscrotal fistula closure in animals
1992	Burger <i>et al.</i> <sup>[13]</sup>	First report in both animal and human studies on oral mucosa for urethroplasty
1992	Dessanti <i>et al.</i> <sup>[2]</sup>	Urethral replacement
1993	El Kasaby <i>et al.</i> <sup>[14]</sup>	Urethral stricture correction
1993	Monfort <i>et al.</i> <sup>[15]</sup>	Urethral stricture correction in children
1994	Gonzalvez-Pinera <i>et al.</i> <sup>[16]</sup>	Small populations of patients
1994	Brock <sup>[17]</sup>	Small populations of patients
1995	Duchett <i>et al.</i> <sup>[18]</sup>	First histological and immunohistochemical report
1995	Dessanti <i>et al.</i> <sup>[19]</sup>	First report on long follow-up
1996	Fichtner <i>et al.</i> <sup>[21]</sup>	First largest clinical series
1996	Morey and McAninch <sup>[22]</sup>	Techniques of harvesting graft, as well as available sites
1996	Tolstunov and Pogrel <sup>[23]</sup>	
1996	Wessells and McAninch <sup>[24]</sup>	
1996	Lopez <i>et al.</i> <sup>[25]</sup>	
1996	Iizuka <i>et al.</i> <sup>[26]</sup>	
1997	Eppley <i>et al.</i> <sup>[1]</sup>	
1998	Filipas <i>et al.</i> <sup>[3]</sup>	Long-term suitability after exposure to urine
2003	Dublin and Stewart <sup>[28]</sup>	Donor site morbidity and its implications
2004	Fichtner <i>et al.</i> <sup>[29]</sup>	
2004	Wood <i>et al.</i> <sup>[30]</sup>	
2005	Kamp <i>et al.</i> <sup>[31]</sup>	
2005	Jang <i>et al.</i> <sup>[32]</sup>	
2005	Fabbroni <i>et al.</i> <sup>[27]</sup>	
2006	Simonato <i>et al.</i> <sup>[33]</sup>	First report on the use of tongue mucosa

## Surgical Anatomy of Oral Mucosa

The morphology of oral mucosa varies from region to region being related to the functional demands placed upon it. These regional differences exist in the nature of the submucosa, the composition of the lamina propria, the morphology of the epithelial-connective tissue boundary, the thickness of the epithelium and type of keratinization. Three types of oral mucosae have been described, viz., masticatory, lining and specialized mucosae, and researchers have explored the use of mucosal grafts from the buccal and lower lip and from the lateral surface and undersurface of the tongue.

### Buccal and labial mucosae

These are covered by lining mucosa and have a stratified squamous nonkeratinized epithelium that lines a thin elastic lamina propria and submucosa [Figure 1]. The lamina propria consists of a rich vascular supply and dense connective tissue with short, irregular dermal papillae; while the submucosa is firmly attached to the underlying buccinator and orbicularis oris muscles and contains minor salivary glands [Figure 2]. After the removal of its subcutaneous tissue, buccal mucosa is relatively thick, mechanically stiff and elastic and so easy to handle. It is also suggested to have an infection defense layer denoted by a high concentration of IgA antibodies as a result of evolution-related qualities.<sup>[3,34]</sup> Furthermore, the natural moist location of the buccal mucosa in the oral environment favors

its easy adaptability in the urethral passage when used as a free graft.<sup>[35,36]</sup> The mucous membranes of the

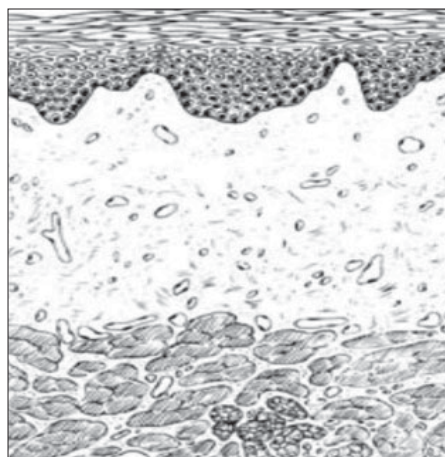


Figure 1: Histology of buccal mucosa<sup>[60]</sup>

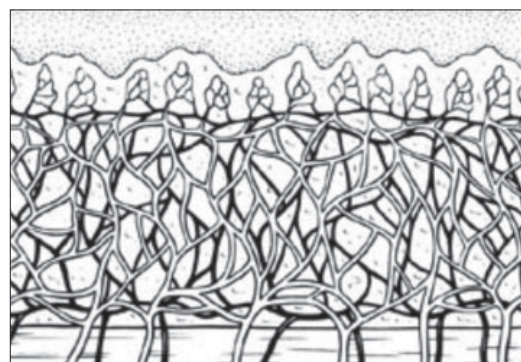


Figure 2: Microvasculature of buccal mucosa<sup>[60]</sup>

cheek and lower lip receive their nerve supply from the buccal and mental branches of the mandibular nerve, respectively.

The lip mucosa is thinner and less resistant than the buccal mucosa. In addition, the width of the lip (maximal dimension, 1 × 4 cm), unlike the buccal mucosa (maximal dimension, 3 × 5.5 cm), limits the size of the graft.<sup>[1,37,38]</sup>

### Tongue mucosa

The mucosa covering the lateral surface and undersurface of the tongue is identical in structure to that lining the rest of the oral cavity, hence it is constantly available with favorable immunological properties (resistance to infection) and tissue characteristics (thick epithelium, high content of elastic fibers, thin lamina propria and rich vascularization) and is also easy to harvest.<sup>[33]</sup> The lateral surface of the tongue offers a short mucosa, of about 7-8 cm long, and both lateral surfaces are available as donor sites if the need arises.<sup>[33]</sup>

### Indications/Uses of Oral Mucosal Free Grafts

Oral mucosal free graft is indicated where urethral substitution is required as an alternative to skin. It

may be applied for a dorsal, lateral or ventral onlay repair or for augmented anastomotic urethroplasty. Buccal mucosa has displaced genital skin flaps and grafts for onlay procedures in several centers.<sup>[20]</sup>

Barbagli *et al.*, championed dorsal placement of graft suggesting that dorsal placement gives better vascular and mechanical support, promoting take and reducing incidence of pseudo-diverticulation and enterenteneous fistula.<sup>[30]</sup> Several studies later supported this position.<sup>[20,25,39,40]</sup> Other reports have shown no differences in outcome with respect to dorsal, lateral and ventral placements of graft.<sup>[41,42]</sup> Oral mucosa may also be used in staged urethroplasty for complex urethral stricture<sup>[43,44]</sup> and in revision urethroplasty for failed hypospadias repair.<sup>[45,46]</sup> Staged buccal graft re-operation creates a well-vascularized substitute urethral plate for easy tubularization during the second stage.<sup>[47]</sup> Buccal mucosa is currently also employed in several reconstructive procedures, including glans recovering, vaginoplasty, ureteric reconstruction, metoidioplasty and repair of stenotic catheterizable continent stoma.<sup>[48,49]</sup>

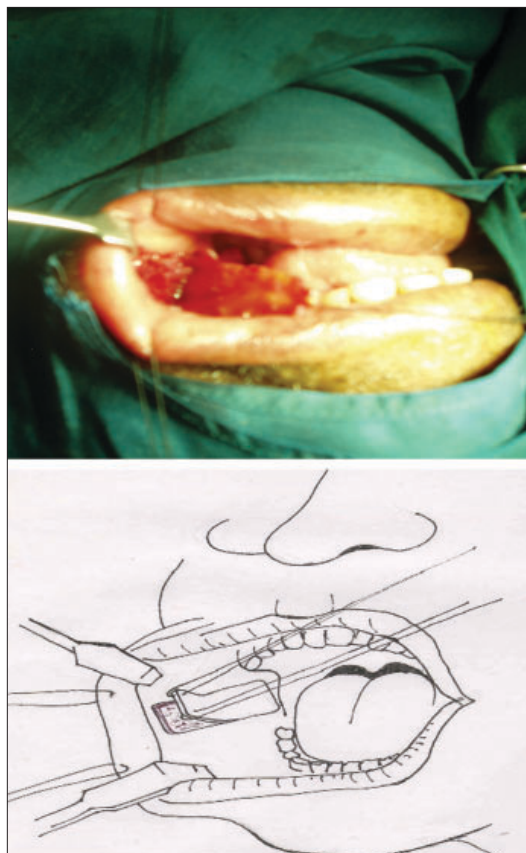


Figure 3: Buccal mucosa harvest from the right inner cheek

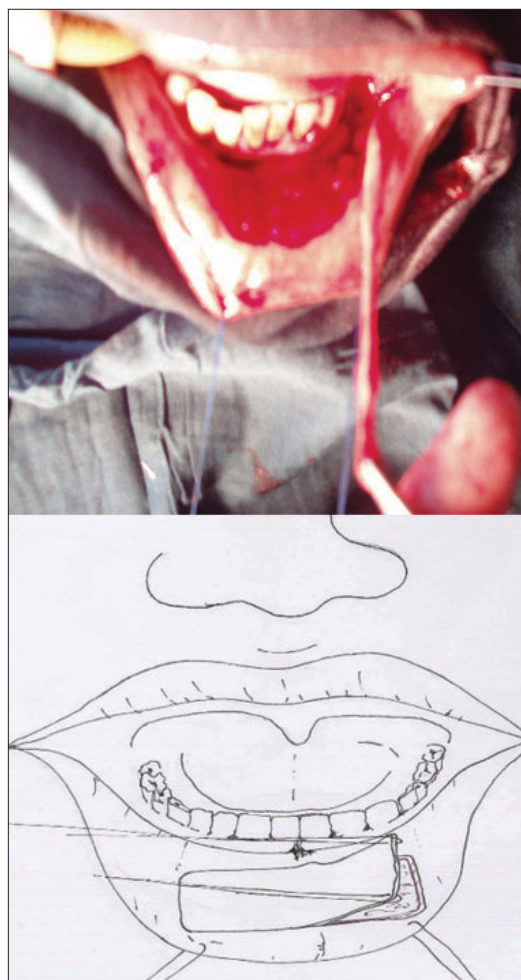

Figure 4: Oral mucosa harvest from the lower lip



## Harvesting Techniques

Oral mucosa can be harvested from the cheek or lower lip, as shown in Figures 3 and 4. Where a long length is needed, the inner cheek strip can be taken continuous with the lip. Typically the circumference of the adult urethra is between 22 and 24 mm, and a 6 cm length is often adequate for most strictures; hence some workers have described various techniques of harvesting oral mucosal graft.<sup>[1,27-51]</sup> Tolstunov and Pogrel described the free buccal mucosa graft procedure taken under general anesthesia using the Steinhäuser mucosal stretcher with retractor (Walter Lorenz Surgical, Inc., Jacksonville, Fla).<sup>[23]</sup> This instrument served as a retractor, assisted in achieving hemostasis by the spring-acting squeezing action between the plates and defined the donor site (63 × 48 mm window) inside the intraoral plate. Submucosal local anesthesia was administered to decrease bleeding and define tissue planes. The graft was thereafter taken with a scalpel, and a tenotomy scissors was used to carefully dissect to the lamina propria separating the graft from the buccopharyngeal fascia. The donor site was subsequently closed with interrupted and continuous sutures. On an average, a graft of 6 × 2.5 cm was harvested. However, Tolstunov *et al.*, have suggested outlining of the donor graft site before harvesting, making sure that at least an 8-mm distance is maintained away from the papilla of the parotid duct and 1 to 1.5 cm behind the commissure of the mouth to prevent distortion of the vermilion border during dissection.<sup>[51]</sup> They also advised that care should be taken when suturing the mucosa not to involve the duct lower lip wound is not closed to prevent inversion of the lip. Some authors have suggested that donor sites should be left open as this approach may reduce postoperative pain with no additional morbidity.<sup>[30]</sup>

Eppley *et al.*, opined that harvesting a graft from the buccal mucosa was more challenging due to limited access from the posterior location of the donor site.<sup>[1]</sup> The donor site was described as the area extending from the anterior tonsillar pillar to the vermilion-mucosal junction of the commissure, while the superior margin was a line some millimeters below the level of the parotid duct. Inferiorly it extended to the level of the mandibular vestibule, thereby providing a donor site of about 16.5 cm<sup>2</sup> (measuring 3 × 5.5 cm). They recommended nasoendotracheal intubation and improved access to the donor site by insertion of a Dingman intraoral retractor that permits maximal mouth opening, stretching and lengthening of the buccal mucosa. The procedure of graft-taking was quite similar to that described by Tolstunov and Pogrel except for separation of the mucosa using cautery and subsequent rinsing of the

graft with antibiotic solution before placement in the recipient site.<sup>[23]</sup> Eppley *et al.*, and Fabbri *et al.*, also closed the donor site partially, starting from the anterior edge, with absorbable sutures and making sure there was no bunching anteriorly.<sup>[1,27]</sup> However, Fabbri *et al.*, observed that an elliptical incision would have allowed for primary closure of the donor site but this would have been at the expense of a smaller graft. Recently, Simonato *et al.*, advocated and described a technique of harvesting mucosal graft from the lateral surface of the tongue.<sup>[33]</sup> Irrespective of the method of harvest and site, the harvested graft should be appropriately de-fattened and applied according to the indications.

## Donor Site Morbidity

Most surgeons have focused more on the complications following urethroplasty than on the potential complications associated with harvesting buccal mucosal graft. As a matter of fact, earlier reports have indicated a low prevalence of morbidity and complications at the donor site following oral mucosa grafts for urethral reconstruction; but it was not until recently that other researchers started documenting their contrasting experiences.<sup>[1,29-32]</sup> Amongst the complications highlighted in the literature are intraoperative hemorrhage, postoperative infection, pain, swelling, damage to the parotid duct, limitation of mouth opening, eversion of the vermilion, loss of sensation or altered sensation in the cheek or lower lip as a result of damage to the long buccal or mental nerves and scar contracture.<sup>[1,23,29-32]</sup> Transient paresthesia of the lower lip following neuropraxia of the mental nerve has been observed as the commonest complication.<sup>[5,31]</sup> Up to 57% of the cases seen by Dublin and Stewart developed numbness after surgery.<sup>[28]</sup> Neurosensory deficit of the long buccal and mental nerves could be explained by individual variations in the location and type of branching of these two nerves; for injury could occur to the long buccal nerve if the incision extends too far posteriorly and inferiorly. Similarly the mental nerve could be damaged if the incision is extended too far anteriorly. This is particularly pertinent in short and thin individuals who have limited amount of buccal mucosal tissue.<sup>[51]</sup>

Wood *et al.*, reported the impact of donor site closure on morbidity, while Kamp *et al.*, and Jang *et al.*, compared donor site morbidities in both the lips and inner cheek and found significantly greater long-term complications after harvesting graft from the lower lip.<sup>[30-32]</sup> In addition, Greenwell *et al.*, assessed the morbidity of buccal mucosa graft and the effect of non-suture of the graft site on postoperative pain.<sup>[52]</sup> They concluded that the

donor site can be left unsutured to lessen pain. This contrasts with the findings of Dublin and Stewart, where all the donor sites were closed and about 32% of the patients had “tightness” of the mouth.<sup>[28]</sup> They also suggested secondary healing of the donor site to prevent the complication of lip eversion. Steinhäuser had earlier observed that techniques involving full-thickness mucosal grafts leave a defect that must be closed by sutures, and this can cause scarring and contraction with decreased mouth opening.<sup>[50]</sup>

Simonato *et al.*, in a recent pilot study using mucosa of the lateral surface of the tongue reported no pain, esthetic or functional complications at the donor site, unlike the buccal mucosal graft.<sup>[33]</sup> However, the limited length of available mucosa on the lateral surface of the tongue makes it difficult to use in patients with long strictures. Regional variations of the oral mucosa, length of the graft required, the decision to close or leave donor site open and harvesting technique are some of the factors suggested to account for such differences.<sup>[31,32]</sup>

### The Role of Tissue Engineering

The main constraint of oral mucosa is the limited amount available for harvest in patients with extensive or panurethral strictures. Buccal mucosa has been successfully tissue-engineered by culturing oral keratinocytes and fibroblasts. These cells were applied to de-epidermised dermis to obtain full-thickness tissue-engineered oral mucosa for substitution urethroplasty.<sup>[53]</sup> Tissue-engineered mucosa may be utilized not only for urethral reconstruction but also for immediate reconstruction of intraoral tissue defects following oral mucosa harvest. This latter technique reduces postoperative pain, enhances intraoral soft-tissue mobility and reduces intraoral scarring.<sup>[54]</sup>

### Outcome

Most authors mentioned in this review have reported excellent short-term outcome, viz., in the range of 70% to 90%. Singh *et al.*, reported a success rate of 86.0% with dorsal onlay mucosal grafts.<sup>[55]</sup> In a comparative analysis of 63 patients and a mean follow-up at 55 months, BMG proved superior to flaps with respective success rates of up to 80% for mucosal grafts and 67% for flaps.<sup>[56]</sup> The results of BMG should ultimately be evaluated by the long-term outcomes. Lozano *et al.*, achieved a 90% success rate with bulbar strictures over a 10-year period.<sup>[57]</sup> Slovav reported a good and lasting potency of 76.9% in patients with long and complex anterior urethral strictures.<sup>[58]</sup> Several authors have also reported excellent long-term outcomes.<sup>[9-12,59]</sup>

### Conclusions

There is mounting evidence to suggest that oral mucosa is emerging as the tissue of choice for urethral substitution, and this tissue is also replacing skin graft and flaps for salvage urethroplasty in a variety of complex and recurrent strictures or failed hypospadias and epispadias repairs. Reconstructive urologists and pediatric surgeons in developing countries should therefore be familiar with this versatile technique for urethral reconstruction.

### References

1. Eppley BL, Keating M, Rink R. A buccal mucosal harvesting technique for urethral reconstruction. *J Urol* 1997;157:1268-70.
2. Dessanti A, Rigamonti W, Merulla V, Falchetti D, Caccia G. Autologous buccal mucosa graft for hypospadias repair: An initial report. *J Urol* 1992;147:1081-3.
3. Filipas D, Wahlmann U, Hohenfellner R. History of oral mucosa. *Eur Urol* 1998;34:165.
4. Xu Y, Qiao Y, Sa Y, *et al.* One stage urethral reconstruction using colonic mucosa graft: An experimental and clinical study. *World J Gastroenterol* 2003;15:381-4.
5. Bhargava S, Chapple CR. Buccal mucosal urethroplasty: Is it the new gold standard? *BJU Int* 2004;93:1191-3.
6. Webster GD, Brown MW, Koefoot RB Jr, Sihelnick S. Suboptimal results in full thickness skin graft urethroplasty using an extrapenile skin donor site. *J Urol* 1984;131:1082-3.
7. Jordan GH, Schlossberg SM. Surgery of the penis and urethra. In: Walsh PC, editor. *Campbell's urology*, 8<sup>th</sup> ed. Philadelphia: Saunders; 2002. p. 3886-954.
8. McAninch JW, Morey AF. Penile circular fasciocutaneous skin flaps in a 1-stage reconstruction of complex anterior urethral stricture. *J Urol* 1998;159:1209-13.
9. Andrich DE, Mundy AR. Substitution urethroplasty with buccal mucosal free grafts. *J Urol* 2001;165:1131-4.
10. Greenwell TJ, Venn SN, Mundy AR. Changing practice in anterior urethral strictures *BJU Int* 1999;83:631-5.
11. Kane CJ, Tarman GJ, Summerton DJ, Buchmann CE, Ward JF, O'Reilly KJ, *et al.* Multi-institutional experience with buccal mucosa only urethroplasty for bulbar urethral reconstruction. *J Urol* 2002;167:1314-7.
12. Venn SN, Mundy AR. Urethroplasty for balanitis xerotica obliterans. *Br J Urol* 1998;81:735-7.
13. Bürger RA, MŠšller C, El-Damanhoury H, *et al.* The buccal mucosal graft for urethral reconstruction: A preliminary report. *J Urol* 1992;147:662-4.
14. el-Kasaby AW, Fath-Alla M, Noweir AM, el-Halaby MR, Zakaria W, el-Beialy MH. The use of buccal mucosa patch graft in the management of anterior urethral strictures. *J Urol* 1993;149:276-8.
15. Monfort G, Di Benedetto V, Meyrat BJ. Urethral stenosis in children: Treatment using urethroplasty with a vesical or oral mucosal graft. *Ann Urol* 1993;27:237-42.
16. Gonzalez-Pinera J, Perez-Martinez A, Andujar-Cairo M, *et al.* Injerto libre de mucosa bucal para el tratamiento de hipospadias complejos. *Circ Pediatr* 1994;7:48-9.
17. Brock JW. Autologous buccal mucosal graft for urethral reconstruction. *Urology* 1994;44:753.
18. Duckett JW, Coplen D, Ewalt D, *et al.* Buccal mucosal urethral replacement. *J Urol* 1995;153:1660-3.
19. Dessanti A, Porcu A, Scanu AM, Dettori G, Caccia G. Labial mucosa and combined labial/bladder mucosa

- free graft for urethral reconstruction. *J Pediatr Surg* 1995;30:1554-6.
20. Pansadoro V, Emiliozzi P, Gaffi M, Scarpone P, DePaula F, Pizzo M. Buccal mucosa urethroplasty in the treatment of bulbar urethral strictures. *Urology* 2003;61:1008-10.
  21. Fitchman J, Fisch M, Honenfellner R. Appendiceal continence mechanisms in continent urinary diversion. *World J Urol* 1996;14:105-7.
  22. Morey AF, McAninch JW. Technique of harvesting buccal mucosa for urethral reconstruction. *J Urol* 1996;155:1696-7.
  23. Tolstunov L, Pogrel A. The free buccal mucosal graft for urethroplasty. *Oral Surg Oral Med Oral Pathol Oral Radiol Endod* 1996;82:613-5.
  24. Wessells H, McAninch JW. Current controversies in anterior urethral stricture repair: Free-graft versus pedicled skin-flap reconstruction. *World J Urol* 1998;16:175-80.
  25. Lopez JA, Valle J, Timon A, Blasco B, Ambroj C, Murillo C, *et al*. Use of autologous buccal mucosal graft for urethral surgery in males. *Eur Urol* 1996;29:227-30.
  26. Iizuka K, Muraishi O, Maijima T, Kitami Y, Xu YM, Watanabe K, *et al*. Total replacement of urethral mucosa with oral mucosa in dogs. *J Urol* 1996;156:498-501.
  27. Fabbioni G, Loukota RA, Eardley I. Buccal mucosal grafts for urethroplasty: Surgical technique and morbidity. *Br J Oral Maxillofac Surg* 2005;43:320-3.
  28. Dublin N, Stewart LH. Oral complications after buccal mucosal graft harvest for urethroplasty. *BJU Int* 2005;95:679.
  29. Fichtner J, Filipas D, Fisch M, *et al*. Long-term outcome of ventral buccal mucosa onlay graft urethroplasty for urethral stricture repair. *Urology* 2004;64:648-50.
  30. Wood DN, Allen SE, Andrich DE, Greenwell TJ, Mundy AR. The morbidity of buccal mucosal graft harvest for urethroplasty and the effect of nonclosure of the graft harvest site on postoperative pain. *J Urol* 2004;172:580-3.
  31. Kamp S, Knoll T, Osman M, Häcker A, Michel MS, Alken P. Donor-site morbidity in buccal mucosa urethroplasty lower lip or inner cheek. *BJU Int* 2005;96:619-23.
  32. Jang TL, Erickson B, Medendorp A, Gonzalez CM. Comparison of donor site intraoral morbidity after mucosal graft harvesting for urethral reconstruction. *Urology* 2005;66:716-20.
  33. Simonato A, Gregori A, Lissiani A, Galli S, Ottaviani F, Rossi R, *et al*. The tongue as an alternative donor site for graft urethroplasty a pilot study. *J Urol* 2006;175:589-92.
  34. Baskin LS, Duckett JW. The use of buccal mucosal in urethral reconstruction. *Adv Urol* 1995;8:213.
  35. Andrich, DE, Mundy AR. Substitution urethroplasty with buccal mucosal free grafts. *J Urol* 2001;165:1131-3.
  36. Kane CJ, Tarman GJ, Summerton DJ, Buchmann CE, Ward JF, O'Reilly KJ, *et al*. Multi-institutional experience with buccal mucosa onlay urethroplasty for bulbar urethral reconstruction. *J Urol* 2002;167:1314-7.
  37. Barbagli G, Palminteri E, Guazzoni G, Cavalcanti A. Bulbar urethroplasty using the dorsal approach: Current techniques. *Int Braz J Urol* 2003;29:155-61.
  38. Barbagli G, Palminteri E, Rzzo M. Dorsal onlay graft urethroplasty using penile skin or buccal mucosa in adult bulbourethral stricture. *J Urol* 1998;160:1307-9.
  39. Dubey D, Kumar A, Bansal P, Srivastava A, Kapoor R, Mandhani A, *et al*. Substitution urethroplasty for anterior urethral strictures a critical appraisal of various techniques. *BJU Int* 2003;91:215-8.
  40. Rosenstein DI, Jordan GH. Dorsal onlay graft urethroplasty using buccal mucosa in bulbous urethral reconstruction. *J Urol* 2002;167:16.
  41. Barbagli G, Palminteri E, Guazzoni G, Montorsi F, Turini D, Lazzeri M. Bulbar urethroplasty using buccal mucosa grafts places on ventral, dorsal or lateral surface of the urethra; Are results affected by the surgical technique. *J Urol* 2005;174:955-7.
  42. Elliott SP, Metro MS, McAninch JW. Long-term follow-up of ventrally placed buccal mucosa only graft in bulbar urethral reconstruction. *J Urol* 2003;169:1754-7.
  43. Palminteri E, Lazzeri M, Guazzoni G, Turini D, Barbagli G. New 2 - staged buccal mucosa urethroplasty. *J Urol* 2002;167:130-2.
  44. Joseph JV, Andrich DE, Leach CJ, *et al*. Urethroplasty for refractory anterior urethral stricture. *J Urol* 2002;167:127-9.
  45. Barbagli G, Angelis M, Palminteri E, Lazzeri M. Failed hypospadias repair presenting in adults. *Eur Urol* 2006;49:887-95.
  46. Snodgrass W, Elmore J. Initial experience with staged buccal graft (Bracka) hypospadias repair reoperations. *J Urol* 2004;172:1720-4.
  47. Snodgrass WT. Reoperative hypospadias: A spectrum of challenges. *Dial Paediatr Urol* 2002;25:1-8.
  48. Djordjevic ML, Stanojevic D, Bizic M, Kojovic V, Majstorovic M, Vujovic S, *et al*. Metoidioplasty as a single mmstage sex reassignment surgery in female transsexual: Belgrade experience. *J Sex Med* 2009;6:1306-13.
  49. Radojivici ZI, Perovic SV, Rados DP, Petar VM. Buccal Mucosa grafts for repair of stenotic catheterizable continent stoma. *J Urol* 2008;180:1767-9.
  50. Steinhauer EW. Free transplantation of oral mucosa for improvement of denture retention. *J Oral Surg* 1969;27:955-61.
  51. Tolstunov L, Pogrel MA, McAninch JW. Intraoral morbidity following free buccal mucosal graft harvesting for urethroplasty. *Oral Surg Oral Med Oral Pathol Oral Radiol Endocr* 1997;84:480-2.
  52. Greenwell TJ, Venn SN, Mundy AR. Changing practice in anterior urethroplasty. *BJU Int* 1999;83:631.
  53. Bhargava S, Chapple CR, Bullock AJ, Layton C, MacNeil S. Tissue-Engineered buccal mucosa for substitution urethroplasty. *BJU Int* 2004;93:807-11.
  54. Lauer G, Schimming R, Frankenschmidt A. Intra oral wound closure with tissue engineered mucosa: New perspectives for urethral reconstruction with buccal mucosa grafts. *Plast Reconstr Surg* 2001;107:25-33.
  55. Singh PB, Das SK, Kumar A, *et al*. Dorsal onlay lingual mucosal graft urethroplasty: Comparison of two techniques. *Int J Urol* 2008;11:1002-5.
  56. Barbagli G, Morgia G, Lazzeri M. Restrospective outcome analysis of one-stage penile urethroplasty using flap or graft in a homogenous series of patients. *BJU Int* 2008;1002:853-60.
  57. Lozano Ortega JL, Pertusa Pena C. Surgical treatment of urethral stenosis: Results of 100 urethroplasties. *Arch Esp Urol* 2009;62:109-14.
  58. Slovac C. Urethroplasties in long strictures of the anterior urethra. *Khirurgiia (Sofia)* 2006;2:19-23.
  59. Fichtner J, Filipas D, Fisch M, Hohenfellner R, Thüroff JW. Long term outcome of ventral mucosal onlay graft urethroplasty for urethral stricture. *Urology* 2004;64:648-50.
  60. Jordan GH, Schlossberg SM. Using tissue transfer for urethral construction. *Contemp Urol* 1993;13:23.