

# Traumatic Brown-Sequard syndrome– clinico-radiological correlation on MRI

S Dlangamandla, MB BCh

N Mahomed, MB BCh, FCRad(D)

Department of Radiology, University of the Witwatersrand, Johannesburg

Corresponding author: N Mahomed (nasreen.mahomed@wits.ac.za)

A 34-year-old man presented with a history of a stab wound to the left side of the neck. Physical examination revealed an ipsilateral left-sided hemiplegia and contralateral loss of sensation. A clinical diagnosis of Brown-Sequard syndrome was made. Magnetic resonance imaging (MRI) findings demonstrated hyperintensity at C4 and C5 levels on sagittal T2-weighted sequence of the cervical spine (Fig. 1) with limitation to the left hemicord demonstrated in the axial plane (Fig. 2), accounting for the Brown-Sequard syndrome. The patient was managed with supportive treatment.

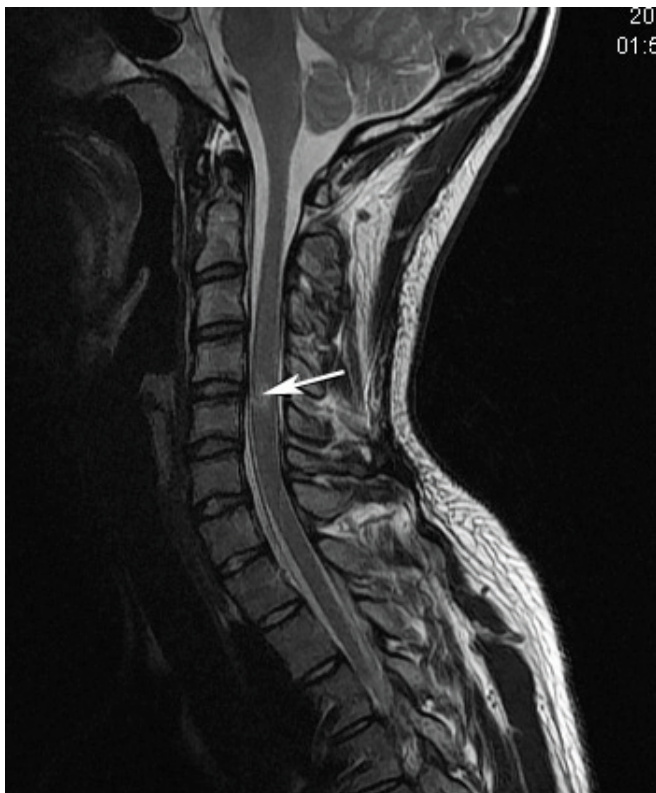

Fig. 1. Sagittal T2-weighted MRI of cervical spine demonstrates spinal cord hyperintensity at C4 and C5 levels.

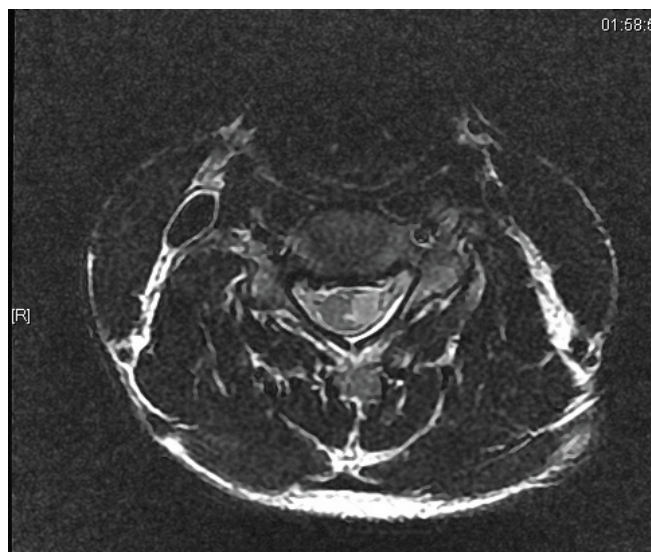


Fig. 2. Axial T2-weighted MRI at C4 and C5 levels demonstrates the extent of spinal cord hyperintensity limited to the left hemicord in keeping with the clinical features of Brown-Sequard syndrome.

## Discussion

Brown-Sequard syndrome, first reported in 1849, is characterised by hemisection of the cord with disruption of the descending lateral corticospinal tracts resulting in **ipsilateral** hemiplegia, and damage of the ascending lateral spinothalamic tracts (which cross within one or two levels of the dorsal root entrance) resulting in **contralateral** loss of pain and temperature. Damage to the dorsal columns results in ipsilateral loss of proprioception and fine touch below the level of the lesion.<sup>1,2</sup>

The most common cause of Brown-Sequard syndrome is penetrating trauma to the spinal cord, but it can also occur with blunt trauma, disc herniation, syringomyelia and spinal tumours.<sup>1,2</sup> In our patient, the high signal on MRI in the left hemicord at the level of the transection correlates well with the clinical features.

1. Sathirapanya P, Taweelarp A, Sae Heng S, Riabroi K. Brown-Sequard syndrome from cervical disc herniation, a case report and review of literature. *Neurology Asia* 2007;12:65-67.
2. Pablo M, Pedro G, Rafael A, Ariel K, Ana R. Brown-Sequard syndrome after blunt cervical spine trauma: clinical and radiological correlations. *Eur Spine J* 2007;16:1165-1170.